NTP
National Toxicology Program

# Hyaline Glomerulopathy in Pulegone-Treated Mice and Rats

Susan A. Elmore, MS, DVM, Diplomate ACVP

National Institute of Environmental Health Sciences

NTP Board of Scientific Counselors

Technical Reports Subcommittee

November 19, 2009

## Overview

- To provide information about the light and electron microscopic characteristics of hyaline glomerulopathy
  - subchronic and chronic
  - mice and rats

NTP
National Toxicology Program

# Mouse Chronic Study H&E

Control

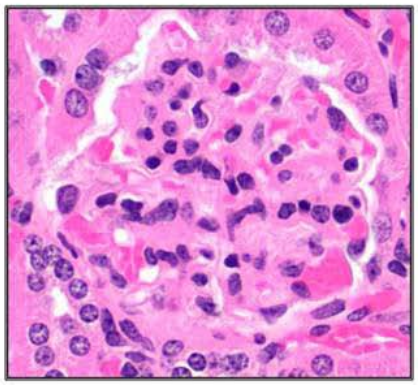

Treated

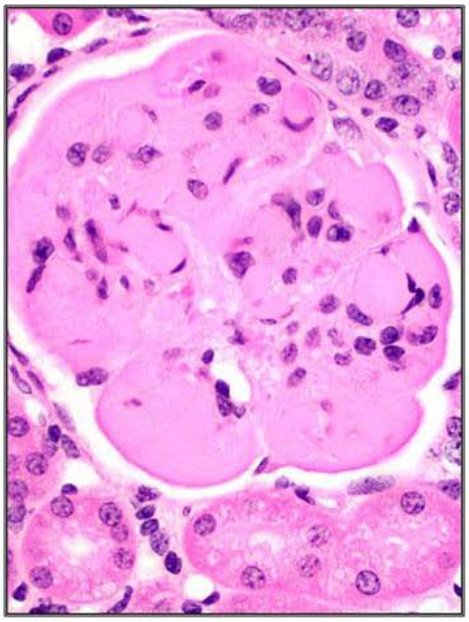

## 2-Year Mouse Study

- Males 1/50, 19/50, 30/50, 44/50
- Females 0/49, 3/50, 15/50, 41/50
- Light Microscopy, H&E stain
  - amorphous eosinophilic material expanding and effacing the mesangium and capillary loops
  - mesangiolysis
  - intraglomerular hemorrhage

NTP
National Toxicology Program

# Mouse Chronic Study H&E

## Hemorrhage

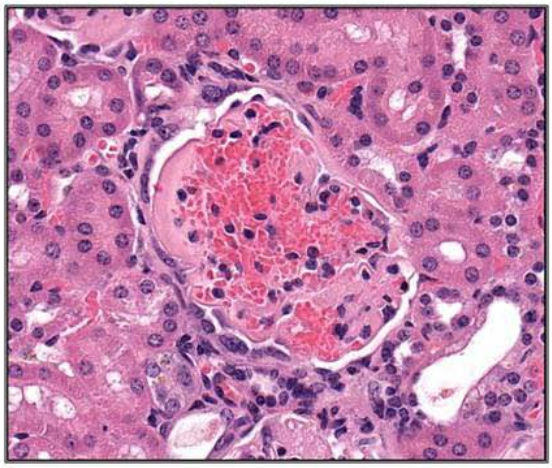

## Mesangiolysis

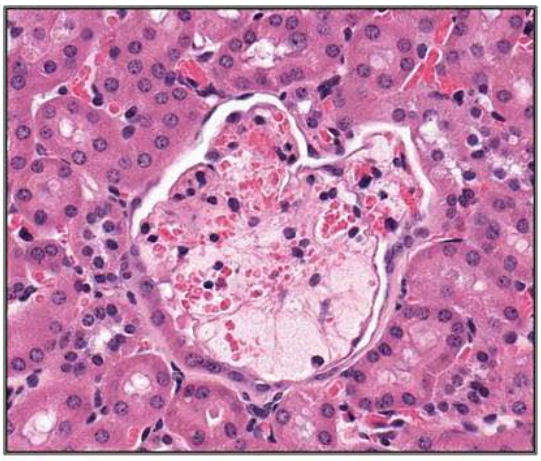

## Special Stains: 2-Year Mouse Study

- Test for amyloid: Congo Red, Leib's Cresyl Violet and Bennhold's Congo Red
  - Negative
- Evaluate basement membranes: PAS and Jones' Methenamine Silver
  - No immune complex deposition within membranes
- Test for collagen and/or mesangial matrix: Masson's Trichrome
  - Increased mesangial matrix
  - Fibrin thrombi

NTP
National Toxicology Program

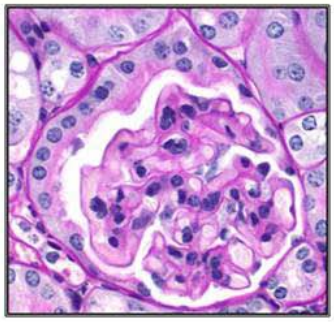

Control PAS

PAS

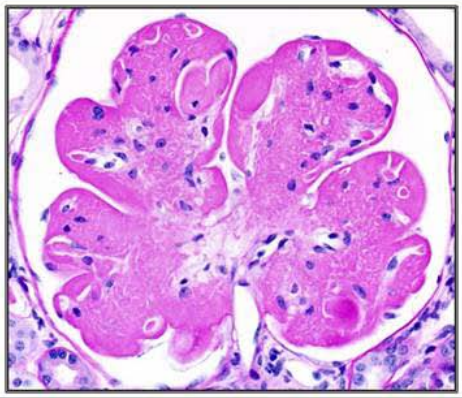

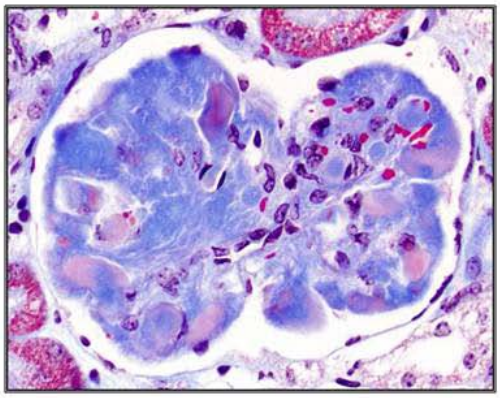

Masson's Trichrome

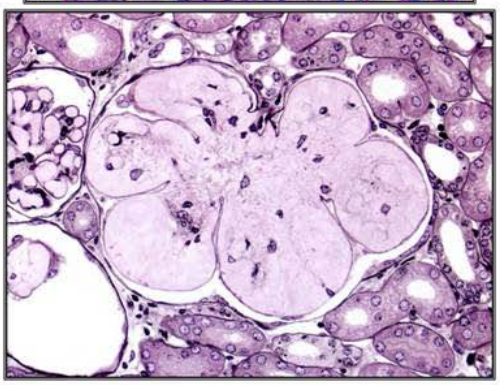

Jones' Methenamine Silver

## Immunohistochemistry: 2-Year Mouse Study

- anti-IgM positive
- anti-IgG, anti-IgA and complement protein 3 negative

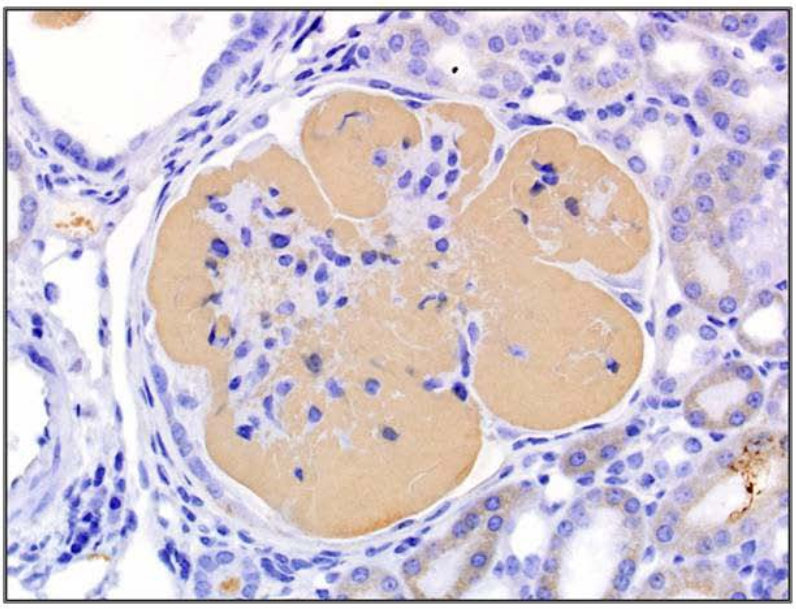

NTP
National Toxicology Program

# Electron Microscopy: 2-Year Mouse Study

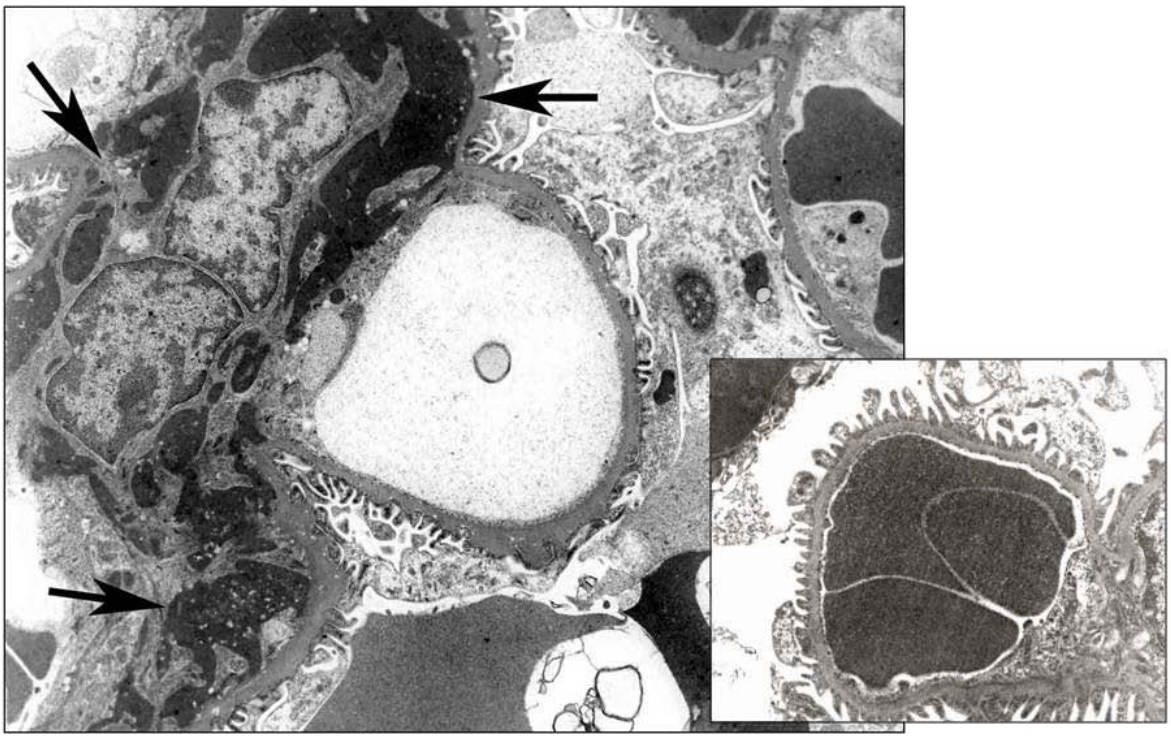

NTP
National Toxicology Program

# Electron Microscopy: 2-Year Mouse Study

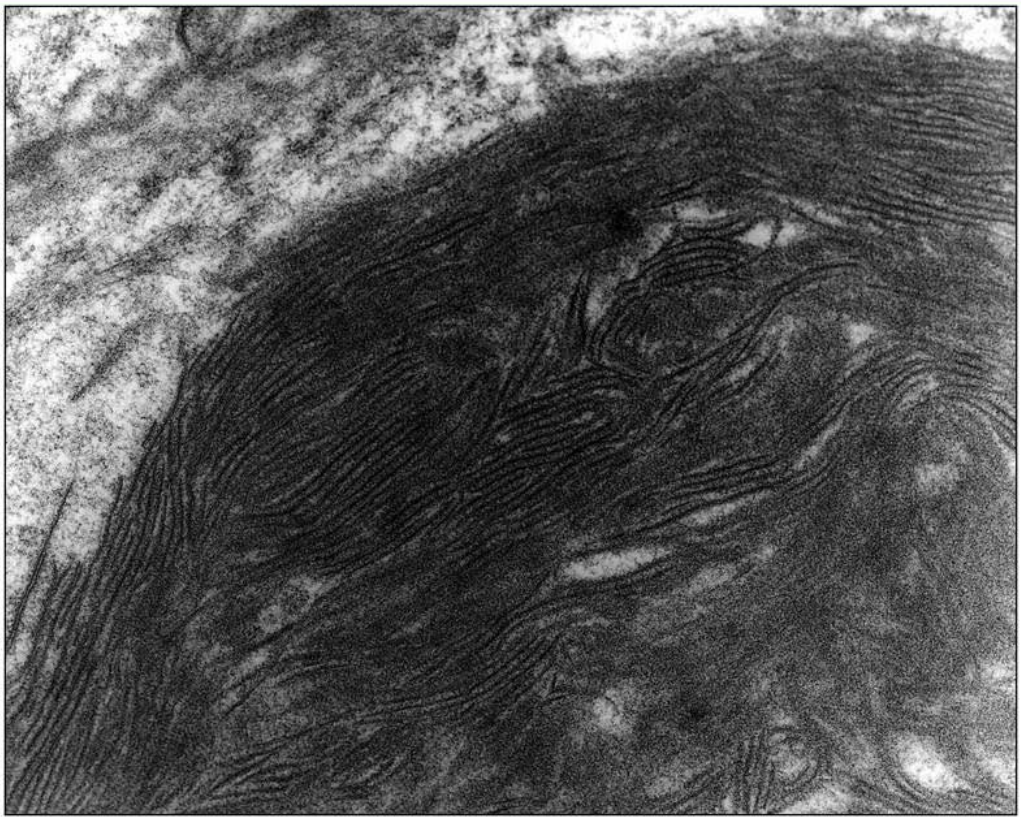

NTP
National Toxicology Program

# Hyaline Glomerulopathy in B6C3F1 Mice
## Wojcinski et al., *Pathol*, 19:224-229, 1991

**Spontaneous lesion**
**2 B6C3F1 female mice of 920 animals**
**Undetermined etiology**
**Not associated with systemic disease**
**Not reported as a treatment-related lesion**

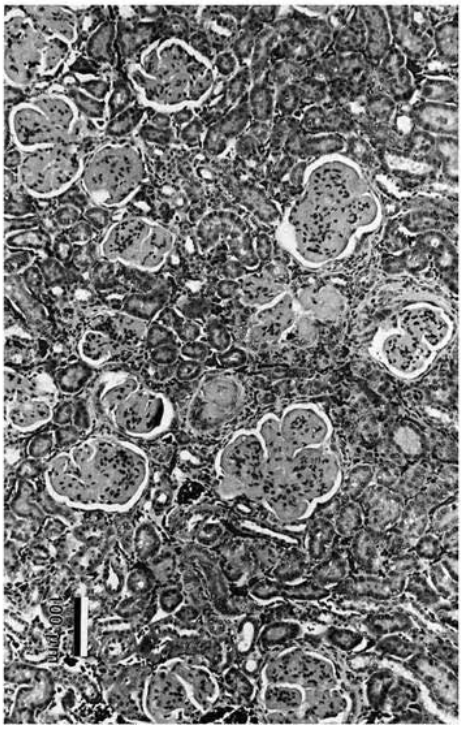

# Regulatory Effects of Novel Neurotrophin-1/B Cell-Stimulating Factor-3 (Cardiotrophin-Like Cytokine) on B Cell Function

- *Journal of Immunology*, 2002 Jun 1;168(11): 5690-8
  G. Senaldi, M. Stolina, J. Guo, R. Faggioni, S.McCabe, S.A. Kaufman, G. Van, W. Xu, F. A. Fletcher, T. Boone, M. Chang, U. Sarmiento, and R. C. Cattley

- NNT-1/BSF-3-transgenic mice, engineered to express NNT-1/BSF-3 in the liver under control of the apolipoprotein E promoter

- Non-amyloid mesangial deposits that contain IgM, IgG, and C3 and are characterized by a distinctive ultrastructure similar to that of immunotactoid glomerulopathy.

## Hyaline Glomerulopathy in Rats

- No reports in the literature of hyaline glomerulopathy in rats
- NTP Pulegone chronic rat study
  - Males 0/50, 0/50, 9/50, 24/50
  - Females 0/50, 17/50, 49/50, 48/49
  - H&E and special stain results similar to mice

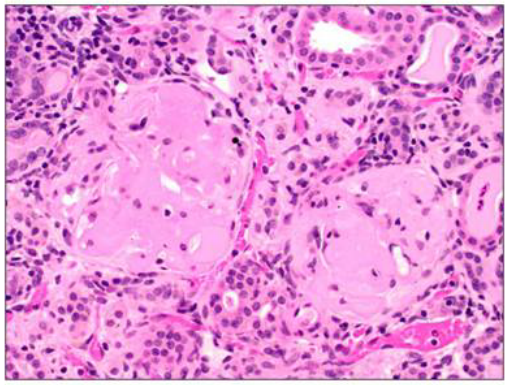

NTP
National Toxicology Program

PAS

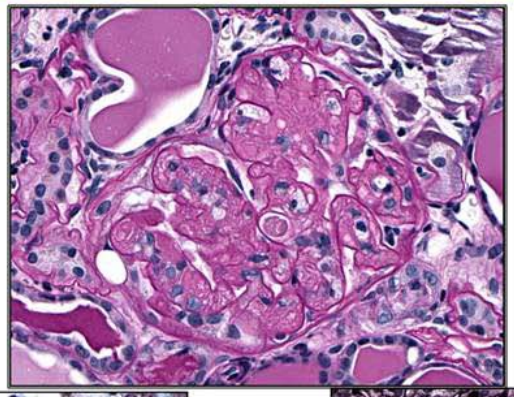

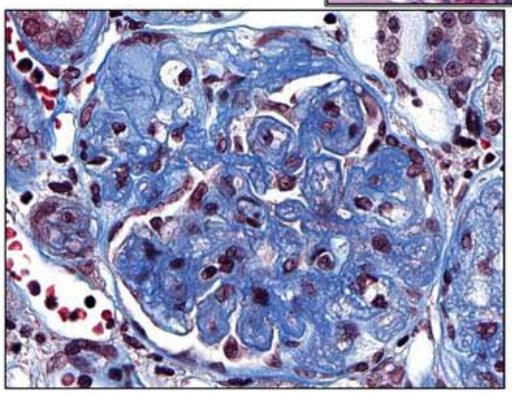

Masson's Trichrome

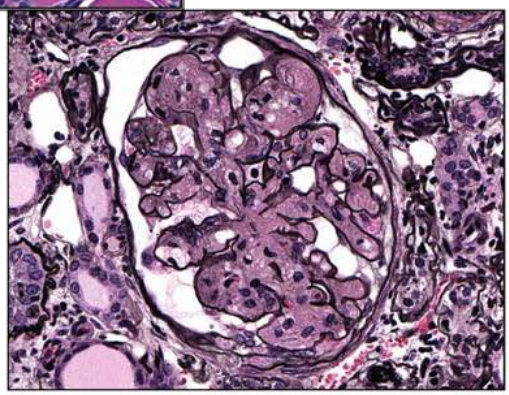

Jones' Methenamine Silver

## Immunohistochemistry: 2 Year Rat Study

- Positive for anti-IgM, anti-IgG, anti-IgA
  - multifocal within an affected glomerulus
- Negative for complement protein 3

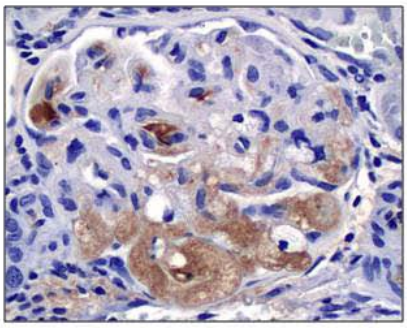

**Anti IgA**

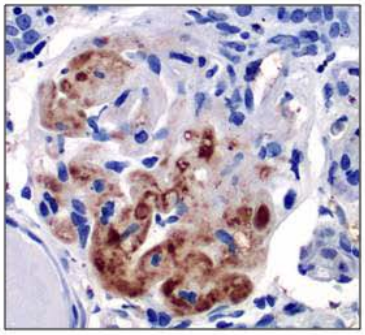

**Anti IgG**

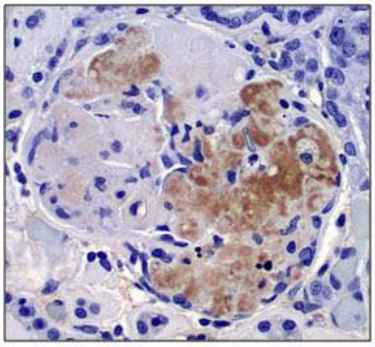

**Anti IgM**

NTP
National Toxicology Program

# Rat Chronic Study EM

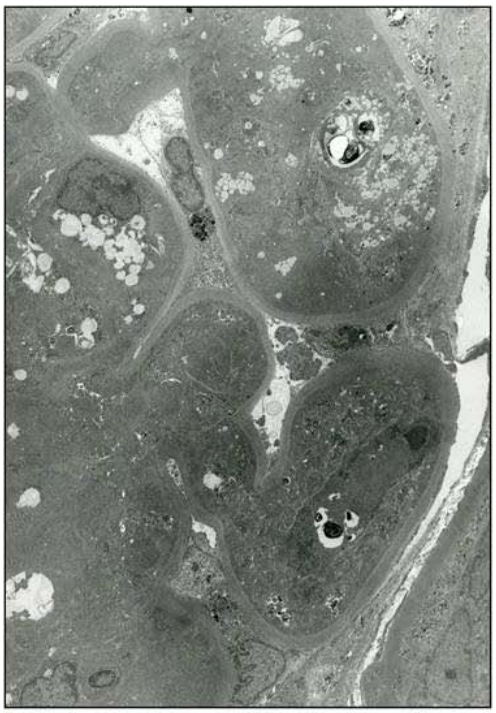

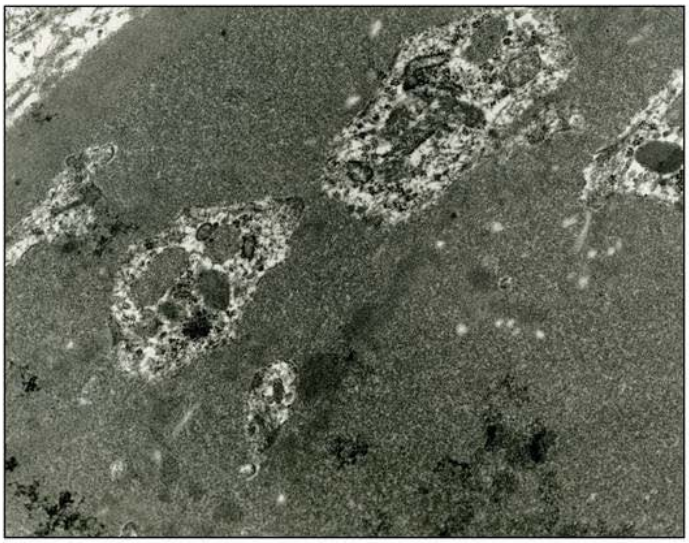

## Pulegone Subchronic Studies

- Mouse: no evidence of hyaline glomerulopathy
- Rat:
  - male rats: 0/10, 0/10, 0/10, 0/10, 2/10, 10/10 minimal severity
  - female rats: 0/10, 0/10, 0/10, 0/10, 0/10, 8/10 minimal severity

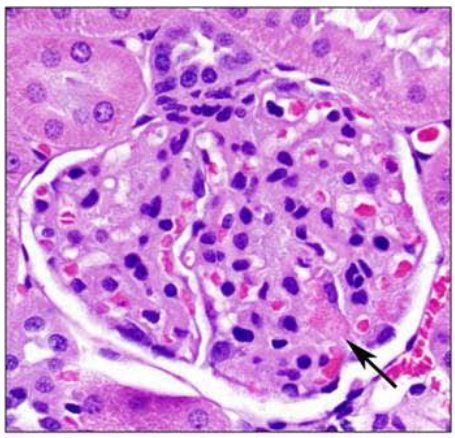

H&E

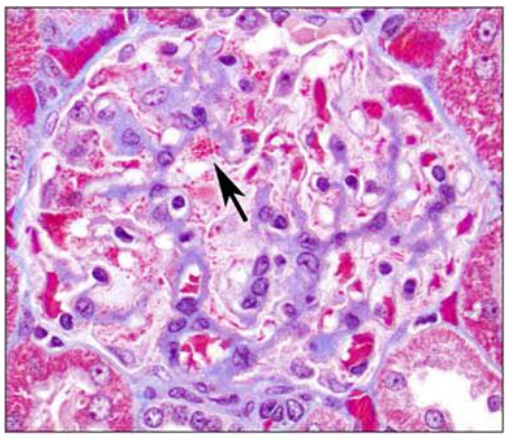

Masson's Trichrome

## Summary of Hyaline Glomerulopathy

- Reported in B6C3F1 mice as a rare spontaneous lesion not associated with systemic disease; never reported in rats
- Pulegone subchronic studies: present in rats, not in mice
- Pulegone chronic studies: present in both rats and mice
- Has features similar to amyloid with H&E stain
- Has light and EM features similar to immunotactoid glomerulopathy in humans
  - "Congo red-negative, organized glomerular Ig deposits without associated systemic disease"

## Acknowledgements

- Dr. J. Morrison, DVM, DACVP
- Dr. A.J Skowronek, DVM, PhD, DACVP
- Dr. D.M. Sells, DVM, PhD, DACVP
- Dr. A. Brix, DVM, PhD, DACVP
- Dr. H. Kolenda-Roberts, DVM, PhD, DACVP