

**NATIONAL TOXICOLOGY PROGRAM**  
Technical Report Series  
No. 249



**LIFETIME CARCINOGENESIS STUDIES**  
**OF**  
**AMOSITE ASBESTOS**  
**(CAS NO. 12172-73-5)**  
**IN SYRIAN GOLDEN HAMSTERS**  
**(FEED STUDIES)**

**U.S. DEPARTMENT OF HEALTH AND HUMAN SERVICES**  
Public Health Service  
National Institutes of Health



**NTP TECHNICAL REPORT  
ON THE**

---

**LIFETIME  
CARCINOGENESIS STUDIES  
OF  
AMOSITE ASBESTOS  
(CAS NO. 12172-73-5)  
IN SYRIAN GOLDEN HAMSTERS  
(FEED STUDIES)**

---



**NATIONAL TOXICOLOGY PROGRAM  
Box 12233  
Research Triangle Park  
North Carolina 27709**

**November 1983**

**NTP-81-58  
NIH Publication Number 84-2505  
NTP TR 249**

**U.S. DEPARTMENT OF HEALTH AND HUMAN SERVICES  
Public Health Service  
National Institutes of Health**

## NOTE TO THE READER

This is one in a series of experiments designed to determine whether selected chemicals produce cancer in animals. Chemicals selected for testing in the NTP carcinogenesis program are chosen primarily on the bases of human exposure, level of production, and chemical structure. Selection per se is not an indicator of a chemical's carcinogenic potential. Negative results, in which the test animals do not have a greater incidence of cancer than control animals, do not necessarily mean that a test chemical is not a carcinogen, inasmuch as the experiments are conducted under a limited set of conditions. Positive results demonstrate that a test chemical is carcinogenic for animals under the conditions of the test and indicate that exposure to the chemical has the potential for hazard to humans. The determination of the risk to humans from chemicals found to be carcinogenic in animals requires a wider analysis which extends beyond the purview of this study.

This study was designed and conducted at the National Institute of Environmental Health Sciences, National Toxicology Program.

Comments and questions about the National Toxicology Program Technical Reports on Carcinogenesis Studies should be directed to the National Toxicology Program, located at Research Triangle Park, North Carolina 27709 (919-541-3991) or at Room 835B, Westwood Towers, 5401 Westbard Ave., Bethesda, Maryland 20205 (301-496-1152).

Although every effort is made to prepare the Technical Reports as accurately as possible, mistakes may occur. Readers are requested to communicate any mistakes to the Deputy Director, NTP (P.O. Box 12233, Research Triangle Park, NC 27709), so that corrective action may be taken. Further, anyone who is aware of related ongoing or published studies not mentioned in this report is encouraged to make this information known to the NTP.

These NTP Technical Reports are available for sale from the National Technical Information Service, U.S. Department of Commerce, 5285 Port Royal Road, Springfield, VA 22161 (703-487-4650).

Single copies of this carcinogenesis studies technical report are available without charge (while supplies last) for the NTP Public Information Office, National Toxicity Program, P.O. Box 12233, Research Triangle Park, NC 27709.

## TABLE OF CONTENTS

	Page
Abstract .....	5
Contributors .....	6
Reviewers .....	7
Summary of Peer Review Comments .....	8
I. Introduction .....	9
II. Materials and Methods .....	13
Test Materials .....	14
Test Diets .....	15
Source and Specifications of Test Animals .....	15
Animal Maintenance .....	15
Clinical Examinations and Pathology .....	17
Data Recording and Statistical Methods .....	17
III. Results .....	19
Establishment of Test Groups .....	20
Body Weights and Clinical Signs .....	20
Survival .....	23
Pathology and Statistical Analyses of Results .....	25
IV. Summary, Comments, and Conclusion .....	33
V. References .....	35

## TABLES

Table 1	Chemical and Physical Properties of the Amosite Sample .....	14
Table 2	Materials and Methods for Animal Maintenance .....	16
Table 3	Disposition of Hamsters from the Amosite Asbestos Feeding Study .....	25
Table 4	Incidence of Primary Tumors in Male Hamster Control Groups .....	26
Table 5	Incidence of Primary Tumors in Female Hamster Control Groups .....	27
Table 6	Incidence of Primary Tumors in Male Hamsters Administered Amosite Asbestos .....	28
Table 7	Incidence of Primary Tumors in Female Hamsters Administered Amosite Asbestos .....	29
Table 8	Incidence of Gastrointestinal Tract Tumors in the Amosite Asbestos Study ....	29
Table 9	Comparison of Adrenal Tumor Incidence as Determined by Original Pathologist and NTP Pathology Working Group (PWG) .....	31

## FIGURES

Figure 1	Schedule of Major Events in the Amosite Asbestos Study .....	20
Figure 2	Growth Curves for Male Hamsters Administered Amosite Asbestos in the Diet .....	21
Figure 3	Growth Curves for Female Hamsters Administered Amosite Asbestos in the Diet .....	22
Figure 4	Survival Curves for Male Hamsters Receiving Amosite Asbestos .....	23
Figure 5	Survival Curves for Female Hamsters Receiving Amosite Asbestos .....	24

## APPENDIXES

Appendix A	Calculated Values of Amosite Asbestos in Individual Lots of Feed as Determined by Magnesium Content .....	39
Table A1	Calculated Values of Amosite Asbestos in Individual Lots of Feed as Determined by Magnesium Content .....	40
Appendix B	Disease Status of Hamsters Exposed to Amosite Asbestos.....	41
Table B1	Disease Status of Hamsters Exposed to Amosite Asbestos.....	42
Appendix C	Summary of the Incidence of Neoplasms in Hamsters Administered Amosite Asbestos in the Diet .....	43
Table C1	Summary of the Incidence of Neoplasms in Male Hamsters Administered Amosite Asbestos in the Diet .....	44
Table C2	Summary of the Incidence of Neoplasms in Female Hamsters Administered Amosite Asbestos in the Diet .....	47
Appendix D	Individual Animal Tumor Pathology of Hamsters Administered Amosite Asbestos in the Diet .....	51
Table D1	Individual Animal Tumor Pathology of Male Hamsters Administered Amosite Asbestos in the Diet .....	52
Table D2	Individual Animal Tumor Pathology of Female Hamsters Administered Amosite Asbestos in the Diet .....	67

## **CARCINOGENESIS STUDIES OF AMOSITE ASBESTOS**

### **ABSTRACT**

Carcinogenesis studies of amosite asbestos were conducted by administering diets containing 1% of the asbestos in pellets from the conception of the mothers through the lifetime of male and female Syrian golden hamsters. Control groups consisted of 127 male and 126 female hamsters and the amosite asbestos groups consisted of 252 male and 254 female hamsters.

No adverse effect on body weight gain or survival was observed from treatment with amosite asbestos. Neither of the amosite asbestos groups showed increased neoplasia in any organ or tissue compared to the control groups.

Under the conditions of these studies, the ingestion of amosite asbestos at a level of 1% in the diet for their lifetime was not toxic and did not cause a carcinogenic response in male and female Syrian golden hamsters.

## CONTRIBUTORS

National Toxicology Program  
Box 12233  
Research Triangle Park  
North Carolina 27709

- Evaluation of experiments, interpretation of results, and report of findings:
  - Dr. Ernest E. McConnell (Chemical Manager)
  - Dr. Joseph K. Haseman
  - Dr. James Huff
  - Dr. John A. Moore
  
- Conduct of Study:
  - Illinois Institute of Technology Research Institute
  - The carcinogenesis bioassay using Syrian golden hamsters was begun in 1977 and terminated in 1979.
  - Mr. Alan Shefner - Principal Investigator
  - Dr. Patricia Holmes - Toxicologist
  - Ms. Josephine Reed - Quality Assurance
  
- Pathology Evaluation:
  - Illinois Institute of Technology Research Institute
  - Dr. John Rust
  
- Pathology Quality Assurance
  - Experimental Pathology Laboratory
  - Dr. Jerry Hardisty
  - Dr. James Procter
  - NTP Pathology Working Group (3 April 1981)
  - Dr. Gary A. Boorman
  - Dr. Bholu N. Gupta
  - Dr. Larry Lomax
  - Dr. Ernest E. McConnell
  - Dr. Gerd Reznik
  - Dr. J. Stinson
  - Dr. J. Ward
  
- Format, Typing, and Collation:
  - Ms. Beth H. deBrito
  - Ms. Ethel Gilchrist
  - Ms. Sheridan Jameson
  - Ms. Geraldine Wandrisco
  
- Report Review:
  - NTP/NIH Staff Peer Review Committee
  - Dr. J. F. Douglas
  - Dr. C. K. Grieshaber
  - Dr. L. Hart
  - Dr. J. K. Haseman
  - Dr. J. E. Huff
  - Dr. E. E. McConnell
  - Dr. J. A. Moore
  - Dr. R. W. Tennant



## REVIEWERS

### National Toxicology Program Board of Scientific Counselors' Technical Reports Review Subcommittee

Margaret Hitchcock, Ph.D. (Chairperson)  
John B. Pierce Foundation Laboratory  
New Haven, Connecticut

Curtis Harper, Ph.D.  
Associate Professor of Pharmacology  
University of North Carolina  
Chapel Hill, North Carolina

Alice Whittemore, Ph.D.  
Stanford University School of Medicine  
Palo Alto, California

### Ad Hoc Subcommittee Panel of Experts

Roy Shore, Ph.D.  
New York University Medical Center  
New York, New York

Svend Nielsen, D.V.M., Ph.D.  
Professor of Pathology  
The University of Connecticut  
Storrs, Connecticut

Norman Breslow, Ph.D.  
University of Washington  
Seattle, Washington

Bernard A. Schwetz, D.V.M., Ph.D.  
Toxicology Research Laboratory  
Dow Chemical U.S.A.  
Midland, Michigan

Joseph Highland, Ph.D.  
Environmental Defense Fund  
Washington, D.C.

James Swenberg, D.V.M., Ph.D. (Principal  
Reviewer)  
Chemical Industry Institute of  
Toxicology  
Research Triangle Park, North  
Carolina

Frank Mirer, Ph.D. (Principal Reviewer)  
International Union, United Auto  
Workers  
Detroit, Michigan

Gary M. Williams, M.D.  
Chief of Experimental Pathology  
American Health Foundation  
Valhalla, New York

Sheldon D. Murphy, Ph.D.  
Professor of Toxicology  
University of Texas Medical School  
Houston, Texas

## **SUMMARY OF PEER REVIEW COMMENTS ON THE CARCINOGENESIS STUDIES OF AMOSITE ASBESTOS**

On June 23, 1981, this carcinogenesis technical report on amosite asbestos underwent peer review and was approved by the National Toxicology Program Board of Scientific Counselors' Technical Reports Review Subcommittee and associated Panel of Experts at an open meeting held in Building 101, National Toxicology Program, Research Triangle Park, North Carolina.

Dr. Swenberg, as a principal reviewer for the report on the carcinogenesis studies of amosite asbestos, agreed with the conclusion that the ingestion of amosite asbestos was not carcinogenic in male and female Syrian golden hamsters. The asbestos was administered in pelleted diet in 1% quantities for the entire lifetime of the hamsters. He said the description of animal replacement following missexing could be expanded, additional non-tumor pathology data and information on autolyzed or cannibalized animals should be added if available [see page 25], and the discussion on azoxymethane should be clarified.

As second principal reviewer, Dr. Mirer inquired as to the rationale for this being a lifetime carcinogenesis study as opposed to the usual two-year studies. Dr. E. McConnell, NTP, said this was done not only to avoid missing late appearing tumors, especially in the gastrointestinal tract, but to determine the effects in animals of exposure beginning in utero and continuing through the full life span. Another reason was to learn more about the incidence rates of neoplasms over an extended time in control hamsters. As an example, inhalation studies with asbestos in rats have shown that most mesotheliomas do not appear until after 27 months.

Dr. Moore, NTP, said that there was disagreement between the original pathologist and the Pathology Working Group for both this report and the chrysotile asbestos report. Dr. Swenberg felt that this was handled well in the reports. He said that the quality assurance review findings should also be included in the report or at least a statement to the effect that the findings are available on request.

Dr. Swenberg moved that the report on the carcinogenesis studies of amosite asbestos be approved following minor revisions. Dr. Mirer seconded the motion and the technical report was approved unanimously by the Peer Review Panel.

## **I. INTRODUCTION**

## I. INTRODUCTION

---

The term asbestos has a commercial/industrial derivation limited to naturally occurring fibrous minerals of the serpentine or amphibole series. Chrysotile is the only asbestos in the serpentine series, whereas the amphibole series is represented by actinolite, amosite, anthophyllite, crocidolite, and tremolite. The essential characteristic of asbestos materials is their fibrous nature. The gross fibers of asbestos which are visible to the naked eye are actually bundles of much finer fibrils that are submicroscopic in size.

Studies during the past 25 years have clearly established an association between occupational exposure to asbestos and increased risk of cancer. Human studies have shown that increased tumor risk is associated with chrysotile, amosite, and anthophyllite exposure; animal studies also implicate crocidolite.

Excellent reviews of the carcinogenic and public health effects associated with asbestos are those by Selikoff (1980), the Environmental Protection Agency (1980), Selikoff and Hammond (1979), and the International Agency for Research on Cancer (1977).

Lung cancer and mesothelioma are neoplasms most frequently observed in people exposed to asbestos, with the latter tumor perhaps unique in its association with these fibers. A modest increase in the incidence of gastrointestinal tumors has also been observed among asbestos insulation workers, miners, and factory workers. The increased incidence of gastrointestinal cancer and possibly peritoneal mesothelioma in occupationally exposed populations may be a consequence of direct fiber ingestion or ingestion of inhaled fibers cleared from the nasal or tracheobronchial portions of the respiratory system by mucociliary processes.

Large portions of the population ingest asbestos through consumption of food and water. Analysis of water samples from 365 cities found 45% to have detectable levels of asbestos (Millette, 1979). Forty-one cities had asbestos concentrations in water that exceeded 10 million fibers per liter. Asbestos or asbestos-like fibers may gain access to water supplies as a result of mining (Lake Superior), the presence of natural serpentine or amphibole deposits in water sheds (Seattle, Washington, and San Francisco, California), or, under certain conditions, through the use of asbestos cement pipe in municipal water supplies (EPA, 1980). In the latter instance erosion of fibers is associated with the "aggressiveness" of the

water, a term representing a mathematical expression of pH, alkalinity, and calcium content. About 69% of U.S. water systems utilize water that is potentially capable of eroding asbestos-cement pipe (EPA, 1980).

Harrington et al. (1978) failed to detect an association between the use of asbestos-cement pipe for municipal water supplies and the incidence of gastrointestinal cancer. In a study of the cancer incidence in the San Francisco Bay area, Kanarek et al. (1980) reported a statistically significant trend for the incidence of several cancer types, including stomach, gallbladder, esophageal, and peritoneal cancer, when analyzing census tracts on a gradient of low to high asbestos content in municipal water. In subsequent studies, Cooper et al. (1979) confirmed the association between asbestos levels in San Francisco Bay area drinking water and cancer of the digestive tract.

Furthermore, beers and wines could contain asbestos, possibly as a consequence of the use of asbestos filters in the preparation of these products (Cunningham and Pontefract, 1971). The ingestion of rice treated with talc that contains asbestos has been hypothesized to be associated with an increased incidence of stomach cancer (Merliss, 1971a and 1971b).

A number of studies have provided evidence that ingestion of asbestos in either food or water can result in the migration of asbestos fibers through the gastrointestinal mucosa and distant organ sites in humans (Carter and Taylor, 1980) in rats (Cunningham et al., 1977), and in baboons (Storeygard and Brown, 1977). Electron microscopic studies confirmed the presence of amphibole mineral fibers in the urine of people who ingested water containing these fibers (Cook and Olson, 1979).

Studies in animals have shown that the inhalation of asbestos can produce lung carcinoma and mesothelioma in the pleural cavity. Intrapleural, intratracheal, and intraperitoneal injection of asbestos will also produce neoplasia in several species of laboratory animals. A review of these studies is given by Levine (1978).

Asbestos (chrysotile, amosite, and crocidolite), has been shown to be cytotoxic *in vitro* to human embryonic intestine, mouse epithelial-like colon-derived cells, and rat liver epithelial cells (Reiss et al., 1979). However, chrysotile asbestos was far more cytotoxic than the amphibole fibers, and

## I. INTRODUCTION

---

effects were more pronounced in the intestine-derived cells than in those derived from the liver. Asbestos was also found to be cytotoxic to Syrian hamster peritoneal macrophages (Bey and Harrington, 1971).

Using the HGPRT locus/resistance to 6-thioguanine assay system, Reiss et al. (1979) showed that the above three forms of asbestos were not mutagenic. In addition, no mutagenic activity was demonstrated using chrysotile, amosite, or crocidolite asbestos in *Escherichia coli* or *Salmonella typhimurium* systems (Chamberlain and Tarmy, 1977). From these studies, asbestos is not likely to be genotoxic, but rather a solid-state carcinogen (Weisburger and Williams, 1979).

In 1973 the National Institute of Environmental Health Sciences and the Environmental Protection Agency cosponsored a symposium on the possible biological effects of ingested asbestos (EHP, 1974). This conference concluded that a paucity of data existed concerning the effects of ingested asbestos and that specific research was needed.

A Subcommittee of the DHEW Committee to Coordinate Toxicology and Related Programs

subsequently reviewed existing data and prepared a draft research protocol that the Committee felt was responsive to the major public health consensus. The protocol was widely distributed within and outside the government. On the basis of the comments received, a revised protocol was developed which required long-term animal toxicology and carcinogenesis studies to evaluate the ingestion of several forms of asbestos for carcinogenic effect. The forms of asbestos to be studied included chrysotile (a serpentine asbestos) (NTP TR 246), amosite (NTP TR 249 for Syrian golden hamsters and NTP TR 279 for F344/N rats) and crocidolite (representative of amphibole asbestos) (NTP TR 280), and a nonfibrous tremolite (NTP TR 267) which contained low levels of asbestiform fibers.

All materials were to be tested in the Fischer 344 strain of rat, whereas two forms of asbestos were to be tested in hamsters. All studies were to encompass the lifetime of the animal, defined as the period from which the animal commences eating solid food until death.

This technical report presents the results of those studies undertaken to determine the effects of amosite asbestos in the diet fed to male and female golden hamsters.



## **II. MATERIALS AND METHODS**

**TEST MATERIALS**

**TEST DIETS**

**SOURCE AND SPECIFICATIONS  
OF TEST ANIMALS**

**ANIMAL MAINTENANCE**

**CLINICAL EXAMINATIONS AND  
PATHOLOGY**

**DATA RECORDING AND  
STATISTICAL METHODS**

## II. MATERIALS AND METHODS: TEST MATERIALS

### TEST MATERIALS

An amosite sample (S-33) from a mine in Penge, Transvaal, Republic of South Africa was purchased by the Bureau of Mines from the Atlas Asbestos Company, Montreal, Quebec, Canada. The Bureau obtained 4,000 pounds and provided to The National Institute of Environmental Health Sciences about 1,200 pounds for these studies.

Composed primarily of grunerite asbestos (~94%), with a minor amount of actinolite asbestos (<5%), the sample was processed by a single pass through an air jet mill to improve the homogeneity of the amosite. The high abrasive action of amosite caused erosion of the steel surfaces of the mill which increased the chromium content of the milled product from 90 to 170 ppm.

Sixty lots of milled amosite were packaged in 20 pound lots in virgin fiberboard drums, which

were color coded by type of asbestos and stored with other types of asbestos in a special warehouse at Research Triangle Park, North Carolina. Random sampling of the drums determined that the amosite was of uniform homogeneity.

The homogeneity of the samples and the physical and chemical properties of the materials were characterized by the Bureau of Mines (Supt. of Documents No. 1 28.23:8452) and the Fine Particle Laboratories, Illinois Institute of Technology Research Institute, Chicago, Illinois (Special Report and Addendum on Project L6085, contract No 1-ES-5-3157). Copies of these reports are available upon request from the National Toxicology Program.

Selected chemical and physical properties of the amosite asbestos are given in Table 1. The results of analyses of each lot of blended feed are given in Appendix A.

TABLE 1. CHEMICAL AND PHYSICAL PROPERTIES OF THE AMOSITE SAMPLE

#### Mineralogical Composition

Grunerite asbestos and actinolite asbestos were detected at a volume percent abundance of about 94 and 5, respectively; minor amounts of biotite, siderite, plagioclase, ziosite, glass, opaques, and quartz were detected.

#### Fiber Characteristics

Surface area (m <sup>2</sup> /g)	3.6 ± 0.3 to 4.0 ± 0.1 (a)
Density (g/cm)	3.35 + 0.026 SD
Transmission Electron Microscopy Data	
fiber count/gm	3466 x 10 <sup>6</sup>
length (μm)	median 4.37, range 0.85 - 995 (b)
diameter (μm)	median 0.72, range 0.064 - 12.4
median fiber aspect ratio (l/d)	6.4248

#### Chemical - Instrumental Analysis

	(Wt. %)		(Wt. %)
Al <sub>2</sub> O <sub>3</sub>	0.42	Na <sub>2</sub> O	0.03
CaO	0.48	MnO	2.66
FeO	34.61	Cr <sub>2</sub> O <sub>3</sub>	0.03
Fe <sub>2</sub> O <sub>3</sub>	2.24	NiO	0.01
MgO	6.22	CO <sub>2</sub>	0.88
K <sub>2</sub> O	0.30	H <sub>2</sub> O <sup>-</sup>	0.15
SiO <sub>2</sub>	50.36	H <sub>2</sub> O <sup>+</sup>	2.30
benzene extracted organics	0.021		

(a) As measured using Quantrachrome or Perkin-Elmer surface area instruments on 15-30 independent samples.

(b) Amosite had a high percentage (24.6%) of fibers in the length class >100 μm and had several fibers over 1000 μm.



## II. MATERIALS AND METHODS: TEST DIETS

---

### TEST DIETS

An NIH 31 open formula rodent diet prepared by Zeigler Brothers Inc., Gardners, PA was used. The test diet contained 1% by weight of amosite asbestos. Pilot studies determined that homogeneous mixing of asbestos in the diet occurred when a 55 cu. ft. Patterson Kelly "V" blender was loaded by alternate layering of feed and asbestos.

Feed was pelleted into oval  $\frac{3}{8}$ " x  $\frac{3}{4}$ " pellets using a SproutWaldron pelleter. Pelleted feed was packaged in 25 pound aliquots in standard paper feed bags that were color coded to minimize feeding errors at the test laboratory. Each lot of blended feed was analyzed for asbestos concentration (Appendix A).

### SOURCE AND SPECIFICATIONS OF TEST ANIMALS

Disease free, mated female outbred Syrian golden hamsters were obtained over a period of 20 weeks in 1977 from Charles River Lakeview

Laboratories, New Field, NJ. The hamsters had been mated 6 days prior to shipping.

### ANIMAL MAINTENANCE

Upon arrival the mated female hamsters were weighed and sorted into weight ranges. They were then distributed randomly between control and treatment groups which were housed in separate rooms. Each dam was placed in its respective room in an individual cage with filter top. Treated or control food was placed in feed jars on the floor of each cage *ad libitum*. Water was provided *ad libitum* in water bottles. The hamsters were not handled except to change the cages just before the litters were due to be born. New litters were left undisturbed until approximately 10 days of age. The cages were then changed weekly (Table 2) until the offspring were weaned at 4 weeks of age.

At weaning, the offspring were weighed individually and separated by sex, at which time the dams were killed. Twenty male and 20 female offspring were removed from the study for endo- and ectoparasite examination (Appendix B) to confirm that the test groups were of a desired health status. Hamsters for the lifetime study were divided into four groups composed of 127 male and 126 female controls, and 252 male and 254 female treated animals. The test animals were randomly placed into groups of 3 males or 3 females and housed in polycarbonate cages for the remainder of the lifetime study. Extra off-

spring were retained as alternates in case of sexing errors. At about 6 weeks after weaning (10 weeks of age), all missexed hamsters were killed, along with their cage mates, and replaced with the alternates which had been maintained and treated in an identical manner. The remaining extra hamsters were killed. The experimental design insured that ingestion of asbestos spanned the entire period of solid food consumption during the lifetime of the animal. Food consumption was not determined because of the hamsters' habit of sequestering feed in their bedding. Control hamsters were housed in separate rooms.

During the test period, the temperature was maintained at  $22^{\circ}\text{C} \pm 2^{\circ}$  and the relative humidity ranged from 40% to 80%. To minimize asbestos contamination of room air, each cage was totally enclosed. Incoming air to the cages was filtered through fiberglass filters and exiting air was filtered through fiberglass roughing filters and bag housing filters. The cage air pressure was negative in relation to the room and the room pressure was slightly negative in relation to corridor air. Air flow within the animal rooms was changed at least 20 times per hour. Fluorescent lighting was provided on a 12 hours per day cycle.

**TABLE 2. MATERIALS AND METHODS FOR ANIMAL MAINTENANCE**

<b>Item</b>	<b>Manufacturer</b>	<b>Specifications</b>	<b>Frequency of Change or Cleaning</b>
Cages	Maryland Plastics New York, NY	Econo-Cage polycarbonate 19" x 10½" x 8"	Weekly
Racks	Bussy Products	Stainless steel 20 cages/rack	Monthly
Bedding	Ab-sorb-Dri, Inc. Rochelle Park, NJ	Hardwood 50 lb/bag	Weekly
Cage tops	Able Molded Plastics, Inc. Chicago, IL	GE Lexan polycarbonate	Monthly
Cage Filter	Associated Air Filter Co. Rosemont, IL	3" Diameter cut from FG50 filter mats	Monthly
Metal Holder for Cage Filter	C.D. Cash Manufacturing Chicago, IL	Outer shell with screen and baffle; inner shell with screen	Monthly
Snap Ring for Holder	Keats-Lorenz Spring Co. Chicago, IL	Phosphor bronze Spring tempered	Monthly
Feed Dish with Metal Lips	W. Braun Company Chicago, IL	16 oz. Opal or clear glass jars	Weekly
Feed Follower	Unifab Corp. Kalamazoo, MI	Stainless steel with 7 holes	Weekly
Water Bottles	Continental Glass Co. Chicago, IL	Pint flint glass	Weekly
Watering Tube	Wahmann Mfg. Co. Timonium, MD	Stainless steel 5/16" OD 7½" length with 120° bend 1½" from bottle	Weekly
Feed	Zeigler Brothers Gardners, PA	NIH 31 diet 25 or 50 lb bags	Weekly
Cage & Bottle Washer	Blakeslee Cicero, IL	Tunnel wash	Daily check Monthly maintenance
Autoclaves	American Sterilizer	Models 1) Medallion 2) RSP (Vacumatic S)	Bimonthly maintenance
Washing Compounds	Economics Labs, Inc. St. Paul, MN	Spearhead Lime away	
Room Air Filters (Exhaust)	(Roughing Filters) Air Filter Equip. Corp. Chicago, IL  (Bag Housing) Pure Air Filter Chicago, IL	Amer-Glass filters Type G filters  Dri Pak 2100 H Class II  Absolute filters Am. Air Filter Astrocel	
Rack Washer	Metal Wash Machinery Elizabeth, NJ	Mark V	Daily check Monthly maintenance

## II. MATERIALS AND METHODS: CLINICAL EXAMINATIONS AND PATHOLOGY

---

### CLINICAL EXAMINATIONS AND PATHOLOGY

All hamsters were observed daily for signs of toxicity and individual body weights were recorded weekly throughout the study. All animals were allowed to die or were killed with pentobarbital sodium when moribund. A complete post-mortem examination was performed on all animals unless they were severely cannibalized or autolyzed. Thus, the number of animals from which particular organs or tissues were examined microscopically does not necessarily represent the number of animals that were placed on study in each group.

The gastrointestinal tract, chosen as one of the target organs, was handled in a manner slightly different than is normally followed in rodent lifetime studies. The entire esophagus was opened and pinned so that the exterior surface was adjacent to cardboard prior to placement in fixative. The stomach and cecum were prepared in a similar manner. Two-centimeter lengths of duodenum and ileum and 2 portions of jejunum were placed unopened in fixative so that cross sections of these tissues were available for histopathological examination. The remaining small intestine was opened, washed gently with saline, and examined. Suspected lesions were processed separately and identified as to location. The entire colon with anus was opened, examined, and pinned similarly to cardboard prior to fixation. The size and location of masses were recorded. Masses greater than 1 mm diameter were removed for processing as separate specimens. After fixation the colon was "carpet-rolled"

starting at the posterior end and the mucosal surface was faced inward prior to embedding.

All tissues were fixed in 10% neutral buffered formalin, sectioned, and stained with hematoxylin and eosin. Tissues/organs examined microscopically were: tissue masses, the above-mentioned portions of gastrointestinal tract, mesenteric and bronchial lymph nodes, mammary gland, salivary gland, thigh muscle, bone marrow (sternum), nasal cavity with turbinates, larynx, trachea, lungs and bronchi, heart, thyroid, liver, parathyroid, gallbladder, pancreas, spleen, kidneys, adrenal glands, urinary bladder, seminal vesicles/prostate/testes, ovaries/uterus, brain, pituitary gland, eyes, and spinal cord.

The findings of the contractor pathologist were reviewed by an independent pathology contractor. All tumors diagnosed by the original pathologist, target organs (gastrointestinal tract) from all animals, and all organs from randomly selected hamsters were examined and a tissue count on all animals was taken. Sections from all tumors and any other organ where a discrepancy existed between the original and reviewing pathologists were submitted to the NTP Pathology Working Group (NTP/PWG) for review. When a discrepancy in tumor diagnosis between the original pathologist and the NTP/PWG reviewers occurred, slides were returned to the original pathologist for reevaluation. The tables shown in this report represent the original pathologist's final diagnosis. Cases in which the original pathologist did not agree with the NTP/PWG are reported separately.

### DATA RECORDING AND STATISTICAL METHODS

Individual animal pathology data from this experiment were recorded in the Carcinogenesis Bioassay Data System. The data elements include descriptive information on the chemicals, animals, experimental design, clinical observations, survival, and pathologic results.

Probabilities of survival estimated by the product-limit procedure of Kaplan and Meier (1958) are presented in this report graphically. Animals

were statistically censored as of the time that they died of other than natural causes or were found to be missing; animals dying from natural causes were not statistically censored. Differences in survival were evaluated by Cox's (1972) life table method.

As noted earlier, concurrent studies were conducted in this laboratory with another form of asbestos (short and intermediate range chryso-

## II. MATERIALS AND METHODS: DATA RECORDING AND STATISTICAL METHODS

---

tile) using the same protocol (NTP, 1983). Although the results of these studies for treated animals are not given in this report, the chrysotile controls were included with the amosite control groups as part of the pooled controls for statistical analyses.

The incidence of lesions is given as the ratio of the number of animals bearing such lesions at a specific anatomic site (numerator) to the total number of animals in which that site is examined (denominator). In most instances, the denominators represent only those animals for which that site was examined histologically. However, when a macroscopic examination was required to detect lesions (e.g., skin or mammary tumors) prior to histologic sampling, or when lesions could have appeared at multiple sites (e.g., lymphomas), the denominators consist of the numbers of animals necropsied.

For the statistical analysis of tumor incidence data, two methods of adjusting for intercurrent mortality were employed. Each used the classical methods for combining contingency tables developed by Mantel and Haenszel (1959).

For the first method of analysis it was assumed that all tumors of a given type either directly or indirectly caused the death of the animal. The proportions of tumor-bearing animals in the treated and control groups were compared at each point in time at which an animal died with a

tumor of interest. The denominators of these proportions denoted the total number of animals at risk in each group. These results were then combined by Mantel-Haenszel methods to obtain an overall probability (P) value. This method of adjusting for intercurrent mortality is Cox's (1972) life table method.

The second method of analysis assumed that all tumors of a given type were "incidental," i.e., they were merely observed at autopsy in animals dying of an unrelated cause. The proportions of animals found to have tumors in treated and control groups were compared within five time intervals. For male hamsters, the intervals were 0-52, 53-78, 79-92, 93-103, and greater than 103 weeks. For female hamsters, whose median survival was considerably less than the males, the time intervals were 0-44, 45-52, 53-60, 61-68, and greater than 68 weeks. The denominators of these proportions were the number of animals actually autopsied during the time interval. The individual time interval comparisons were then combined by the previously described methods to obtain a single overall result. (See Peto et al., 1980).

In addition to these tests, one other statistical analysis, the Fisher exact test based on the overall proportion of tumor-bearing animals (Gart et al., 1979), was carried out for each primary tumor. All reported P values are one sided. Except where noted, the three alternative analyses gave similar results.

### **III. RESULTS**

**ESTABLISHMENT OF TEST GROUPS**

**BODY WEIGHTS AND CLINICAL SIGNS**

**SURVIVAL**

**PATHOLOGY AND STATISTICAL ANALYSIS OF RESULTS**

### III. RESULTS: ESTABLISHMENT OF TEST GROUPS

#### ESTABLISHMENT OF TEST GROUPS

Because the experiment was designed to evaluate the effects of orally ingested amosite asbestos during the entire life of the animal from the time it was able to eat, mated female hamsters were placed on the test diets for approximately 2 weeks before the first litters were born. Between 10% and 15% of the females were either not pregnant, aborted, or produced litters which died immediately after birth. Several other dams died during the week following birth; these animals had prolapsed rectums. The incidences of infertility and neonatal deaths were unrelated to the test diet. The litters were not manipulated or handled during lactation to minimize the chance that the mothers would reject or cannibalize them. However, many of the pups that died during the nursing period were cannibalized by their mothers. In those pups in which a postmortem examination was possible, the stomachs typically

contained no milk, suggesting maternal rejection or the inability to compete with litter mates. None of these effects were related to the ingestion of the asbestos.

Between weaning and 14 weeks of age, approximately 2% of the offspring in all groups died from cage fighting injuries or contraction of an enteritis of undetermined origin. Histologically, the enteritis resembled the acute form of proliferative ileitis ("wet tail"), a common disease of hamsters. Incidences of combined cage fighting injuries and contraction of enteritis were also observed, but these also were not treatment related. Replacement hamsters were incorporated into the groups, as necessary, in additional cages to maintain group sizes until the animals were 10 weeks of age, at which time the remaining extra hamsters were killed (Figure 1).

Figure 1. Schedule of Major Events in the Amosite Asbestos Study

<u>Weeks</u>	<u>Events</u>
-1	Pregnant Dams Obtained - 6 July 77 Start Test Diet
0	Birth
+4	Weaned Weighed Sexed Randomly Grouped - 3/Cage Ecto + Endoparasite Exam
+10	Missexed Hamsters Discarded Alternates Added Remaining Extra Hamsters Discarded
Lifetime	Natural Death or Moribund Sacrifice

#### BODY WEIGHTS AND CLINICAL SIGNS

Amosite asbestos consumption appeared to increase body weight in both male and female hamsters compared to the temporal control groups (Figures 2 and 3). No compound related clinical signs were observed during the entire study.

Occasional skin lesions and bite wounds were observed in both sexes, particularly in males. These injuries decreased after the hamsters reached 20 weeks of age.

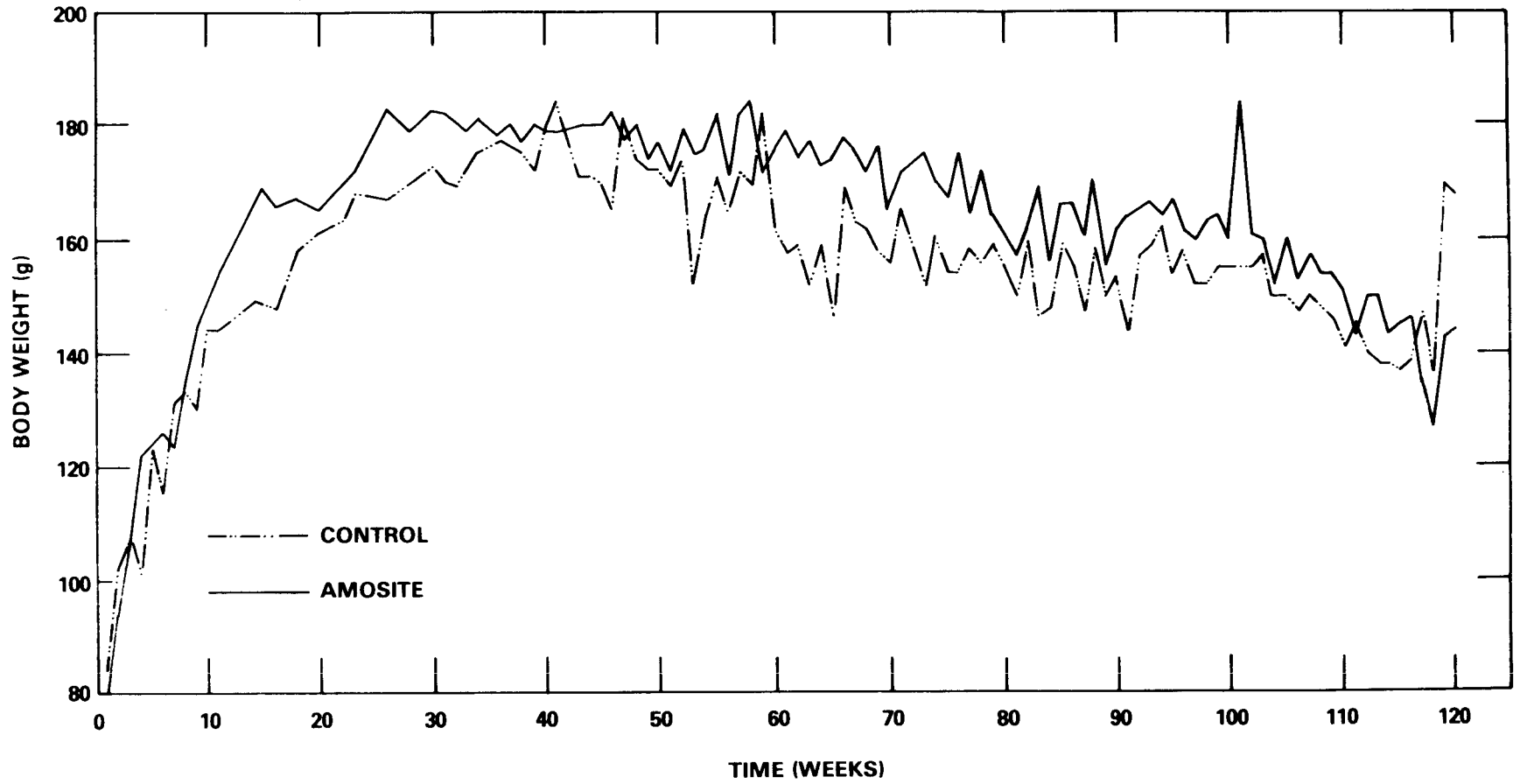


Figure 2. Growth Curves for Male Hamsters Administered Amosite Asbestos in the Diet

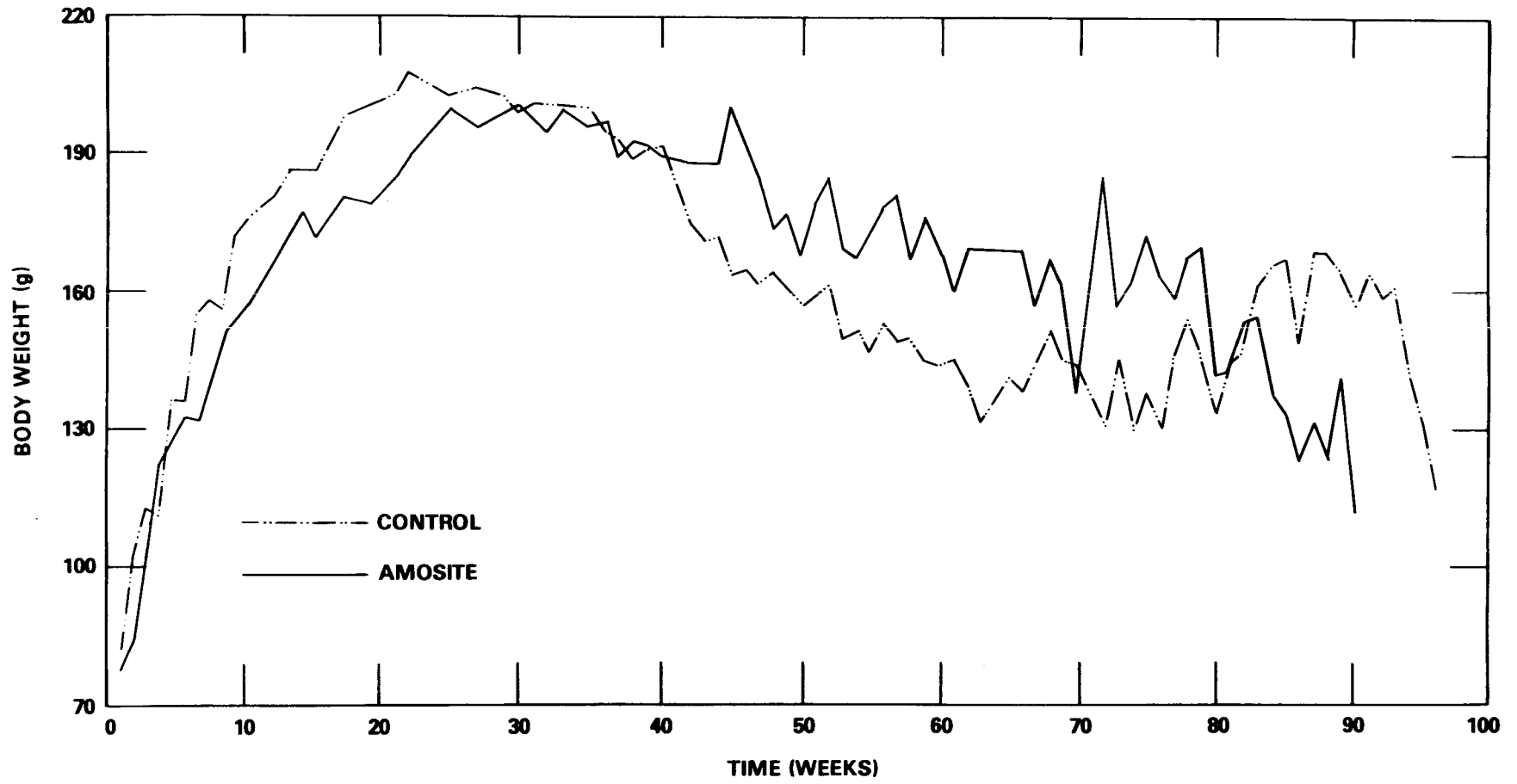


Figure 3. Growth Curves for Female Hamsters Administered Amosite Asbestos in the Diet



### III. RESULTS: SURVIVAL

#### SURVIVAL

The survival rate was significantly ( $P < 0.01$ ) higher in both males and females on the amosite diet when compared with the corresponding control groups (Figures 4 and 5). The median life spans of control and treated females were short-

er than for the corresponding groups of males. The median survival was 55 and 81 weeks, respectively, for control female and male hamsters in contrast to 60 and 84 weeks, respectively, for treated females and males.

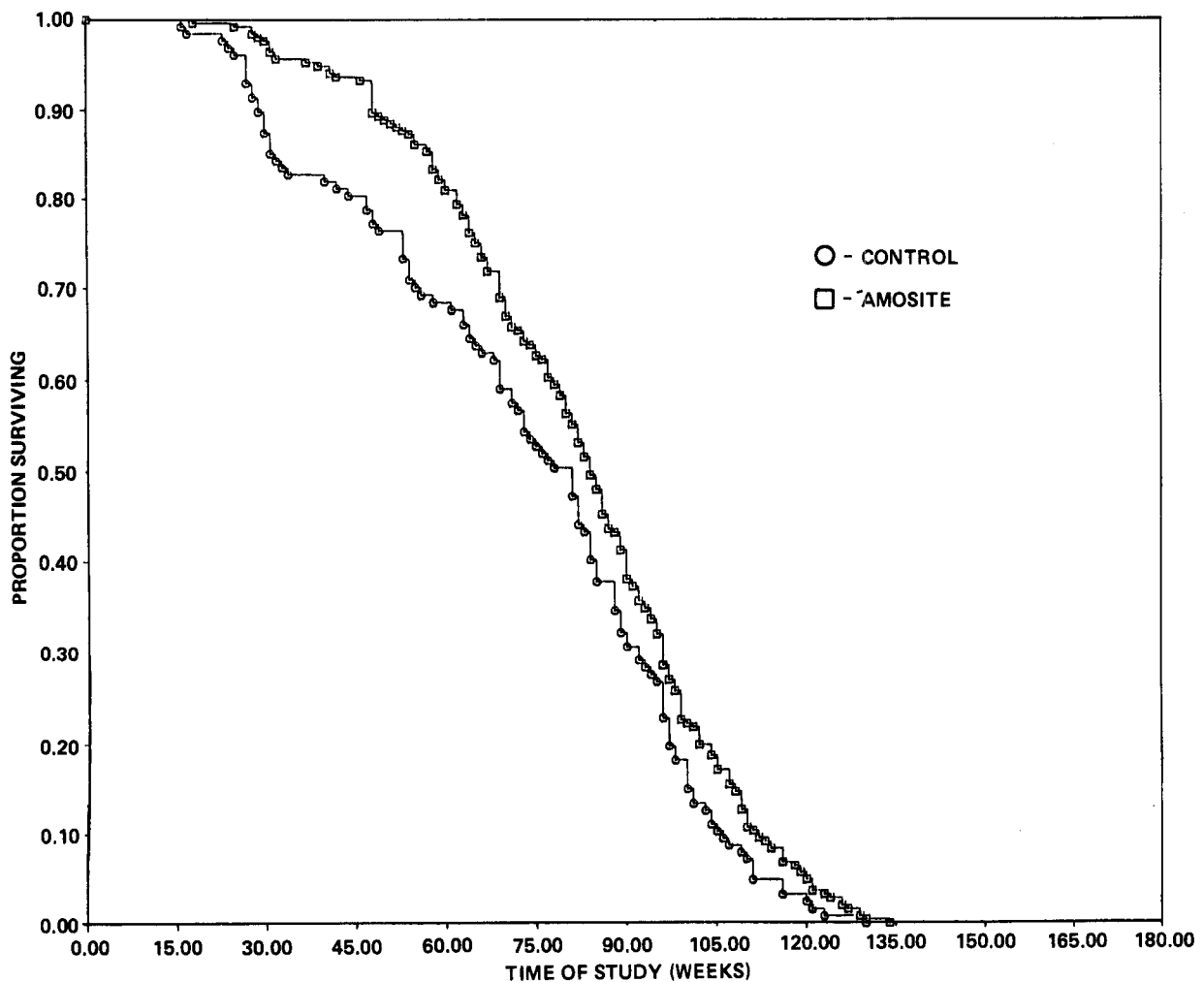


Figure 4. Survival Curves for Male Hamsters Receiving Amosite Asbestos

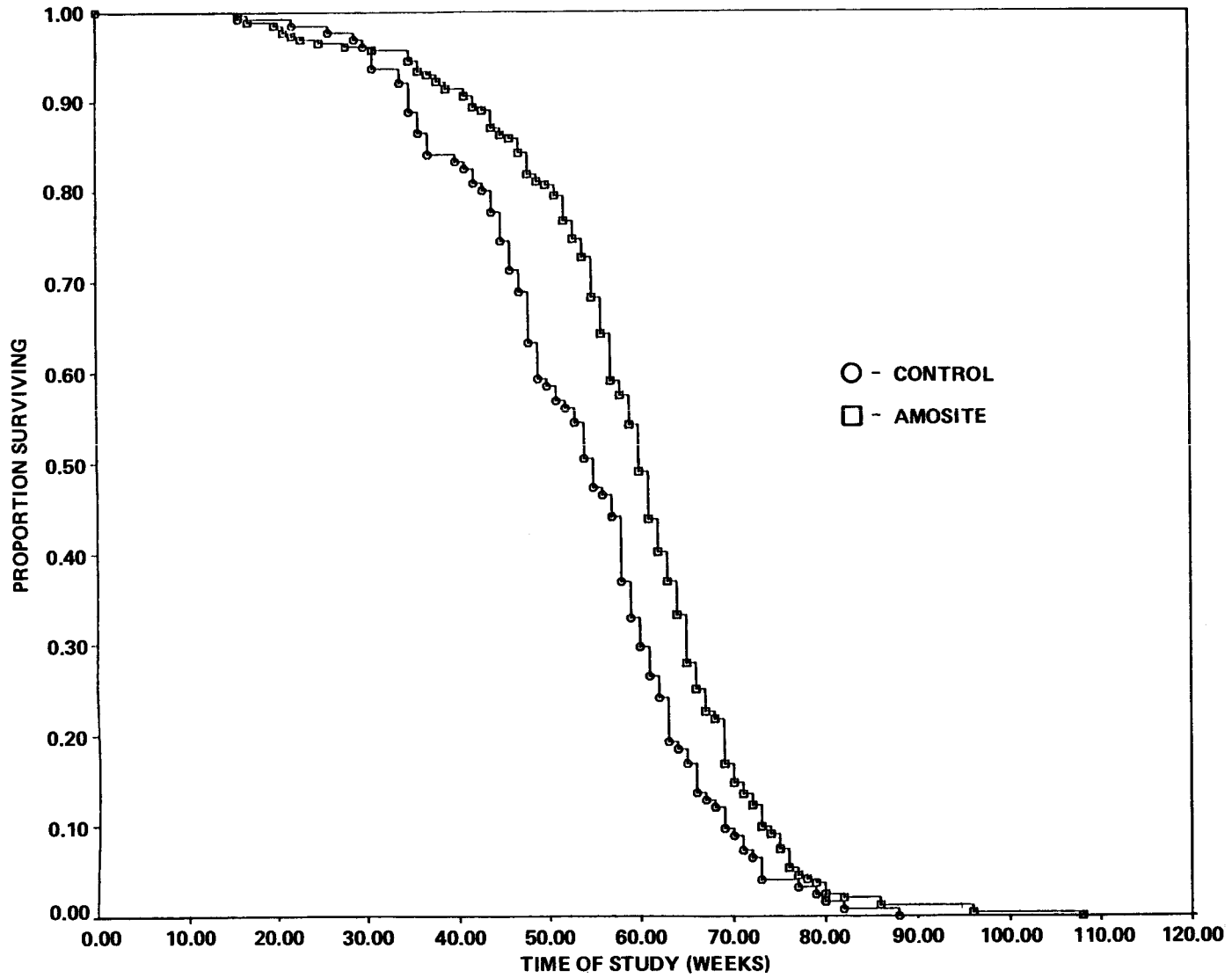


Figure 5. Survival Curves for Female Hamsters Receiving Amosite Asbestos

### III. RESULTS: PATHOLOGY AND STATISTICAL ANALYSES OF RESULTS

#### PATHOLOGY AND STATISTICAL ANALYSES OF RESULTS

The number of hamsters available for histopathologic examination is shown in Table 3. The majority of animals not included in the pathologic analysis were excluded because of autolysis

or cannibalism. A review of the clinical records of hamsters lost to autolysis or cannibalization gave no indication that these animals had neoplasms.

TABLE 3. DISPOSITION OF HAMSTERS FROM THE AMOSITE ASBESTOS FEEDING STUDY

Group	Sex	On Test	Histopathologic Evaluation	Missing	Cannibalized	Autolyzed	Missexed
Control	M	127	122	0	0	4	1
	F	126	119	1	0	1	5
Treated	M	252	248	0	0	3	1
	F	254	237	5	0	5	7

Various neoplasms were observed in control (Tables 4 and 5) and amosite exposed (Tables 6 and 7) hamsters. The proportions of control male and female hamsters bearing primary tumors were not statistically different among the four control groups. Thus, statistical comparisons were made with pooled as well as temporal controls. Male hamsters had a slightly higher rate of neoplasia than the females.

The only statistically significant ( $P < 0.05$ ) difference in tumor incidence observed in this study

was a decrease in islet cell adenomas observed in female hamsters receiving amosite (Table 7). A greater than 4% incidence of neoplasia in treated or control groups was observed for the adrenal gland and pancreas (Islets of Langerhans), and the parathyroid. None of the amosite treated groups showed an increased rate of neoplasia compared to temporal or pooled control groups, particularly in the gastrointestinal tract, which was the proposed target organ (Table 8).

**TABLE 4. INCIDENCE OF PRIMARY TUMORS IN MALE HAMSTER CONTROL GROUPS**

	Amosite Controls	Short Range Chrysotile Controls	Intermediate Range (IR) Chrysotile Controls	DMH (a) and IR Chrysotile Controls
	(%)	(%)	(%)	(%)
Animals with primary tumors	21/122 (17)	21/115 (18)	26/116 (22)	27/119 (23)
Skin or sub. tissues: All tumors	0/122 (0)	0/115 (0)	1/116 (1)	0/119 (1)
Lung and trachea: All tumors	0/120 (0)	0/115 (0)	0/116 (0)	0/119 (0)
Adrenal: Cortical adenoma	8/119 (7)	7/115 (6)	7/115 (3)	3/117 (3)
Cortical carcinoma	3/119 (3)	3/115 (3)	3/115 (3)	4/117 (3)
Pheochromocytoma	3/119 (3)	2/115 (2)	5/115 (4)	3/117 (3)
Other tumors	1/119 (1)	0/115 (0)	3/115 (3)	2/117 (2)
Pancreas: Islet cell adenoma	3/114 (3)	2/111 (2)	7/110 (6)	8/110 (7)
Islet cell carcinoma	0/114 (0)	1/111 (1)	0/110 (0)	0/110 (0)
Thyroid: C-cell adenoma	1/106 (1)	3/109 (3)	3/106 (3)	0/107 (0)
C-cell carcinoma	1/106 (1)	1/109 (1)	1/106 (1)	0/107 (0)
Other	0/106 (0)	0/109 (0)	0/106 (0)	1/107 (1)
Parathyroid: Adenoma	0/64 (0)	0/72 (0)	1/71 (1)	1/64 (2)
G.I. Tract: All tumors	2/122 (1)	2/115 (2)	1/116 (1)	2/119 (2)
Pituitary: All tumors	0/81 (0)	0/84 (0)	0/77 (0)	0/80 (0)
Kidney: All tumors	1/120 (1)	0/115 (0)	2/116 (2)	1/119 (1)
Liver: All tumors	0/120 (0)	0/115 (0)	0/116 (0)	0/119 (0)
Leukemia or malignant lymphoma	1/122 (1)	2/115 (2)	1/116 (1)	4/119 (4)
Hemangioma or Hemangiosarcoma	2/122 (2)	0/115 (0)	0/116 (0)	3/119 (3)
All other tumors	1/122 (1)	1/115 (1)	0/116 (0)	3/119 (3)

(a) 1,2-Dimethylhydrazine dihydrochloride

**TABLE 5. INCIDENCE OF PRIMARY TUMORS IN FEMALE HAMSTER CONTROL GROUPS**

	Amosite Controls	Short Range Chrysotile Controls	Intermediate Range (IR) Chrysotile Controls	DMH (a) and IR Chrysotile Controls
	(%)	(%)	(%)	(%)
Animals with primary tumors	15/119 (13)	19/114 (17)	17/119 (14)	15/120 (12)
Skin or sub. tissues: All tumors	0/119 (0)	0/114 (0)	0/119 (0)	0/120 (0)
Lung and trachea: All tumors	0/119 (0)	0/114 (0)	0/119 (0)	0/119 (0)
Adrenal: Cortical adenoma	2/118 (2)	4/112 (4)	6/118 (5)	3/120 (2)
Cortical carcinoma	0/118 (0)	0/112 (0)	0/118 (0)	0/120 (0)
Pheochromocytoma	0/118 (0)	0/112 (0)	0/118 (0)	0/120 (0)
Other tumors	0/118 (0)	0/112 (0)	0/118 (0)	0/120 (0)
Pancreas: Islet cell adenoma	3/115 (3)	2/109 (2)	5/116 (4)	5/116 (4)
Islet cell carcinoma	0/115 (0)	1/109 (1)	0/116 (0)	0/116 (0)
Thyroid: C-cell adenoma	1/106 (1)	2/107 (2)	3/115 (3)	0/112 (0)
C-cell carcinoma	0/106 (0)	0/107 (0)	0/115 (0)	1/112 (1)
Other tumors	0/106 (0)	2/107 (2)	0/115 (0)	0/112 (0)
Parathyroid: Adenoma	1/61 (1)	3/68 (4)	1/77 (1)	1/74 (1)
G.I. Tract: All tumors	1/119 (1)	1/114 (1)	2/119 (2)	1/120 (1)
Pituitary: All tumors	0/79 (0)	0/77 (0)	2/67 (3)	0/62 (0)
Kidney: All tumors	0/119 (0)	0/114 (0)	1/119 (1)	0/120 (0)
Liver: All tumors	0/118 (0)	0/114 (0)	0/119 (0)	0/119 (0)
Leukemia or malignant lymphoma	2/119 (2)	2/114 (2)	0/119 (0)	3/120 (2)
Hemangioma or hemangiosarcoma	1/119 (1)	0/114 (0)	0/119 (0)	1/120 (1)
Uterus: All tumors	2/119 (2)	3/113 (3)	1/119 (1)	2/120 (2)
All other tumors	2/119 (2)	3/114 (3)	0/119 (0)	1/120 (1)

(a) 1,2-Dimethylhydrazine dihydrochloride

**TABLE 6. INCIDENCE OF PRIMARY TUMORS IN MALE HAMSTERS ADMINISTERED AMOSITE ASBESTOS**

	<b>Amosite Controls</b>	<b>Pooled Controls</b>	<b>Amosite Dosed</b>
	(%)	(%)	(%)
Animals with primary tumors	21/122 (17)	95/472 (20)	57/248 (23)
Skin or sub. tissues: All tumors	0/122 (0)	2/472 (<1)	0/248 (0)
Lung and trachea: All tumors	0/120 (0)	0/470 (0)	0/248 (0)
Adrenal: Cortical adenoma	8/119 (7)	25/466 (5)	13/246 (5)
Cortical carcinoma	3/119 (3)	13/466 (3)	7/246 (3)
Pheochromocytoma	3/119 (3)	13/466 (3)	4/246 (2)
Other tumors	1/119 (1)	6/466 (1)	2/246 (1)
Pancreas: Islet cell adenoma	3/114 (3)	20/445 (4)	11/234 (5)
Islet cell carcinoma	0/114 (0)	1/445 (<1)	0/234 (0)
Thyroid: C-cell adenoma	1/106 (1)	7/428 (2)	7/221 (3)
C-cell carcinoma	1/106 (1)	3/428 (<1)	2/221 (1)
Other tumors	0/106 (0)	1/428 (<1)	2/221 (1)
Parathyroid: Adenoma	0/64 (0)	2/271 (1)	2/150 (1)
G.I. Tract: All tumors	1/122 (1)	6/472 (1)	6/248 (2)
Pituitary: All tumors	0/81 (0)	0/322 (0)	0/182 (0)
Kidney: All tumors	1/120 (1)	4/470 (1)	2/248 (1)
Liver: All tumors	0/120 (0)	0/470 (0)	0/247 (0)
Leukemia or malignant lymphoma	1/122 (1)	8/472 (2)	5/248 (2)
Hemangioma or hemangiosarcoma	2/122 (2)	5/472 (1)	2/248 (1)
All other tumors	1/122 (1)	5/472 (1)	2/248 (1)

**TABLE 7. INCIDENCE OF PRIMARY TUMORS IN FEMALE HAMSTERS ADMINISTERED AMOSITE ASBESTOS**

	Amosite Controls	Pooled Controls	Amosite Dosed
	(%)	(%)	(%)
Animals with primary tumors	15/119 (13)	66/472 (14)	30/237 (13)
Skin or sub. tissues: All tumors	0/119 (0)	0/472 (0)	2/237 (1)
Lung and trachea: All tumors	0/119 (0)	0/471 (0)	0/234 (0)
Adrenal: Cortical adenoma	2/118 (2)	15/468 (3)	6/234 (3)
Cortical carcinoma	0/118 (0)	0/468 (0)	0/234 (0)
Pheochromocytoma	0/118 (0)	0/468 (0)	2/234 (1)
Other tumors	0/118 (0)	0/468 (0)	0/234 (0)
Pancreas: Islet cell adenoma	3/115 (3)	15/456 (3)	2/222 (1) (a)
Islet cell carcinoma	0/115 (0)	1/456 (<1)	0/222 (0)
Thyroid: C-cell adenoma	1/106 (1)	6/440 (1)	4/215 (2)
C-cell carcinoma	0/106 (0)	1/440 (<1)	1/215 (<1)
Other tumors	0/106 (0)	2/440 (<1)	0/215 (0)
Parathyroid: Adenoma	1/61 (2)	6/280 (2)	1/141 (1)
G.I. Tract: All tumors	1/119 (1)	5/472 (1)	4/237 (2)
Pituitary: All tumors	0/79 (0)	2/285 (<1)	0/149 (0)
Kidney: All tumors	0/119 (0)	1/472 (<1)	0/236 (0)
Liver: All tumors	0/118 (0)	0/472 (0)	0/234 (0)
Leukemia or malignant lymphoma	2/119 (2)	7/472 (1)	3/237 (1)
Hemangioma or hemangiosarcoma	1/119 (1)	2/472 (<1)	3/237 (1)
Uterus: All tumors	2/119 (2)	8/471 (2)	1/236 (<1)
All other tumors	2/119 (2)	6/472 (1)	2/237 (1)

(a) P<0.05 decrease relative to pooled controls (life table and incidental tumor tests).

**TABLE 8. INCIDENCE OF GASTROINTESTINAL TRACT TUMORS IN THE AMOSITE ASBESTOS STUDY**

	Amosite Controls		Pooled Controls		Amosite Dosed	
	M	F	M	F	M	F
Stomach (no. examined)	(120)	(117)	(464)	(468)	(247)	(236)
Squamous cell papilloma	1	0	3	0	4	0
Papilloma	0	0	0	0	0	3
Small Intestine (no. examined)	(120)	(117)	(467)	(469)	(246)	(236)
Adenoma	0	0	1	0	0	0
Adenocarcinoma	0	0	1	0	0	0
Large Intestine (no. examined)	(118)	(116)	(464)	(468)	(246)	(235)
Adenoma	0	0	0	1 (a)	0	0
Papillary adenoma	0	0	0	0	1 (a)	0
Adenocarcinoma	0	0	0	1	0	0
Lipoma	0	0	0	1	0	0
Rectum (no. examined)	(122)	(119)	(472)	(272)	(248)	(237)
Adenoma	0	1 (a)	1	1 (a)	0	0
Adenomatous polyp	0	0	0	0	1	0
Fibroma	0	0	0	1	0	0
Squamous cell papilloma	0	0	0	0	0	1

(a) These lesions were diagnosed by the original pathologist and were not confirmed by the NTP Pathology Working Group.

### III. RESULTS: PATHOLOGY AND STATISTICAL ANALYSES OF RESULTS

---

The diagnoses of the original pathologist and the NTP Pathology Working Group (PWG) differed on whether certain adrenal tumors originated in the medulla or cortex. As shown in Table 9, the PWG diagnoses revealed fewer adrenal medullary tumors and more adrenal cortical tumors. This discrepancy did not alter the results of the study. The criteria used by the NTP/PWG for the diagnosis of adrenal tumors were based on those reported by Homburger and Russfield (1970), Matsuyama and Suzuki (1970), and Murthy and Russfield (1966). These criteria were as follows:

#### Adrenal Cortex:

1. Focal hyperplasia—Proliferation of normal appearing cells resembling those of the zona fasciculata. The cells were of uniform size and morphology and mitotic figures were not observed. These lesions were invariably observed in adrenals showing severe amyloidosis. Another type of hyperplastic lesion involved extracapsular nodules of normal appearing cortical tissue, which were completely encased in a connective tissue capsule.
2. Cortical adenoma—One of the two types observed was composed of cells resembling the zona fasciculata, which were pheomorphic and compressed the adjacent parenchyma. The second type contained similar cells but admixed between them were spindle shaped cells which resembled fibroblasts. Mitotic figures were rare. The border of both types of adenomas was well defined but no capsule was evident.
3. Neurolemmoma—This tumor was composed of delicate spindle cells arranged in parallel palisades. It was circumscribed but nonencapsulated. No mitotic figures were observed. The neurolemmomas were observed much less frequently than the previously described adenomas.
4. Cortical carcinoma—Carcinomas were composed of cells resembling both types of the above described adenomas. They were differentiated from adenomas based on pleomorphism, nuclear atypia, increased numbers of mitotic figures, and invasive growth through the capsule and/or into adjacent blood vessels. Areas of necrosis and hemorrhage were common.

#### Adrenal Medulla:

1. Hyperplasia—This lesion was characterized by proliferation of normal appearing cells, although an increase in basophilia was sometimes noted. The normal architecture was preserved and the lesion was usually diffuse.
2. Pheochromocytoma—This lesion consisted of a focal nodular proliferation of normal or smaller than normal appearing uniform cells. Mitotic figures were not observed. Growth was by expansion. The borders were distinct and there appeared to be a delicate capsule.
3. Malignant pheochromocytoma—The major distinguishing characteristics of this neoplasm were nuclear atypia and invasive growth.

The major difference in terminology between the original pathologist and the NTP/PWG was in regard to those benign and malignant adrenal tumors that were composed of spindle-shaped and eosinophilic hepatoid-like cells. The original pathologist diagnosed these tumors as pheochromocytomas or malignant pheochromocytomas, while the PWG diagnosed them as cortical adenomas or carcinomas.

While this study was not designed to evaluate nonneoplastic disease, generalized amyloidosis was observed and caused many deaths. This disease apparently was not treatment-related and its appearance is considered normal in aging hamsters. The kidneys were particularly affected by diffuse accumulation of amyloid, which replaced glomeruli, infiltrated tubular interstitium, and obliterated the normal cortical architecture. Other organs which showed significant accumulations of amyloid were the adrenal gland, liver, spleen, and the epithelium of the small intestine. Amyloid was observed in many tissues within the walls of blood vessels.

Many of the livers were cirrhotic and infiltrated with amyloid, and contained large cystic structures filled with a lightly staining proteinaceous fluid. Interpreted as cystic bile ducts, these structures are consistent with so-called retention cysts. At times, these cysts were large and/or numerous enough to displace more than half of the liver.

Other non-treatment-related, nonneoplastic lesions that were observed in greater than 5% of the hamsters in any of the experimental groups were: skin—chronic dermatitis; lung—interstitial pneumonitis; spleen—lymphoid atrophy; lymph node—hyperplasia; heart—atrial thrombosis;



### III. RESULTS: PATHOLOGY AND STATISTICAL ANALYSES OF RESULTS

stomach (nonglandular)—hyperkeratosis or acanthosis; urinary bladder—hyperplasia; adrenal gland—cortical and medullary hyperplasia; thyroid gland—follicular atrophy; prostate—inflam-

mation; seminal vesicle—inflammation; and testes—seminiferous atrophy and interstitial hyperplasia.

**TABLE 9. COMPARISON OF ADRENAL TUMOR INCIDENCE AS DETERMINED BY ORIGINAL PATHOLOGIST AND NTP PATHOLOGY WORKING GROUP (PWG)**

	Amosite Controls	Pooled Controls	Amosite Dosed
	(%)	(%)	(%)
<b>Males (a)</b>			
Cortical adenoma	8/119 (7)	25/466 (5)	13/246 (5)
Cortical carcinoma	3/119 (3)	13/466 (3)	7/246 (3)
Pheochromocytoma	3/119 (3)	13/466 (3)	4/246 (1)
Other	1/119 (1)	6/466 (1)	2/246 (1)
<b>Males (b)</b>			
Cortical adenoma	9/119 (8)	31/466 (7)	18/246 (7)
Cortical carcinoma	3/119 (3)	14/466 (3)	7/246 (3)
Pheochromocytoma	1/119 (1)	7/466 (2)	0/246 (0)
Other	0/119 (0)	2/466 (<1)	0/246 (0)
<b>Females (a)</b>			
Cortical adenoma	2/118 (2)	15/468 (3)	6/234 (3)
Cortical carcinoma	0/118 (0)	0/468 (0)	0/234 (0)
Pheochromocytoma	0/118 (0)	0/468 (0)	2/234 (1)
Other	0/118 (0)	0/468 (0)	0/234 (0)
<b>Females (b)</b>			
Cortical adenoma	4/118 (2)	19/468 (4)	8/234 (3)
Cortical carcinoma	0/118 (0)	0/468 (0)	0/234 (0)
Pheochromocytoma	0/118 (0)	0/468 (0)	1/234 (<1)
Other	0/118 (0)	0/468 (0)	0/234 (0)

(a) Original pathologist

(b) NTP Pathology Working Group



#### **IV. SUMMARY, COMMENTS, AND CONCLUSION**

#### IV. SUMMARY, COMMENTS, AND CONCLUSION

---

The clinicopathologic results in this study showed that the ingestion of 1% amosite asbestos in the diet throughout the lifetime of Syrian golden hamsters inexplicably seemed to enhance body weight gain and survival. The ingestion of amosite asbestos by these hamsters did not cause an increase of tumors at any anatomic site when compared to temporal or pooled control groups. An apparent increase in adrenal cortical tumors that was observed in a concurrent study of short range and intermediate range chrysotile asbestos (NTP, 1983) was not observed in the amosite asbestos study.

Other such studies involving the long-term ingestion of asbestos are few. Donham et al. (1980) reported equivocal results in F344 rats which were fed a diet containing 10% chrysotile for their lifetime. While they did not observe a statistically significant ( $P < 0.05$ ) increase in the number of tumors in exposed animals, the authors believed that there was a trend toward increased colon lesions, evidence of penetration of asbestos into the colonic mucosa, and possible cytotoxicity to colonic tissues, suggesting a relationship to peritoneal mesothelioma. In another equivocal study, Gibel et al. (1976) reported an increase in malignant tumors in the lung, kidney, liver, and reticuloendothelial system but no increase in intestinal neoplasia in Wistar rats fed asbestos filter material at 20 mg/day for 8-14 months. Cunningham et al. (1977) reported on 24- and 30-month studies in male Wistar rats using 1% chrysotile in the diet. No intestinal tumors were found in the control rats. Results reported by Gross et al. (1974), who fed rats a diet containing 5% chrysotile asbestos for 21 months, showed no evidence of intestinal neoplasia.

The only other oral asbestos study in hamsters identified in the literature was reported by Smith et al. (1980). They exposed groups of 30 male and 30 female hamsters for their lifetime via drinking water to amosite asbestos, mine tailings, beach rock, and Lake Superior drinking water. No adverse effects on body weight or survival time were observed in any of the groups. One peritoneal mesothelioma, one pulmonary carcinoma, and two early squamous cell carcinomas of the nonglandular stomach were found in those hamsters that were exposed to amosite asbestos, but the incidence was not statistically significant ( $P < 0.05$ ).

Except for those of Donham et al. (1980) and Smith et al. (1980), these long-term studies were

conducted with relatively small numbers of animals. Some were conducted for an insufficient period of time to adequately test the carcinogenic potential of ingested asbestos.

A long-term study to determine the promoter potential of amosite asbestos was reported by Ward et al. (1980). Six-week-old male F344 rats were exposed 3 times per week for 10 weeks to 1 mg amosite asbestos in saline via gavage. Once per week during this same period half of the rats received subcutaneous injections of 7.4 mg/kg azoxymethane (AOM), a known intestinal carcinogen in animals. The rats were allowed to live out their life span or until they reached 94-95 weeks of age, at which time they were killed. The authors reported an intestinal tumor incidence of 66.7% for AOM alone, 77.1% for amosite asbestos plus AOM, and 32.6% for amosite asbestos alone. They conclude that while amosite asbestos did not significantly add to the incidence of AOM-induced intestinal neoplasia, amosite alone caused a relatively high rate of intestinal neoplasia. However, there was no untreated control group to compare to the treated groups. These authors also reported a 14% incidence of Zymbal gland tumors in the rats exposed to amosite asbestos alone. The historical rate of Zymbal gland tumors in the Program is 0.34%, indicating that this neoplasm is an extremely rare spontaneous tumor. However, a single dose of 5.1 mg/kg AOM in male F344 rats induced a 14% incidence of Zymbal gland tumors (Ward, 1975). In this study, 5.1 mg/kg AOM also caused a 24% incidence of intestinal neoplasia. The incidence of Zymbal gland tumors in the amosite asbestos groups may have resulted from inadvertent exposure to AOM. If this occurred, these hamsters would also be expected to show a high incidence of intestinal neoplasms.

This investigation of the carcinogenic potential of ingested asbestos is a two-animal-species effort by the National Institute of Environmental Health Sciences/ National Toxicology Program. While the results in the hamster appear to be negative, carcinogenesis studies involving more types of asbestos, but using essentially the same protocol (1% diet), in rats are currently being evaluated.

*Conclusion: Under the conditions of these studies, the ingestion of amosite asbestos at a level of 1% in the diet for their lifetime was not toxic and did not cause a carcinogenic response in male and female Syrian golden hamsters.*

## **V. REFERENCES**

## V. REFERENCES

---

- Bey, E.; Harrington, J.S., Cytotoxic effects of some mineral dusts on Syrian hamster peritoneal macrophages. *J. Exptl. Med.* 133:1149-1169; 1971.
- Carter, R.E.; Taylor, W.G., Identification of a particular amphibole asbestos fiber in tissues of persons exposed to high oral intake of the mineral. *Environ. Res.* 21:85-93; 1980.
- Chamberlain, M.; Tarmy, E.M., Asbestos and glass fibers in bacterial mutation tests. *Mutation Res.* 43:159-164; 1977.
- Cook, P.M.; Olson, G.F., Ingested mineral fibers: elimination in human urine. *Science* 204:195-198; 1979.
- Cooper, R.C.; Murchio, J.C.; Paffenbarger, R.S., Asbestos in domestic water supplies for five California counties. Part II, EHS Publ. No. 79-1, School of Public Health, Univ. Calif. Berkeley. 247; 1979. In: EPA, Ambient water quality criteria for asbestos, EPA 440/5-80-022, US EPA, Washington, D.C.; 1980.
- Cox, D.R., Regression models and life tables. *J.R. Stat. Soc.* B34:187-220; 1972.
- Cunningham, H.M.; Moodie, C.A.; Lawrence, G.A.; Pontefract, R.D., Chronic effects of ingested asbestos in rats. *Arch. Environ. Contam. Toxicol.* 6:507-513; 1977.
- Cunningham, H.M.; Pontefract, R.D., Asbestos fibers in beverages and drinking water. *Nature* 232:332-333; 1971.
- Donham, K.J., Berg, J.W., Will, L.A.; Leininger, J.R., The effects of long term ingestion of asbestos on the colon of F344 rats. *Cancer* 45:1073-1084; 1980.
- EHP, Environmental Health Perspectives, Proceedings of the joint NIEHS-EPA conference on biological effects of ingested asbestos. *Environ. Health Perspect.* 9:113-462; 1974.
- EPA, Environmental Protection Agency, Ambient water quality criteria for asbestos. EPA 440/5-80-022, 153 pages, EPA, Washington, DC, October 1980.
- Gart, J.; Chu, K.; Tarone, R., Statistical issues in interpretation of chronic bioassay tests for carcinogenicity. *J. Natl. Cancer Inst.* 62(4):957-974; 1979.
- Gibel, W.; Lohs, K.H.; Horn, K.H.; Wildner, G.P.; Hoffman, F., Investigation into a carcinogenic effect of asbestos filter materials following oral intake in experimental animals. *Archiv. fur Geschwulstforschung* 46:437-442; 1976.
- Gross, P.; Harley, R.A.; Swinberne, L.M.; Davis, J.M.G.; Green, W.B., Ingested mineral fibers, do they penetrate tissue or cause cancer? *Arch. Environ. Hlth.* 29:341-347; 1974.
- Harrington, J.M.; Craun, G.F.; Meigs, J.W.; Landrigen, P.J.; Flannery, J.T., An investigation of the use of asbestos cement pipe for public water supply and the incidence of gastrointestinal cancer in Connecticut, 1935-1973. *Am. J. Epidemiol.* 107:96-103; 1978.
- Homburger, F.; Russfield, A.B., Inbred line of Syrian hamsters with frequent spontaneous adrenal tumors. *Cancer Res.* 30:305-308; 1970.
- IARC, International Agency for Research on Cancer, Asbestos, IARC Monographs on the evaluation of the carcinogenic risk of chemicals to man. Vol. 14. Lyon, France, 1977, pp. 1-106.
- Kanarek, M.S.; Conforti, P.M.; Jackson, L.A.; Cooper, R.C.; Murchio, J.C., Asbestos in drinking water and cancer incidence in the San Francisco Bay area. *Am. J. Epidemiol.* 112:54-72; 1980.
- Kaplan, E.L.; Meier, P., Nonparametric estimation from incomplete observations. *J. Amer. Statist. Assoc.* 53:457-481; 1958.
- Levine, R.J., Asbestos: An information resource. National Institutes of Health, Department of Health and Human Services, NIH 78-1681, 1978.
- Mantel, N.; Haenszel, W., Statistical aspects of the analysis of data from retrospective studies of disease. *J. Natl. Cancer Inst.* 22:719-748; 1959.
- Matsuyama, M.; Suzuki, H., Adrenal tumours and endocrine lesions induced in Syrian hamsters by urethane injection during suckling period. *Brit. J. Cancer* 24:312-318; 1970.
- Merliss, R.R., Talc and asbestos contamination of rice. *JAMA* 216:2144; 1971a.
- Merliss, R.R., Talc-treated rice and Japanese stomach cancer. *Science* 173:1141-1142; 1971b.
- Millette, J.R., Exposure to asbestos from drinking water in the United States. EPA 600/1-79-150, 1979.
- Murthy, A.S.K.; Russfield, A.B., Evidence for three types of benign adrenal tumors in Syrian hamsters. *Arch. Path.* 81:140-145; 1966.

## V. REFERENCES

---

NTP, National Toxicology Program, NTP Technical report on the carcinogenesis bioassay of chrysotile asbestos in syrian golden hamsters. NTP TR 246, Department of Health and Human Services, Research Triangle Park, North Carolina, 1983.

Peto, R.; Pike, M.; Day, N.; Gray, R.; Lee, P.; Parish, S.; Peto, J.; Richard, S.; Wahrendorf, J., Guidelines for simple, sensitive significant tests for carcinogenic effects in long-term animal experiments. In: International Agency for Research Against Cancer, Monographs on the long-term and short-term screening assays for carcinogens: a critical appraisal. Geneva: World Health Organization, Supplement 2:311-426; 1980.

Reiss, B., Weisburger, J.H.; Williams, G.M., Asbestos and gastrointestinal cancer: cell culture studies. Environmental Protection Agency, EPA-600/1-79-023, July 1979.

Selikoff, I.J., Asbestos-associated disease. In: Maxcy-Rosehau's Public Health and Preventive Medicine, 11th Edition, J.M. Last, (ed.), Appleton-Century-Croft, 1980, pp. 568-589.

Selikoff, I.J.; Hammond, E.C., (eds.), Health hazards of asbestos exposure. *Ann. N.Y. Acad. Sci.* 330:1-814; 1979.

Smith, W.E.; Hubert, D.D.; Sobel, H.J.; Peters, E.T.; Doerfler, T.E., Health in experimental animals drinking water with and without amosite and other mineral particles. *J. Environ. Pathol. Toxicol.* 3:277-300; 1980.

Storeygard, A.R.; Brown, A.L., Penetration of the small intestinal mucosa by asbestos fibers. *Mayo Clin. Proc.* 52:809-812; 1977.

Ward, J.M., Dose response to a single injection of azoxymethane in rats. *Vet. Pathol.* 12:165-177; 1975.

Ward, J.M.; Frank, A.L.; Wenk, M.; Devor, D.; Tarone, R.E., Ingested asbestos with frequent spontaneous adrenal tumors. *J. Environ. Pathol. Toxicol.* 3:301-312; 1980.

Weisburger, J.H.; Williams, G.M., Chemical carcinogens. In: *Toxicology: the basic science of poisons*. Second Edition, J. Doull and C. Klaasen, eds., New York: MacMillan Publishing Co., Inc.; 1979.





## **APPENDIX A**

### **CALCULATED VALUES OF AMOSITE ASBESTOS IN INDIVIDUAL LOTS OF FEED AS DETERMINED BY MAGNESIUM CONTENT**

## APPENDIX A

---

Five pellets from the asbestos dosed and seven pellets from the control diet were individually crushed, transferred to a tared crucible, and weighed. The sample sizes for the assays were 350 to 500 mg of asbestos-containing diet and 1000 to 1500 mg of control diet. The crucibles containing the diet were placed in a muffle furnace and ashed overnight at 550°C. After cooling, the ashed samples were quantitatively transferred to 100-ml beakers. Twenty ml of a 1:1:2 solution of nitric and hydrofluoric acid in distilled water were added to each beaker and the beakers were placed in a sandbath for 24 hours at 177°C. The digested sample was quantitatively transferred to a volumetric flask and a sufficient quantity of a stock solution containing potassium, lanthanum, and hydrochloric acid was added to provide a final concentration of 100 mg/l of K<sup>+</sup> and 30 mg/l of La<sup>++</sup> at a pH below 3. The quantity of asbestos was determined by measuring the magnesium content by atomic absorption spectroscopy.

Results of the analyses are presented in Table A1.

**TABLE A1. CALCULATED VALUES OF AMOSITE ASBESTOS IN INDIVIDUAL LOTS OF FEED AS DETERMINED BY MAGNESIUM CONTENT**

<u>Feed Preparation Date</u>	<u>Asbestos Content (%)</u>
06/23/77	1.04 ± 0.07
09/21/77	1.07 ± 0.14
12/07/77	1.09 ± 0.17
02/01/78	1.16 ± 0.13
03/22/78	1.04 ± 0.08
05/22/78	1.08 ± 0.06
07/11/78	0.79 ± 0.01
07/11/78	0.96 ± 0.04
10/79	0.97
	Mean = 1.02 ± 0.21

## **APPENDIX B**

### **DISEASE STATUS OF HAMSTERS EXPOSED TO AMOSITE ASBESTOS**

**TABLE B1. DISEASE STATUS OF HAMSTERS EXPOSED TO AMOSITE ASBESTOS**

Organism	Control		Asbestos (Amosite)	
	Mother	Offspring	Mother	Offspring
<i>Mycoplasma</i> spp.	-	-	-	-
<i>Corynebacterium kutscheri</i>	-	-	-	-
<i>Salmonella</i> spp.	-	-	-	-
<i>Streptobacillus moniliformis</i>	-	-	-	-
<i>Streptococcus pneumoniae</i>	-	-	-	-
<i>Haemobartonella</i> spp.	-	-	-	-
<i>Encephalitozoon</i> spp.	-	-	-	-
<i>Aspicularis tetraptera</i>	-	-	-	-
<i>Syphacia obvelata</i>	-	-	-	-
<i>Taxoplasma gondii</i>	-	-	-	-
<i>Hymenolepis diminuta or nana</i>	-	-	-	-
<i>Trichomonas</i> spp.	+++	+++	+++	+++
<i>Hexamita muris</i>	++	++	++	++
<i>Giardia muris</i>	++	++	++	++
<i>Lymphocytic choriomeningitis</i>	-	-	-	-
Mites	-	-	-	-
Fleas	-	-	-	-
Lice	-	-	-	-

## **APPENDIX C**

### **SUMMARY OF THE INCIDENCE OF NEOPLASMS IN HAMSTERS ADMINISTERED AMOSITE ASBESTOS IN THE DIET**

TABLE C1.

SUMMARY OF THE INCIDENCE OF NEOPLASMS IN MALE HAMSTERS ADMINISTERED AMOSITE ASBESTOS IN THE DIET

	CONTROL	AMOSITE
ANIMALS INITIALLY IN STUDY	127	252
ANIMALS NECROPSIED	122	248
ANIMALS EXAMINED HISTOPATHOLOGICALLY	121	248
-----		
INTEGUMENTARY SYSTEM		
NONE		
-----		
RESPIRATORY SYSTEM		
#LUNG	(120)	(248)
CORTICAL CARCINOMA, METASTATIC	1 (1%)	
OSTEOSARCOMA, METASTATIC		1 (0%)
-----		
HEMATOPOIETIC SYSTEM		
*MULTIPLE ORGANS	(122)	(248)
MALIG.LYMPHOMA, LYMPHOCYTIC TYPE		4 (2%)
MALIG.LYMPHOMA, HISTIOCYTIC TYPE	1 (1%)	1 (0%)
#LYMPH NODE	(121)	(246)
PLASMA-CELL TUMOR	1 (1%)	
-----		
CIRCULATORY SYSTEM		
#SPLEEN	(117)	(243)
HEMANGIOMA	1 (1%)	
HEMANGIOSARCOMA	1 (1%)	
#MEDIASTINAL L.NODE	(121)	(246)
HEMANGIOSARCOMA		1 (0%)
*STERNAL SYNCHONDROSI	(122)	(248)
HEMANGIOMA		1 (0%)
#LIVER	(120)	(247)
HEMANGIOSARCOMA	1 (1%)	
-----		
DIGESTIVE SYSTEM		
#CARDIAC STOMACH	(120)	(247)
SQUAMOUS CELL PAPILOMA	1 (1%)	4 (2%)
#COLON	(118)	(246)
PAPILLARY ADENOMA		1 (0%)
SARCOMA, NOS, METASTATIC	1 (1%)	
*RECTUM	(122)	(248)
ADENOMATOUS POLYP, NOS		1 (0%)
-----		
URINARY SYSTEM		
#KIDNEY	(120)	(248)
TRANSITIONAL-CELL CARCINOMA		1 (0%)
ADENOCARCINOMA, NOS		1 (0%)
#KIDNEY/CORTEX	(120)	(248)
ADENOCARCINOMA, NOS	1 (1%)	
-----		
#	NUMBER OF ANIMALS WITH TISSUE EXAMINED MICROSCOPICALLY	
*	NUMBER OF ANIMALS NECROPSIED	

**TABLE C1. MALE HAMSTERS: NEOPLASMS (CONTINUED)**

	<b>CONTROL</b>	<b>AMOSITE</b>
<b>ENDOCRINE SYSTEM</b>		
#ADRENAL	(119)	(246)
CORTICAL ADENOMA	8 (7%)	13 (5%)
CORTICAL CARCINOMA	3 (3%)	7 (3%)
PHEOCHROMOCYTOMA	3 (3%)	4 (2%)
NEUROBLASTOMA		1 (0%)
NEURILEMOMA	1 (1%)	1 (0%)
#THYROID	(106)	(221)
ADENOMA, NOS		2 (1%)
C-CELL ADENOMA	1 (1%)	7 (3%)
C-CELL CARCINOMA	1 (1%)	2 (1%)
#PARATHYROID	(64)	(150)
ADENOMA, NOS		2 (1%)
#PANCREATIC ISLETS	(114)	(234)
ISLET-CELL ADENOMA	3 (3%)	11 (5%)
-----		
<b>REPRODUCTIVE SYSTEM</b>		
NONE		
-----		
<b>NERVOUS SYSTEM</b>		
NONE		
-----		
<b>SPECIAL SENSE ORGANS</b>		
NONE		
-----		
<b>MUSCULOSKELETAL SYSTEM</b>		
*RIB	(122)	(248)
OSTEOSARCOMA		1 (0%)
*MUSCLE OF LEG	(122)	(248)
FIBROSARCOMA		1 (0%)
-----		
<b>BODY CAVITIES</b>		
NONE		
-----		
<b>ALL OTHER SYSTEMS</b>		
NONE		
-----		
<b>ANIMAL DISPOSITION SUMMARY</b>		
ANIMALS INITIALLY IN STUDY	127	252
NATURAL DEATH <sup>a</sup>	110	202
MORIBUND SACRIFICE	17	50
SCHEDULED SACRIFICE		
ACCIDENTALLY KILLED		
TERMINAL SACRIFICE		
ANIMAL MISSING		
-----		
<sup>a</sup> INCLUDES AUTOLYZED ANIMALS		
-----		
# NUMBER OF ANIMALS WITH TISSUE EXAMINED MICROSCOPICALLY		
* NUMBER OF ANIMALS NECROPSIED		

**TABLE C1. MALE HAMSTERS: NEOPLASMS (CONTINUED)**

	CONTROL	AMOSITE
<b>TUMOR SUMMARY</b>		
TOTAL ANIMALS WITH PRIMARY TUMORS*	21	57
TOTAL PRIMARY TUMORS	27	67
TOTAL ANIMALS WITH BENIGN TUMORS	15	40
TOTAL BENIGN TUMORS	18	47
TOTAL ANIMALS WITH MALIGNANT TUMORS	7	20
TOTAL MALIGNANT TUMORS	8	20
TOTAL ANIMALS WITH SECONDARY TUMORS#	2	1
TOTAL SECONDARY TUMORS	2	1
TOTAL ANIMALS WITH TUMORS UNCERTAIN- BENIGN OR MALIGNANT	1	
TOTAL UNCERTAIN TUMORS	1	
TOTAL ANIMALS WITH TUMORS UNCERTAIN- PRIMARY OR METASTATIC		
TOTAL UNCERTAIN TUMORS		

\* PRIMARY TUMORS: ALL TUMORS EXCEPT SECONDARY TUMORS

# SECONDARY TUMORS: METASTATIC TUMORS OR TUMORS INVASIVE INTO AN ADJACENT ORGAN



TABLE C2.

**SUMMARY OF THE INCIDENCE OF NEOPLASMS IN FEMALE HAMSTERS ADMINISTERED  
AMOSITE ASBESTOS IN THE DIET**

	CONTROL	AMOSITE
ANIMALS INITIALLY IN STUDY	126	254
ANIMALS MISSING		5
ANIMALS NECROPSIED	119	237
ANIMALS EXAMINED HISTOPATHOLOGICALLY	119	237
<b>INTEGUMENTARY SYSTEM</b>		
*SUBCUT TISSUE	(119)	(237)
FIBROSARCOMA		2 (1%)
<b>RESPIRATORY SYSTEM</b>		
#LUNG	(119)	(234)
FIBROSARCOMA, METASTATIC		1 (0%)
<b>HEMATOPOIETIC SYSTEM</b>		
*MULTIPLE ORGANS	(119)	(237)
#SPLEEN	(119)	(237)
FIBROSARCOMA, METASTATIC		1 (0%)
#LYMPH NODE	(117)	(236)
MALIG. LYMPHOMA, LYMPHOCYTIC TYPE		1 (0%)
#MESENTERIC L. NODE	(117)	(236)
MALIG. LYMPHOMA, HISTIOCYTIC TYPE		1 (0%)
#RENAL LYMPH NODE	(117)	(236)
MALIG. LYMPHOMA, HISTIOCYTIC TYPE		1 (0%)
<b>CIRCULATORY SYSTEM</b>		
#SPLEEN	(119)	(237)
HEMANGIOMA		1 (0%)
HEMANGIOSARCOMA		2 (1%)
#OVARY	(117)	(225)
<b>DIGESTIVE SYSTEM</b>		
#STOMACH	(117)	(236)
PAPILLOMA, NOS		1 (0%)
#CARDIAC STOMACH	(117)	(236)
PAPILLOMA, NOS		2 (1%)
*RECTUM	(119)	(237)
*ANUS	(119)	(237)
SQUAMOUS CELL PAPILLOMA		1 (0%)
<b>URINARY SYSTEM</b>		
#KIDNEY	(119)	(236)
SARCOMA, NOS, METASTATIC		1 (0%)
#URINARY BLADDER	(117)	(225)
TRANSITIONAL-CELL PAPILLOMA		1 (0%)

\* NUMBER OF ANIMALS WITH TISSUE EXAMINED MICROSCOPICALLY  
# NUMBER OF ANIMALS NECROPSIED

**TABLE C2. FEMALE HAMSTERS:NEOPLASMS(CONTINUED)**

	<b>CONTROL</b>	<b>AMOSITE</b>
<b>ENDOCRINE SYSTEM</b>		
#ADRENAL	(11)	(234)
CORTICAL ADENOMA	2 (2%)	6 (3%)
PHEOCHROMOCYTOMA		2 (1%)
#THYROID	(106)	(215)
C-CELL ADENOMA	1 (0%)	4 (2%)
C-CELL CARCINOMA		1 (0%)
#PARATHYROID	(61)	141
ADENOMA, NOS	1 (2%)	1 (0%)
#PANCREATIC ISLETS	(115)	(222)
ISLET CELL ADENOMA	3 (3%)	2 (1%)
*MAMMARY GLAND	(119)	(237)
*VAGINA	(119)	(237)
PAPILLOMA, NOS		1 (0%)
#UTERUS	(119)	(236)
PAPILLARY CARCINOMA	1 (0%)	1 (0%)
#UTERUS/ENDOMETRIUM	(119)	(236)
#OVARY	(117)	(225)
<hr/>		
NERVOUS SYSTEM		
<hr/>		
SPECIAL SENSE ORGANS		
<hr/>		
MUSCULOSKELETAL SYSTEM		
<hr/>		
BODY CAVITIES		
<hr/>		
OTHER SYSTEMS		
*MULTIPLE ORGANS	(119)	(237)
FIBROSARCOMA, METASTATIC		1 (0%)
<hr/>		
ANIMAL DISPOSITION SUMMARY		
ANIMALS INITIALLY IN STUDY	126	254
NATURAL DEATHS	123	232
MORIBUND SACRIFICE	2	16
ACCIDENTALLY KILLED		1
ANIMAL MISSING		5
<hr/>		
INCLUDES AUTOLYZED ANIMALS		

\*NUMBER OF ANIMALS WITH TISSUE EXAMINED MICROSCOPICALLY  
#NUMBER OF ANIMALS NECROPSIED

	<b>CONTROL</b>	<b>AMOSITE</b>
<b>TUMOR SUMMARY</b>		
TOTAL ANIMALS WITH PRIMARY TUMORS*	15	30
TOTAL PRIMARY TUMORS	15	31
TOTAL ANIMALS WITH BENIGN TUMORS	11	22
TOTAL BENIGN TUMORS	11	22
TOTAL ANIMALS WITH MALIGNANT TUMORS	3	9
TOTAL MALIGNANT TUMORS	3	9
TOTAL ANIMALS WITH SECONDARY TUMORS#		3
TOTAL SECONDARY TUMORS		4
	-	
	-	
<b>TOTAL UNCERTAIN TUMORS</b>		

PRIMARY TUMORS: ALL TUMORS EXCEPT SECONDARY TUMORS  
SECONDARY TUMORS: METASTATIC TUMORS OR TUMORS INVASIVE INTO AN ADJACENT ORGAN



## **APPENDIX D**

### **INDIVIDUAL ANIMAL TUMOR PATHOLOGY OF HAMSTERS ADMINISTERED AMOSITE ASBESTOS IN THE DIET**

TABLE D1.

INDIVIDUAL ANIMAL TUMOR PATHOLOGY OF MALE HAMSTERS ADMINISTERED AMOSITE ASBESTOS IN THE DIET

CONTROL

ANIMAL NUMBER	0	1	1	1	2	2	2	3	3	4	4	4	5	5	6	6	7	7	8	8	9	9
WEEKS ON STUDY	0	1	3	5	7	1	3	1	2	8	4	9	8	1	2	9	0	1	0	8	8	0
<b>RESPIRATORY SYSTEM</b>																						
LUNGS AND BRONCHI CORTICAL CARCINOMA, METASTATIC	+	+	+	+	+	X	+	+	+	+	+	+	+	+	+	+	+	+	+	+	+	+
TRACHEA	+	+	+	+	+	+	+	+	+	+	+	+	+	+	+	+	+	+	+	+	+	+
<b>HEMATOPOIETIC SYSTEM</b>																						
BONE MARROW	+	+	+	+	+	+	+	-	+	+	+	+	+	+	+	+	+	+	+	+	-	+
SPLEEN HEMANGIOMA HEMANGIOSARCOMA	+	+	+	+	+	+	+	+	+	+	+	+	+	+	+	+	+	+	+	+	+	+
LYMPH NODES PLASMA-CELL TUMOR	+	+	+	+	+	+	+	+	+	+	+	+	+	+	+	+	+	+	+	+	+	+
THYMUS	+	+	-	+	+	+	+	+	-	-	+	+	-	-	+	-	-	-	-	-	+	-
<b>CIRCULATORY SYSTEM</b>																						
HEART	+	+	+	+	+	+	+	+	+	+	+	+	+	+	+	+	+	+	+	+	+	+
<b>DIGESTIVE SYSTEM</b>																						
SALIVARY GLAND	+	+	+	+	+	+	+	+	+	+	+	+	+	+	+	+	+	+	+	+	+	+
LIVER HEMANGIOSARCOMA	+	+	+	+	+	+	+	+	+	+	+	+	+	+	+	+	+	+	+	+	+	+
BILE DUCT	+	+	+	+	+	+	+	+	+	+	+	+	+	+	+	+	+	+	+	+	+	+
GALLBLADDER & COMMON BILE DUCT	N	N	N	N	+	N	N	N	N	+	N	N	N	N	N	N	+	N	N	N	N	N
PANCREAS	+	-	+	+	+	+	+	+	+	+	+	+	+	+	+	+	+	+	+	+	+	+
ESOPHAGUS	+	+	+	+	+	+	+	+	+	+	+	+	+	+	+	+	+	+	+	+	+	+
STOMACH SQUAMOUS CELL PAPILLOMA	+	+	+	+	+	+	+	+	+	+	+	+	+	+	+	+	+	+	+	+	+	+
SMALL INTESTINE	+	+	+	+	+	+	+	+	+	+	+	+	+	+	+	+	+	+	+	+	+	+
LARGE INTESTINE SARCOMA, NOS, METASTATIC	+	+	+	+	+	+	+	+	+	+	+	+	+	+	+	+	+	+	+	+	+	+
<b>URINARY SYSTEM</b>																						
KIDNEY ADENOCARCINOMA, NOS	+	+	+	+	+	+	+	+	+	+	+	+	+	+	+	+	+	+	+	+	+	+
URINARY BLADDER	+	+	+	+	+	+	+	+	+	+	+	+	+	+	+	+	+	+	+	+	+	+
<b>ENDOCRINE SYSTEM</b>																						
PITUITARY	-	+	+	-	+	+	+	+	+	+	+	+	+	+	+	+	-	+	+	-	+	+
ADRENAL CORTICAL ADENOMA CORTICAL CARCINOMA PHEOCHROMOCYTOMA NEURILEIOMA	-	+	+	+	+	+	+	+	+	+	+	+	+	+	+	X	X	+	-	+	+	X
THYROID C-CELL ADENOMA C-CELL CARCINOMA	+	+	+	+	+	+	+	+	+	+	+	+	+	+	+	+	+	+	+	-	+	+
PARATHYROID	-	+	-	+	-	+	-	+	+	+	+	+	-	+	+	+	-	-	-	-	+	-
PANCREATIC ISLETS ISLET-CELL ADENOMA	+	-	+	+	+	+	+	+	+	+	+	+	+	+	+	+	+	+	+	+	+	+
<b>REPRODUCTIVE SYSTEM</b>																						
MAMMARY GLAND	N	N	N	N	N	N	N	N	N	N	N	N	N	N	N	N	N	N	N	N	N	N
TESTIS	+	+	+	+	+	+	+	+	+	+	+	+	+	+	+	+	+	+	+	+	+	+
PROSTATE	-	+	+	-	+	+	+	+	+	+	+	+	+	+	+	+	+	+	+	+	-	+
<b>NERVOUS SYSTEM</b>																						
BRAIN	+	+	+	+	+	+	+	+	+	+	+	+	+	+	+	+	+	+	+	+	+	+
<b>ALL OTHER SYSTEMS</b>																						
MULTIPLE ORGANS NOS MALIG. LYMPHOMA, HISTIOCYTIC TYPE	N	N	N	N	N	N	N	N	N	N	N	N	N	N	N	N	N	N	N	N	N	X

+: TISSUE EXAMINED MICROSCOPICALLY  
 -: REQUIRED TISSUE NOT EXAMINED MICROSCOPICALLY  
 X: TUMOR INCIDENCE  
 N: NECROPSY, NO AUTOLYSIS, NO MICROSCOPIC EXAMINATION  
 : NO TISSUE INFORMATION SUBMITTED  
 C: NECROPSY, NO HISTOLOGY DUE TO PROTOCOL  
 A: AUTOLYSIS  
 M: ANIMAL MISSING  
 B: NO NECROPSY PERFORMED

TABLE D1. MALE HAMSTERS: TUMOR PATHOLOGY (CONTINUED) CONTROL

ANIMAL NUMBER	1	0	1	1	1	1	1	1	1	1	1	1	1	1	1	1	1	1	1	1	1	1	1	1	1	1	1	1	1	1	1								
WEEKS ON STUDY	0	1	1	2	3	7	8	9	9	9	9	7	6	1	3	4	0	1	0	0	1	0	0	0	0	2	3	3	1	7	2	3	1	0	4	0			
<b>RESPIRATORY SYSTEM</b>																																							
LUNGS AND BRONCHI CORTICAL CARCINOMA, METASTATIC	+	+	+	+	+	+	+	+	+	+	+	+	+	+	+	+	+	+	+	+	+	+	A	+	+	+	+	+	+	+	+	+	+	+	+	+			
TRACHEA	+	+	+	+	+	+	+	+	+	+	+	+	+	+	+	+	+	+	+	+	+	+	A	+	+	+	+	+	+	+	+	+	+	+	+	+	+		
<b>HEMATOPOIETIC SYSTEM</b>																																							
BONE MARROW	+	+	+	+	+	+	+	+	+	+	+	+	+	+	-	+	A	+	+	+	+	+	+	+	+	+	+	+	+	+	+	+	+	+	+	-			
SPLEEN HEMANGIOMA HEMANGIOSARCOMA	+	+	+	+	+	+	+	+	+	+	+	+	+	+	+	+	A	+	+	-	+	+	+	+	+	+	+	+	+	+	+	+	+	+	+	+	+		
LYMPH NODES PLASMA-CELL TUMOR	+	+	+	+	+	+	+	+	+	+	+	+	+	+	+	+	A	+	+	+	+	+	+	+	+	+	+	+	+	+	+	+	+	+	+	+	+	+	
THYMUS	+	+	-	+	+	+	+	-	+	+	+	-	+	+	+	A	-	+	-	+	+	+	+	+	+	+	+	+	+	+	+	+	+	+	+	-	+		
<b>CIRCULATORY SYSTEM</b>																																							
HEART	+	+	+	+	+	+	+	+	+	+	+	+	+	+	+	+	A	+	+	+	+	+	+	+	+	+	+	+	+	+	+	+	+	+	+	+	-		
<b>DIGESTIVE SYSTEM</b>																																							
SALIVARY GLAND	+	+	+	+	+	+	+	+	+	+	+	+	+	+	+	+	A	+	+	+	+	+	+	+	+	+	+	+	+	+	+	+	+	+	+	+	+	+	
LIVER HEMANGIOSARCOMA	+	+	+	+	+	+	+	+	+	+	+	+	+	+	+	+	A	+	+	+	+	+	+	+	+	+	+	+	+	+	+	+	+	+	+	+	+	-	
BILE DUCT	+	+	+	+	+	+	+	+	+	+	+	+	+	+	+	+	A	+	+	+	+	+	+	+	+	+	+	+	+	+	+	+	+	+	+	+	+	-	
GALLBLADDER & COMMON BILE DUCT	N	N	N	N	N	N	N	N	N	N	N	N	N	N	N	N	N	N	N	N	N	N	N	N	N	N	N	N	N	N	N	N	N	N	N	N	N		
PANCREAS	+	-	+	+	+	+	+	+	+	+	+	+	+	+	+	+	A	+	+	+	+	+	+	+	+	+	+	+	+	+	+	+	+	+	+	+	+	+	
ESOPHAGUS	+	+	+	+	+	+	+	+	+	+	+	+	+	+	+	+	A	+	+	+	+	+	+	+	+	+	+	+	+	+	+	+	+	+	+	+	+	+	
STOMACH SQUAMOUS CELL PAPILLOMA	+	+	+	+	+	+	+	+	+	+	+	+	+	+	+	+	A	+	+	+	+	+	+	+	+	+	+	+	+	+	+	+	+	+	+	+	+	+	
SMALL INTESTINE	+	+	+	+	+	+	+	+	+	+	+	+	+	+	+	+	A	+	+	+	+	+	+	+	+	+	+	+	+	+	+	+	+	+	+	+	+	+	
LARGE INTESTINE SARCOMA, NOS, METASTATIC	+	+	-	+	+	+	+	+	+	+	+	+	+	+	+	+	A	+	+	+	+	+	+	+	+	+	+	+	+	+	+	+	+	+	+	+	+	+	
<b>URINARY SYSTEM</b>																																							
KIDNEY ADENOCARCINOMA, NOS	+	+	+	+	+	+	+	+	+	+	+	+	+	+	+	+	A	+	+	+	+	+	+	+	+	+	+	+	+	+	+	+	+	+	+	+	+	-	
URINARY BLADDER	+	+	+	+	+	+	+	+	+	+	+	+	+	+	+	+	A	+	+	+	+	+	+	+	+	+	+	+	+	+	+	+	+	+	+	+	+	+	+
<b>ENDOCRINE SYSTEM</b>																																							
PITUITARY	+	+	+	-	+	+	+	+	+	+	+	+	+	+	+	+	-	A	-	-	+	-	-	+	-	+	-	-	+	-	+	-	+	-	+	-			
ADRENAL CORTICAL ADENOMA CORTICAL CARCINOMA PHEOCHROMOCYTOMA NEURILEIOMA	+	+	+	+	+	+	+	+	+	+	+	+	+	+	+	+	+	+	+	+	+	+	+	+	+	+	+	+	+	+	+	+	+	+	+	+	+	+	
THYROID C-CELL ADENOMA C-CELL CARCINOMA	+	-	+	+	+	+	+	+	+	+	+	+	+	+	+	+	A	-	+	-	+	+	+	+	+	+	+	+	+	+	+	+	+	+	+	+	+	+	
PARATHYROID	-	-	+	+	+	+	+	+	+	+	+	+	+	+	+	+	+	A	-	+	-	-	-	-	-	-	-	-	-	-	-	-	-	-	-	-	-	-	
PANCREATIC ISLETS ISLET-CELL ADENOMA	+	-	+	+	+	+	+	+	+	+	+	+	+	+	+	+	+	A	+	+	+	+	+	+	+	+	+	+	+	+	+	+	+	+	+	+	+	+	+
<b>REPRODUCTIVE SYSTEM</b>																																							
MAMMARY GLAND	N	N	N	N	N	N	N	N	N	N	N	N	N	N	N	N	N	N	N	N	N	N	N	N	N	N	N	N	N	N	N	N	N	N	N	N	N		
TESTIS	+	+	+	+	+	+	+	+	+	+	+	+	+	+	+	+	+	A	+	+	+	+	+	+	+	+	+	+	+	+	+	+	+	+	+	+	+	+	
PROSTATE	+	+	+	+	+	+	+	+	+	+	+	+	+	+	+	+	+	+	+	+	+	+	+	+	+	+	+	+	+	+	+	+	+	+	+	+	+	+	+
<b>NERVOUS SYSTEM</b>																																							
BRAIN	+	+	+	+	+	+	+	+	+	+	+	+	+	+	+	+	+	+	+	+	+	+	+	+	+	+	+	+	+	+	+	+	+	+	+	+	+	+	
<b>ALL OTHER SYSTEMS</b>																																							
MULTIPLE ORGANS NOS MALIG LYMPHOMA, HISTIOCYTIC TYPE	N	N	N	N	N	N	N	N	N	N	N	N	N	N	N	N	N	N	N	N	N	N	N	N	N	N	N	N	N	N	N	N	N	N	N	N	N	N	

+ : TISSUE EXAMINED MICROSCOPICALLY  
- : REQUIRED TISSUE NOT EXAMINED MICROSCOPICALLY  
X : TUMOR INCIDENCE  
N : NECROPSY, NO AUTOLYSIS, NO MICROSCOPIC EXAMINATION

! : NO TISSUE INFORMATION SUBMITTED  
C : NECROPSY, NO HISTOLOGY DUE TO PROTOCOL  
A : AUTOLYSIS  
M : ANIMAL MISSING  
B : NO NECROPSY PERFORMED

**TABLE D1. MALE HAMSTERS: TUMOR PATHOLOGY (CONTINUED) CONTROL**

ANIMAL NUMBER	1	1	2	2	2	2	2	2	2	2	2	2	2	2	2	2	2	2	2	2	2	2	2	2	2	2	2	
WEEKS ON STUDY	6	8	0	2	0	3	1	2	1	3	1	2	2	2	3	3	3	4	4	4	5	5	5	6	6	6	7	7
<b>RESPIRATORY SYSTEM</b>																												
LUNGS AND BRONCHI	+	+	+	+	A	+	+	+	+	+	+	+	+	+	+	+	+	+	+	A	+	+	+	+	+	+	+	+
CORTICAL CARCINOMA, METASTATIC																												
TRACHEA	+	+	+	+	A	+	+	+	+	+	+	+	+	+	+	+	+	+	+	A	+	+	+	+	+	+	+	+
<b>HEMATOPOIETIC SYSTEM</b>																												
BONE MARROW	+	+	+	+	A	+	+	+	+	+	+	+	+	+	+	+	+	+	+	+	+	+	+	+	+	+	-	+
SPLEEN	+	+	+	+	A	+	+	+	+	+	+	+	+	+	+	+	+	+	+	A	+	+	-	+	+	+	+	+
HEMANGIOMA																												
HEMANGIOSARCOMA																X												
LYMPH NODES	+	+	+	+	A	+	+	+	+	+	+	+	+	+	+	+	+	+	+	+	+	+	+	+	+	+	+	+
PLASMA-CELL TUMOR																												
THYMUS	+	-	-	+	A	+	+	+	+	+	+	-	-	+	-	+	A	+	+	-	-	-	-	-	-	-	-	-
<b>CIRCULATORY SYSTEM</b>																												
HEART	+	+	+	+	A	+	+	+	+	+	+	+	+	+	+	+	+	+	A	+	+	+	+	+	+	+	+	+
<b>DIGESTIVE SYSTEM</b>																												
SALIVARY GLAND	+	+	+	+	A	+	+	+	+	+	+	+	+	+	+	+	+	+	+	A	+	+	+	+	+	+	-	+
LIVER	+	+	+	+	A	+	+	+	+	+	+	+	+	+	+	+	+	+	+	+	+	+	+	+	+	+	+	+
HEMANGIOSARCOMA																	X											
BILE DUCT	+	+	+	+	A	+	+	+	+	+	+	+	+	+	+	+	+	+	+	+	+	+	+	+	+	+	+	+
GALLBLADDER & COMMON BILE DUCT	N	N	N	N	A	N	N	N	N	N	N	N	N	N	N	N	N	N	+	N	N	N	N	N	N	N	N	N
PANCREAS	+	+	+	+	A	+	+	+	+	+	+	+	+	+	+	+	+	+	+	+	+	+	+	+	+	+	+	+
ESOPHAGUS	+	+	+	+	A	+	+	+	+	+	+	+	+	+	+	+	+	+	+	+	+	+	+	+	+	+	+	+
STOMACH	+	+	+	+	A	+	+	+	+	+	+	+	+	+	+	+	+	+	+	+	+	+	+	+	+	+	+	+
SQUAMOUS CELL PAPILLOMA																												
SMALL INTESTINE	+	+	+	+	A	+	+	+	+	+	+	+	+	+	+	+	+	+	+	+	+	+	+	+	+	+	+	+
LARGE INTESTINE	+	+	+	+	A	+	+	+	+	+	+	+	+	+	+	+	+	+	+	A	+	+	+	+	+	+	+	+
SARCOMA, NOS, METASTATIC																												
<b>URINARY SYSTEM</b>																												
KIDNEY	+	+	+	+	A	+	+	+	+	+	+	+	+	+	+	+	+	+	+	+	+	+	+	+	+	+	+	+
ADENOCARCINOMA, NOS																												
URINARY BLADDER	+	+	+	+	A	+	+	+	+	+	+	+	+	+	+	+	+	+	A	+	+	+	+	+	+	+	+	+
<b>ENDOCRINE SYSTEM</b>																												
PITUITARY	+	+	+	+	A	+	-	+	-	+	-	+	-	+	-	-	-	A	+	+	-	+	+	+	+	-	+	+
ADRENAL	+	+	+	+	A	+	+	+	+	+	+	+	+	+	+	+	+	+	+	+	+	+	+	+	+	+	+	+
CORTICAL ADENOMA					X																							
CORTICAL CARCINOMA																												
PHOENOCYTOMA																												
NEURILEIOMA					X					X													X					
THYROID	+	+	+	+	A	+	+	-	+	+	+	+	+	+	+	+	+	A	+	+	-	+	+	+	+	-	+	+
C-CELL ADENOMA																												
C-CELL CARCINOMA																												
PARATHYROID	+	+	+	+	A	+	+	-	+	-	-	+	-	+	-	+	A	-	+	-	-	-	-	-	-	-	-	-
PANCREATIC ISLETS	+	+	+	+	A	+	+	+	+	+	+	+	+	+	+	+	+	+	+	+	+	+	+	+	+	+	+	+
ISLET-CELL ADENOMA																												
<b>REPRODUCTIVE SYSTEM</b>																												
MAMMARY GLAND	N	N	N	N	A	N	N	N	N	N	N	N	N	N	N	N	N	N	N	N	N	N	N	N	N	N	N	N
TESTIS	+	+	+	+	A	+	+	+	+	+	+	+	+	+	+	+	+	+	A	+	+	+	+	+	+	+	+	+
PROSTATE	+	+	+	+	A	+	+	-	+	+	+	+	+	+	+	+	+	+	+	+	+	+	+	+	+	+	+	+
<b>NERVOUS SYSTEM</b>																												
BRAIN	+	+	+	+	A	+	+	+	+	+	+	+	+	+	+	+	+	+	A	+	+	+	+	+	+	+	+	+
<b>ALL OTHER SYSTEMS</b>																												
MULTIPLE ORGANS NOS	N	N	N	N	A	N	N	N	N	N	N	N	N	N	N	N	N	N	N	N	N	N	N	N	N	N	N	N
MALIG. LYMPHOMA, HISTIOCYTIC TYPE																												

+: TISSUE EXAMINED MICROSCOPICALLY  
 -: REQUIRED TISSUE NOT EXAMINED MICROSCOPICALLY  
 X: TUMOR INCIDENCE  
 N: NECROPSY, NO AUTOLYSIS, NO MICROSCOPIC EXAMINATION  
 I: NO TISSUE INFORMATION SUBMITTED  
 C: NECROPSY, NO HISTOLOGY DUE TO PROTOCOL  
 A: AUTOLYSIS  
 M: ANIMAL MISSING  
 B: NO NECROPSY PERFORMED



**TABLE D1. MALE HAMSTERS: TUMOR PATHOLOGY (CONTINUED) CONTROL**

ANIMAL NUMBER	273	281	282	283	286	291	292	293	301	302	303	311	312	313	321	322	323	331	332	333	341	342	343	351	352	353	361	362	363	
WEEKS ON STUDY	1	1	0	0	0	1	1	0	0	0	0	0	0	0	0	0	0	0	0	0	0	0	0	0	0	0	0	0	0	0
<b>RESPIRATORY SYSTEM</b>																														
LUNGS AND BRONCHI		+	+	+	+	A	+	+	+	+	+	+	+	+	+	+	+	+	+	+	+	+	+	+	+	+	+	+	+	
CORTICAL CARCINOMA, METASTATIC																														
TRACHEA		+	+	+	+	A	+	+	+	+	+	+	+	+	+	+	+	+	+	+	+	+	+	+	+	+	+	+	+	
<b>HEMATOPOIETIC SYSTEM</b>																														
BONE MARROW		+	+	-	+	A	+	+	+	+	+	+	+	+	+	+	+	+	+	+	+	+	+	+	+	+	+	+	+	
SPLEEN		+	+	+	+	A	+	+	+	+	+	+	+	+	+	+	+	+	+	+	+	+	+	+	+	+	+	+	+	
HEMANGIOMA																														
HEMANGIOSARCOMA																														
LYMPH NODES		+	+	+	+	A	+	+	+	+	+	+	+	+	+	+	+	+	+	+	+	+	+	+	+	+	+	+	+	
PLASMA-CELL TUMOR		X																												
THYMUS		+	-	-	-	A	+	+	+	-	-	-	-	-	+	+	+	+	+	+	+	+	+	+	+	+	+	+	+	
<b>CIRCULATORY SYSTEM</b>																														
HEART		+	+	+	+	A	+	+	+	+	+	+	+	+	+	+	+	+	+	+	+	+	+	+	+	+	+	+	+	
<b>DIGESTIVE SYSTEM</b>																														
SALIVARY GLAND		+	+	+	+	A	+	+	+	+	+	+	+	+	+	+	+	+	+	+	+	+	+	+	+	+	+	+	+	
LIVER		+	+	+	+	A	+	+	+	+	+	+	+	+	+	+	+	+	+	+	+	+	+	+	+	+	+	+	+	
HEMANGIOSARCOMA																														
BILE DUCT		+	+	+	+	A	+	+	+	+	+	+	+	+	+	+	+	+	+	+	+	+	+	+	+	+	+	+	+	
GALLBLADDER & COMMON BILE DUCT		N	N	+	N	A	N	N	N	N	N	N	N	N	N	N	N	N	N	N	N	N	N	N	N	N	N	N	N	
PANCREAS		+	+	+	+	A	+	+	+	+	+	+	+	+	+	+	+	+	+	+	+	+	+	+	+	+	+	+	+	
ESOPHAGUS		+	+	+	+	A	+	+	+	+	+	+	+	+	+	+	+	+	+	+	+	+	+	+	+	+	+	+	+	
STOMACH		+	+	+	+	A	+	+	+	+	+	+	+	+	+	+	+	+	+	+	+	+	+	+	+	+	+	+	+	
SQUAMOUS CELL PAPILLOMA																														
SMALL INTESTINE		+	+	+	+	A	+	+	+	+	+	+	+	+	+	+	+	+	+	+	+	+	+	+	+	+	+	+	+	
LARGE INTESTINE		+	+	+	+	A	+	+	+	+	+	+	+	+	+	+	+	+	+	+	+	+	+	+	+	+	+	+	+	
SARCOMA, NOS, METASTATIC																														
<b>URINARY SYSTEM</b>																														
KIDNEY		+	+	+	+	A	+	+	+	+	+	+	+	+	+	+	+	+	+	+	+	+	+	+	+	+	+	+	+	
ADENOCARCINOMA, NOS		X																												
URINARY BLADDER		+	+	+	+	A	+	+	+	+	+	+	+	+	+	+	+	+	+	+	+	+	+	+	+	+	+	+	+	
<b>ENDOCRINE SYSTEM</b>																														
PITUITARY		+	+	+	-	A	+	+	+	-	+	-	-	+	-	-	+	+	+	+	+	+	+	+	+	+	+	+	+	
ADRENAL		+	+	+	+	A	+	+	+	+	+	+	+	+	+	+	+	+	+	+	+	+	+	+	+	+	+	+	+	
CORTICAL ADENOMA																														
CORTICAL CARCINOMA																														
PHEOCHROMOCYTOMA																														
NEURILEMOMA																														
THYROID		+	+	+	+	A	+	+	+	+	+	+	+	+	+	+	+	+	+	+	+	+	+	+	+	+	+	+	+	
C-CELL ADENOMA																														
C-CELL CARCINOMA																														
PARATHYROID		-	+	+	+	A	+	+	+	-	+	-	+	-	-	+	-	-	+	-	-	+	-	-	+	-	-	+	+	
PANCREATIC ISLETS		+	+	+	+	A	+	+	+	+	+	+	+	+	+	+	+	+	+	+	+	+	+	+	+	+	+	+	+	
ISLET-CELL ADENOMA																														
<b>REPRODUCTIVE SYSTEM</b>																														
MAMMARY GLAND		N	N	N	N	A	N	N	N	N	N	N	N	N	N	N	N	N	N	N	N	N	N	N	N	N	N	N	N	
TESTIS		+	+	+	+	A	+	+	+	+	+	+	+	+	+	+	+	+	+	+	+	+	+	+	+	+	+	+	+	
PROSTATE		+	+	+	+	A	+	+	+	+	+	+	+	+	+	+	+	+	+	+	+	+	+	+	+	+	+	+	+	
<b>NERVOUS SYSTEM</b>																														
BRAIN		+	+	+	+	A	+	+	+	+	+	+	+	+	+	+	+	+	+	+	+	+	+	+	+	+	+	+	+	
<b>ALL OTHER SYSTEMS</b>																														
MULTIPLE ORGANS NOS		N	N	N	N	A	N	N	N	N	N	N	N	N	N	N	N	N	N	N	N	N	N	N	N	N	N	N	N	
MALIG. LYMPHOMA, HISTIOCYTIC TYPE																														

+: TISSUE EXAMINED MICROSCOPICALLY  
 -: REQUIRED TISSUE NOT EXAMINED MICROSCOPICALLY  
 X: TUMOR INCIDENCE  
 N: NECROPSY, NO AUTOLYSIS, NO MICROSCOPIC EXAMINATION  
 1: NO TISSUE INFORMATION SUBMITTED  
 C: NECROPSY; NO HISTOLOGY DUE TO PROTOCOL  
 A: AUTOLYSIS  
 M: ANIMAL MISSING  
 B: NO NECROPSY PERFORMED

**TABLE D1. MALE HAMSTERS: TUMOR PATHOLOGY (CONTINUED) CONTROL**

ANIMAL NUMBER	361	362	363	367	372	373	378	381	383	389	392	393	400	402	403	411	412	413	422	423	424	444	445	446	449	453	454	459	460	461	464	469	473	474	475	TOTAL ISSUES TUMORS
WEEKS ON STUDY	8	6	9	5	2	1	7	2	1	5	2	2	0	2	2	1	2	2	1	1	1	0	0	0	0	0	0	0	0	0	0	0	0	0	0	
<b>RESPIRATORY SYSTEM</b>																																				
LUNGS AND BRONCHI CORTICAL CARCINOMA, METASTATIC	+	+	+	+	+	+	+	+	+	+	+	+	+	+	+	+	+	+	+	+	+	+	+	+	+	+	+	+	+	+	+	+	+	+	120	
TRACHEA	+	+	+	+	+	+	+	+	+	+	+	+	+	+	+	+	+	+	+	+	+	+	+	+	+	+	+	+	+	+	+	+	+	+	120	
<b>HEMATOPOIETIC SYSTEM</b>																																				
BONE MARROW	+	+	+	+	+	+	+	+	+	+	+	+	+	+	+	+	+	+	+	+	+	+	+	+	+	+	+	+	+	+	+	+	+	+	115	
SPLEEN HEMANGIOMA HEMANGIOSARCOMA	+	+	+	+	+	+	+	+	+	+	+	+	+	+	+	+	+	+	+	+	+	+	+	+	+	+	+	+	+	+	+	+	+	+	117	
Lymph nodes PLASMA-CELL TUMOR	+	+	+	+	+	+	+	+	+	+	+	+	+	+	+	+	+	+	+	+	+	+	+	+	+	+	+	+	+	+	+	+	+	+	121	
THYMUS	+	-	+	+	+	+	+	+	+	+	+	+	+	+	+	+	+	+	+	+	+	+	+	+	+	+	+	+	+	+	+	+	+	+	73	
<b>CIRCULATORY SYSTEM</b>																																				
HEART	+	+	+	+	+	+	+	+	+	+	+	+	+	+	+	+	+	+	+	+	+	+	+	+	+	+	+	+	+	+	+	+	+	+	119	
<b>DIGESTIVE SYSTEM</b>																																				
SALIVARY GLAND	+	+	+	+	+	+	+	+	+	+	+	+	+	+	+	+	+	+	+	+	+	+	+	+	+	+	+	+	+	+	+	+	+	+	116	
LIVER HEMANGIOSARCOMA	+	+	+	+	+	+	+	+	+	+	+	+	+	+	+	+	+	+	+	+	+	+	+	+	+	+	+	+	+	+	+	+	+	+	120	
BILE DUCT	+	+	+	+	+	+	+	+	+	+	+	+	+	+	+	+	+	+	+	+	+	+	+	+	+	+	+	+	+	+	+	+	+	+	120	
GALLBLADDER & COMMON BILE DUCT	+	N	N	N	+	N	N	N	N	N	N	N	+	N	A	N	N	N	N	N	+	A	+	N	+	N	+	+	+	+	+	+	+	+	122	
PANCREAS	+	+	+	+	+	+	+	+	+	+	+	+	+	+	+	+	+	+	+	+	+	+	+	+	+	+	+	+	+	+	+	+	+	+	+	114
ESOPHAGUS	+	+	+	+	+	+	+	+	+	+	+	+	+	+	+	+	+	+	+	+	+	+	+	+	+	+	+	+	+	+	+	+	+	+	+	120
STOMACH SQUAMOUS CELL PAPILLOMA	+	+	+	+	+	+	+	+	+	+	+	+	+	+	+	+	+	+	+	+	+	+	+	+	+	+	+	+	+	+	+	+	+	+	+	120
SMALL INTESTINE	+	+	+	+	+	+	+	+	+	+	+	+	+	+	+	+	+	+	+	+	+	+	+	+	+	+	+	+	+	+	+	+	+	+	+	120
LARGE INTESTINE SARCOMA, NOS, METASTATIC	+	+	+	+	+	+	+	+	+	+	+	+	+	+	+	+	+	+	+	+	+	+	+	+	+	+	+	+	+	+	+	+	+	+	+	118
<b>URINARY SYSTEM</b>																																				
KIDNEY ADENOCARCINOMA, NOS	+	+	+	+	+	+	+	+	+	+	+	+	+	+	+	+	+	+	+	+	+	+	+	+	+	+	+	+	+	+	+	+	+	+	+	120
URINARY BLADDER	+	+	+	+	+	+	+	+	+	+	+	+	+	+	+	+	+	+	+	+	+	+	+	+	+	+	+	+	+	+	+	+	+	+	+	118
<b>ENDOCRINE SYSTEM</b>																																				
PITUITARY	-	-	+	-	-	+	-	+	+	+	-	+	+	A	-	-	+	+	+	+	A	+	+	-	-	+	+	+	+	+	+	+	+	+	81	
ADRENAL CORTICAL ADENOMA CORTICAL CARCINOMA PHEOCHROMOCYTOMA NEURILEMOMA	+	+	+	+	+	+	+	+	+	+	+	+	+	+	+	+	+	+	+	+	+	+	+	+	+	+	+	+	+	+	+	+	+	+	+	119
THYROID C-CELL ADENOMA C-CELL CARCINOMA	+	+	+	+	+	+	+	+	+	+	+	+	+	+	+	+	+	+	+	+	+	+	+	+	+	+	+	+	+	+	+	+	+	+	+	106
PARATHYROID	+	-	+	-	-	+	+	+	+	+	+	+	+	+	+	+	+	+	+	+	+	+	+	+	+	+	+	+	+	+	+	+	+	+	+	64
PANCREATIC ISLETS ISLET-CELL ADENOMA	+	+	+	+	+	+	+	+	+	+	+	+	+	+	+	+	+	+	+	+	+	+	+	+	+	+	+	+	+	+	+	+	+	+	+	114
<b>REPRODUCTIVE SYSTEM</b>																																				
MAMMARY GLAND	N	N	N	N	N	N	N	N	N	N	N	N	N	N	N	N	N	N	N	N	N	N	N	N	N	N	N	N	N	N	N	N	N	N	122	
TESTIS	+	+	+	+	+	+	+	+	+	+	+	+	+	+	+	+	+	+	+	+	+	+	+	+	+	+	+	+	+	+	+	+	+	+	+	119
PROSTATE	+	+	+	+	+	+	+	+	+	+	+	+	+	+	+	+	+	+	+	+	+	+	+	+	+	+	+	+	+	+	+	+	+	+	+	107
<b>NERVOUS SYSTEM</b>																																				
BRAIN	+	+	+	+	+	+	+	+	+	+	+	+	+	+	+	+	+	+	+	+	+	+	+	+	+	+	+	+	+	+	+	+	+	+	+	118
<b>ALL OTHER SYSTEMS</b>																																				
MULTIPLE ORGANS NOS MALIG. LYMPHOMA, HISTIOCYTIC TYPE	N	N	N	N	N	N	N	N	N	N	N	N	N	N	N	N	N	N	N	N	N	N	N	N	N	N	N	N	N	N	N	N	N	N	122	

+: TISSUE EXAMINED MICROSCOPICALLY  
 -: REQUIRED TISSUE NOT EXAMINED MICROSCOPICALLY  
 X: TUMOR INCIDENCE  
 N: NECROPSY, NO AUTOLYSIS, NO MICROSCOPIC EXAMINATION  
 1: NO TISSUE INFORMATION SUBMITTED  
 C: NECROPSY, NO HISTOLOGY DUE TO PROTOCOL  
 A: AUTOLYSIS  
 M: ANIMAL MISSING  
 B: NO NECROPSY PERFORMED

TABLE D1.

INDIVIDUAL ANIMAL TUMOR PATHOLOGY OF MALE HAMSTERS ADMINISTERED AMOSITE ASBESTOS IN THE DIET

AMOSITE

ANIMAL NUMBER	0	1	2	3	4	5	6	7	8	9	10	11	12	13	14	15	16	17	18	19	20	21	22	23	24	25	26	27	28	29	30	
WEEKS ON STUDY	1	2	3	4	5	6	7	8	9	10	11	12	13	14	15	16	17	18	19	20	21	22	23	24	25	26	27	28	29	30		
<b>RESPIRATORY SYSTEM</b>																																
LUNGS AND BRONCHI OSTEOSARCOMA, METASTATIC	+	+	+	+	+	+	+	A	+	+	+	+	+	+	+	+	+	+	+	+	+	+	+	+	+	+	+	+	+	+	+	+
TRACHEA	+	+	+	+	+	+	+	A	+	+	+	+	+	+	+	+	+	+	+	+	+	+	+	+	+	+	+	+	+	+	+	+
<b>HEMATOPOIETIC SYSTEM</b>																																
BONE MARROW	+	+	+	+	+	+	+	A	+	+	+	+	+	+	+	+	+	+	+	+	+	+	+	+	+	+	+	+	+	+	+	+
SPLEEN	+	+	+	+	+	+	+	A	+	+	+	+	+	+	+	+	+	+	+	+	+	+	+	+	+	+	+	+	+	+	+	+
LYMPH NODES HEMANGIOSARCOMA	+	+	+	+	+	+	+	A	+	+	+	+	+	+	+	+	+	+	+	+	+	+	+	+	+	+	+	+	+	+	+	+
THYMUS	-	+	+	-	-	+	-	A	-	-	+	-	-	-	+	+	+	+	+	+	+	+	+	+	+	+	+	+	+	+	+	
<b>CIRCULATORY SYSTEM</b>																																
HEART	+	+	+	+	+	+	+	A	+	+	+	+	+	+	+	+	+	+	+	+	+	+	+	+	+	+	+	+	+	+	+	+
<b>DIGESTIVE SYSTEM</b>																																
SALIVARY GLAND	+	+	+	+	+	+	+	A	+	+	-	+	+	+	+	+	+	+	+	+	+	+	+	+	+	+	+	+	+	+	+	+
LIVER	+	+	+	+	+	+	+	A	+	+	+	+	+	+	+	+	+	+	+	+	+	+	+	+	+	+	+	+	+	+	+	+
BILE DUCT	+	+	+	+	+	+	+	A	+	+	+	+	+	+	+	+	+	+	+	+	+	+	+	+	+	+	+	+	+	+	+	+
GALLBLADDER & COMMON BILE DUCT	N	N	N	N	N	+	+	N	N	A	N	N	N	N	N	N	N	N	N	N	N	N	N	N	N	N	N	N	N	N	N	N
PANCREAS	+	+	+	+	+	+	+	A	+	+	+	+	+	+	+	+	+	+	+	+	+	+	+	+	+	+	+	+	+	+	+	+
ESOPHAGUS	+	+	+	+	+	+	+	A	+	+	+	+	+	+	+	+	+	+	+	+	+	+	+	+	+	+	+	+	+	+	+	+
STOMACH SQUAMOUS CELL PAPILLOMA	+	+	+	+	+	+	+	A	+	+	+	+	+	+	+	+	+	+	+	+	+	+	+	+	+	+	+	+	+	+	+	+
SMALL INTESTINE	+	+	+	+	+	+	+	A	+	+	+	+	+	+	+	+	+	+	+	+	+	+	+	+	+	+	+	+	+	+	+	+
LARGE INTESTINE PAPILLARY ADENOMA	+	+	+	+	+	+	+	A	+	+	+	+	+	+	+	+	+	+	+	+	+	+	+	+	+	+	+	+	+	+	+	+
RECTUM ADENOMATOUS POLYP, NOS	+	+	+	+	+	+	+	A	+	+	+	+	+	+	+	+	+	+	+	+	+	+	+	+	+	+	+	+	+	+	+	N
<b>URINARY SYSTEM</b>																																
KIDNEY TRANSITIONAL-CELL CARCINOMA ADENOCARCINOMA, NOS	+	+	+	+	+	+	+	A	+	+	+	+	+	+	+	+	+	+	+	+	+	+	+	+	+	+	+	+	+	+	+	+
URINARY BLADDER	+	+	+	+	-	+	+	A	+	+	+	+	+	+	+	+	+	+	+	+	+	+	+	+	+	+	+	+	+	+	+	+
<b>ENDOCRINE SYSTEM</b>																																
PITUITARY	+	+	A	-	-	+	+	-	A	+	+	+	+	+	+	+	+	+	+	+	+	+	+	+	+	+	+	+	+	+	+	
ADRENAL CORTICAL ADENOMA CORTICAL CARCINOMA PHEOCHROMOCYTOMA NEUROBLASTOMA NEURILEMOMA	+	+	+	+	+	+	+	A	+	+	+	+	+	+	+	+	+	+	+	+	+	+	+	+	+	+	+	+	+	+	+	+
THYROID ADENOMA, NOS C-CELL ADENOMA C-CELL CARCINOMA	+	+	+	+	+	+	+	A	+	+	+	+	+	+	+	+	+	+	+	+	+	+	+	+	+	+	+	+	+	+	+	+
PARATHYROID ADENOMA, NOS	+	-	A	-	+	-	+	+	A	-	+	-	-	-	+	+	+	+	+	+	+	+	+	+	+	+	+	+	+	+	+	
PANCREATIC ISLETS ISLET-CELL ADENOMA	+	+	+	+	+	+	+	A	+	+	+	+	+	+	+	+	+	+	+	+	+	+	+	+	+	+	+	+	+	+	+	+
<b>REPRODUCTIVE SYSTEM</b>																																
MAMMARY GLAND	N	N	N	N	N	N	N	N	A	N	N	N	N	N	N	N	N	N	N	N	N	N	N	N	N	N	N	N	N	N	N	N
TESTIS	+	+	+	+	-	+	+	+	A	+	+	+	+	+	+	+	+	+	+	+	+	+	+	+	+	+	+	+	+	+	+	+
PROSTATE	+	+	A	+	-	+	+	+	A	+	+	+	+	+	+	+	+	+	+	+	+	+	+	+	+	+	+	+	+	+	+	+
<b>NERVOUS SYSTEM</b>																																
BRAIN	+	+	+	+	+	+	+	A	+	+	+	+	+	+	+	+	+	+	+	+	+	+	+	+	+	+	+	+	+	+	+	+
<b>MUSCULOSKELETAL SYSTEM</b>																																
BONE OSTEOSARCOMA	N	N	N	N	N	N	N	N	A	N	N	N	N	N	N	N	N	N	N	N	N	N	N	N	N	N	N	N	N	N	N	
JOINT HEMANGIOMA	N	N	N	N	N	N	N	N	A	N	N	N	N	N	N	N	N	N	N	N	N	N	N	N	N	N	N	N	N	N	N	N
MUSCLE FIBROSARCOMA	N	N	N	N	N	N	N	N	A	N	N	N	N	N	N	N	N	N	N	N	N	N	N	N	N	N	N	N	N	N	N	N
<b>ALL OTHER SYSTEMS</b>																																
MULTIPLE ORGANS NOS MALIG. LYMPHOMA, LYMPHOCYTIC TYPE MALIG. LYMPHOMA, HISTIOCYTIC TYPE	N	N	N	N	N	N	N	N	A	N	N	N	N	N	N	N	N	N	N	N	N	N	N	N	N	N	N	N	N	N	N	N

+ : TISSUE EXAMINED MICROSCOPICALLY  
 - : REQUIRED TISSUE NOT EXAMINED MICROSCOPICALLY  
 X : TUMOR INCIDENCE  
 N : NECROPSY, NO AUTOLYSIS, NO MICROSCOPIC EXAMINATION  
 : NO TISSUE INFORMATION SUBMITTED  
 C : NECROPSY, NO HISTOLOGY DUE TO PROTOCOL  
 A : AUTOLYSIS  
 M : ANIMAL MISSING  
 S : NO NECROPSY PERFORMED

**TABLE D1. MALE HAMSTERS: TUMOR PATHOLOGY (CONTINUED) AMOSITE**

ANIMAL NUMBER	WEEKS ON STUDY																												
	0	1	2	3	4	5	6	7	8	9	10	11	12	13	14	15	16	17	18	19	20	21	22	23	24	25	26	27	28
<b>RESPIRATORY SYSTEM</b>																													
LUNGS AND BRONCHI	+	+	+	+	+	+	+	+	+	+	+	+	+	+	+	+	+	+	+	+	+	+	+	+	+	+	+	+	+
OSTEOSARCOMA, METASTATIC																													
TRACHEA	+	+	+	+	+	+	+	+	+	+	+	+	+	+	+	+	+	+	+	+	+	+	+	+	+	+	+	+	+
<b>HEMATOPOIETIC SYSTEM</b>																													
BONE MARROW	+	+	+	+	+	+	+	+	+	+	+	+	+	+	+	+	+	+	+	+	+	+	+	+	+	+	+	+	+
SPLEEN	+	+	-	+	+	+	+	+	+	+	+	+	+	+	+	+	+	+	+	+	+	+	+	+	+	+	+	+	+
LYMPH NODES	+	+	+	+	+	+	+	+	+	+	+	+	+	+	+	+	+	+	+	+	+	+	+	+	+	+	+	+	+
HEMANGIOSARCOMA																													
THYMUS	+	+	+	+	-	+	-	+	+	+	+	-	-	+	-	-	-	-	-	+	+	-	+	+	-	+	+	-	
<b>CIRCULATORY SYSTEM</b>																													
HEART	+	+	+	+	+	+	+	+	+	+	+	+	+	+	+	+	+	+	+	+	+	+	+	+	+	+	+	+	+
<b>DIGESTIVE SYSTEM</b>																													
SALIVARY GLAND	+	+	+	+	+	+	+	+	+	+	+	+	+	+	+	+	+	+	+	+	+	+	+	+	+	+	+	+	+
LIVER	+	+	+	+	+	+	+	+	+	+	+	+	+	+	+	+	+	+	+	+	+	+	+	+	+	+	+	+	+
BILE DUCT	+	+	+	+	+	+	+	+	+	+	+	+	+	+	+	+	+	+	+	+	+	+	+	+	+	+	+	+	+
GALLBLADDER & COMMON BILE DUCT	N	N	N	N	N	N	N	N	N	N	N	N	N	N	N	N	N	N	N	N	N	N	N	N	N	N	N	N	N
PANCREAS	+	+	-	+	+	+	+	+	+	+	+	+	+	+	+	+	+	+	+	+	+	+	+	+	+	+	+	+	+
ESOPHAGUS	+	+	+	+	+	+	+	+	+	+	+	+	+	+	+	+	+	+	+	+	+	+	+	+	+	+	+	+	+
STOMACH	+	+	+	+	+	+	+	+	+	+	+	+	+	+	+	+	+	+	+	+	+	+	+	+	+	+	+	+	+
SQUAMOUS CELL PAPILLOMA																													
SMALL INTESTINE	+	+	+	+	+	+	+	+	+	+	+	+	+	+	+	+	+	+	+	+	+	+	+	+	+	+	+	+	+
LARGE INTESTINE	+	+	+	+	+	+	+	+	+	+	+	+	+	+	+	+	+	+	+	+	+	+	+	+	+	+	+	+	+
PAPILLARY ADENOMA																													
RECTUM	+	+	+	+	+	+	+	+	+	+	+	+	+	+	+	+	+	+	+	+	+	+	+	+	+	+	+	+	+
ADENOMATOUS POLYP, NOS																													
<b>URINARY SYSTEM</b>																													
KIDNEY	+	+	+	+	+	+	+	+	+	+	+	+	+	+	+	+	+	+	+	+	+	+	+	+	+	+	+	+	+
TRANSITIONAL-CELL CARCINOMA																													
ADENOCARCINOMA, NOS																													
URINARY BLADDER	+	+	+	+	+	+	+	+	+	+	+	+	+	+	+	+	+	+	+	+	+	+	+	+	+	+	+	+	+
<b>ENDOCRINE SYSTEM</b>																													
PITUITARY	+	+	+	+	+	+	+	+	+	+	+	+	+	+	+	+	+	+	+	+	+	+	+	+	+	+	+	+	+
ADRENAL	+	+	+	+	+	+	+	+	+	+	+	+	+	+	+	+	+	+	+	+	+	+	+	+	+	+	+	+	+
CORTICAL ADENOMA																													
CORTICAL CARCINOMA																													
PHEDCHROMOCYTOMA																													
NEUROBLASTOMA	X																												
NEURILEMOMA					X																								
THYROID	+	+	+	+	+	+	+	+	+	+	+	+	+	+	+	+	+	+	+	+	+	+	+	+	+	+	+	+	+
ADENOMA, NOS																													
C-CELL ADENOMA																													
C-CELL CARCINOMA																													X
PARATHYROID	-	+	-	-	-	-	-	+	-	+	+	-	+	+	-	+	+	-	+	+	-	+	+	+	+	+	+	+	+
ADENOMA, NOS																													
PANCREATIC ISLETS	+	+	-	-	+	+	+	+	+	+	+	+	+	+	+	+	+	+	+	+	+	+	+	+	+	+	+	+	+
ISLET-CELL ADENOMA								X																					
<b>REPRODUCTIVE SYSTEM</b>																													
MAMMARY GLAND	N	N	N	N	N	N	N	N	N	N	N	N	N	N	N	N	N	N	N	N	N	N	N	N	N	N	N	N	N
TESTIS	+	+	+	+	+	+	+	+	+	+	+	+	+	+	+	+	+	+	+	+	+	+	+	+	+	+	+	+	+
PROSTATE	+	+	+	+	+	+	+	+	+	+	+	+	+	+	+	+	+	+	+	+	+	+	+	+	+	+	+	+	+
<b>NERVOUS SYSTEM</b>																													
BRAIN	+	+	+	+	+	+	+	+	+	+	+	+	+	+	+	+	+	+	+	+	+	+	+	+	+	+	+	+	+
<b>MUSCULOSKELETAL SYSTEM</b>																													
BONE	N	N	N	N	N	N	N	N	N	N	N	N	N	N	N	N	N	N	N	N	N	N	N	N	N	N	N	N	N
OSTEOSARCOMA																													
JOINT	N	N	N	N	N	N	N	N	N	N	N	N	N	N	N	N	N	N	N	N	N	N	N	N	N	N	N	N	N
HEMANGIOMA																													
MUSCLE	N	N	N	N	N	N	N	N	N	N	N	N	N	N	N	N	N	N	N	N	N	N	N	N	N	N	N	N	N
FIBROSARCOMA																													
<b>ALL OTHER SYSTEMS</b>																													
MULTIPLE ORGANS NOS	N	N	N	N	N	N	N	N	N	N	N	N	N	N	N	N	N	N	N	N	N	N	N	N	N	N	N	N	N
MALIG. LYMPHOMA, LYMPHOCYTIC TYPE																													
MALIG. LYMPHOMA, HISTIOCYTIC TYPE																													X

+: TISSUE EXAMINED MICROSCOPICALLY  
 -: REQUIRED TISSUE NOT EXAMINED MICROSCOPICALLY  
 X: TUMOR INCIDENCE  
 N: NECROPSY, NO AUTOLYSIS, NO MICROSCOPIC EXAMINATION  
 : NO TISSUE INFORMATION SUBMITTED  
 C: NECROPSY, NO HISTOLOGY DUE TO PROTOCOL  
 A: AUTOLYSIS  
 M: ANIMAL MISSING  
 B: NO NECROPSY PERFORMED

TABLE D1. MALE HAMSTERS: TUMOR PATHOLOGY (CONTINUED) AMOSITE

ANIMAL NUMBER	1	1	1	1	2	2	2	2	2	2	2	2	2	2	2	2	2	2	2	2	2	2	2	2	2	2	2	2	2	2	2	2	2	2	2	2	2					
WEEKS ON STUDY	8	8	9	9	0	0	0	0	0	0	1	1	1	1	1	1	1	1	1	1	1	1	1	1	1	1	1	1	1	1	1	1	1	1	1	1	1	1	1			
<b>RESPIRATORY SYSTEM</b>																																										
LUNGS AND BRONCHI OSTEOSARCOMA, METASTATIC	+	+	+	+	+	+	+	+	+	+	+	+	+	+	+	+	+	+	+	+	+	+	+	+	+	+	+	+	+	+	+	+	+	+	+	+	+	+	+	+		
TRACHEA	+	+	+	+	+	+	+	+	+	+	+	+	+	+	+	+	+	+	+	+	+	+	+	+	+	+	+	+	+	+	+	+	+	+	+	+	+	+	+	+	+	
<b>HEMATOPOIETIC SYSTEM</b>																																										
BONE MARROW	+	+	+	+	+	+	+	+	+	+	+	+	+	+	+	+	+	+	+	+	+	+	+	+	+	+	+	+	+	+	+	+	+	+	+	+	+	+	+	+	+	
SPLEEN	+	+	+	+	+	+	+	+	+	+	+	+	+	+	+	+	+	+	+	+	+	+	+	+	+	+	+	+	+	+	+	+	+	+	+	+	+	+	+	+	+	
LYMPH NODES HEMANGIOSARCOMA	+	+	+	+	+	+	+	+	+	+	+	+	+	+	+	+	+	+	+	+	+	+	+	+	+	+	+	+	+	+	+	+	+	+	+	+	+	+	+	+	+	
THYMUS	+	-	+	+	+	-	-	+	+	-	+	+	-	-	+	-	-	-	-	+	-	-	-	-	-	-	-	-	-	-	-	-	-	-	-	-	-	-	-	-		
<b>CIRCULATORY SYSTEM</b>																																										
HEART	+	+	+	+	+	+	+	+	+	+	+	+	+	+	+	+	+	+	+	+	+	+	+	+	+	+	+	+	+	+	+	+	+	+	+	+	+	+	+	+	+	
<b>DIGESTIVE SYSTEM</b>																																										
SALIVARY GLAND	+	+	+	+	+	+	+	+	+	+	+	+	+	+	+	+	+	+	+	+	+	+	+	+	+	+	+	+	+	+	+	+	+	+	+	+	+	+	+	+	+	
LIVER	+	+	+	+	+	+	+	+	+	+	+	+	+	+	+	+	+	+	+	+	+	+	+	+	+	+	+	+	+	+	+	+	+	+	+	+	+	+	+	+	+	
BILE DUCT	+	+	+	+	+	+	+	+	+	+	+	+	+	+	+	+	+	+	+	+	+	+	+	+	+	+	+	+	+	+	+	+	+	+	+	+	+	+	+	+	+	
GALLBLADDER & COMMON BILE DUCT	+	N	N	N	+	+	N	N	N	N	N	N	N	N	N	N	N	N	N	N	N	N	N	N	N	N	N	N	N	N	N	N	N	N	N	N	N	N	N	N		
PANCREAS	-	+	+	+	+	+	+	+	+	+	+	+	+	+	+	+	+	+	+	+	+	+	+	+	+	+	+	+	+	+	+	+	+	+	+	+	+	+	+	+	+	
ESOPHAGUS	+	+	+	+	+	+	+	+	+	+	+	+	+	+	+	+	+	+	+	+	+	+	+	+	+	+	+	+	+	+	+	+	+	+	+	+	+	+	+	+	+	
STOMACH SQUAMOUS CELL PAPILLOMA	+	+	+	+	+	+	+	+	+	+	+	+	+	+	+	+	+	+	+	+	+	+	+	+	+	+	+	+	+	+	+	+	+	+	+	+	+	+	+	+	+	
SMALL INTESTINE	-	+	+	+	+	+	+	+	+	+	+	+	+	+	+	+	+	+	+	+	+	+	+	+	+	+	+	+	+	+	+	+	+	+	+	+	+	+	+	+	+	
LARGE INTESTINE PAPILLARY ADENOMA	-	+	+	+	+	+	+	+	+	+	+	+	+	+	+	+	+	+	+	+	+	+	+	+	+	+	+	+	+	+	+	+	+	+	+	+	+	+	+	+	+	
RECTUM ADENOMATOUS POLYP, NOS	N	+	+	+	+	+	+	+	+	+	+	+	+	+	+	+	+	+	+	+	+	+	+	+	+	+	+	+	+	+	+	+	+	+	+	+	+	+	+	+		
<b>URINARY SYSTEM</b>																																										
KIDNEY TRANSITIONAL-CELL CARCINOMA ADENOCARCINOMA, NOS	+	+	+	+	+	+	+	+	+	+	+	+	+	+	+	+	+	+	+	+	+	+	+	+	+	+	+	+	+	+	+	+	+	+	+	+	+	+	+	+	+	
URINARY BLADDER	+	+	+	+	+	+	+	+	+	+	+	+	+	+	+	+	+	+	+	+	+	+	+	+	+	+	+	+	+	+	+	+	+	+	+	+	+	+	+	+	+	
<b>ENDOCRINE SYSTEM</b>																																										
PITUITARY	+	+	+	+	+	+	-	+	+	+	+	+	+	+	+	+	+	+	+	-	+	-	-	-	-	-	-	-	-	-	-	-	-	-	-	-	-	-	-	-		
ADRENAL CORTICAL ADENOMA CORTICAL CARCINOMA PHEOCHROMOCYTOMA NEUROBLASTOMA NEURILEMOMA	+	+	+	+	+	+	+	+	+	+	+	+	+	+	+	+	+	+	+	+	+	+	+	+	+	+	+	+	+	+	+	+	+	+	+	+	+	+	+	+	+	+
THYROID ADENOMA, NOS C-CELL ADENOMA C-CELL CARCINOMA	+	-	+	+	+	-	+	+	+	+	+	+	+	+	+	+	+	+	+	-	+	+	+	+	+	+	+	+	+	+	+	+	+	+	+	+	+	+	+	+	+	
PARATHYROID ADENOMA, NOS	+	-	+	+	+	-	+	+	+	-	+	+	+	+	+	+	+	+	+	+	+	+	+	+	+	+	+	+	+	+	+	+	+	+	+	+	+	+	+	+	+	
PANCREATIC ISLETS ISLET-CELL ADENOMA	-	+	+	+	+	+	+	+	+	+	+	+	+	+	+	+	+	+	+	+	+	+	+	+	+	+	+	+	+	+	+	+	+	+	+	+	+	+	+	+	+	
<b>REPRODUCTIVE SYSTEM</b>																																										
MAMMARY GLAND	N	N	N	N	N	N	N	N	N	N	N	N	N	N	N	N	N	N	N	N	N	N	N	N	N	N	N	N	N	N	N	N	N	N	N	N	N	N	N	N		
TESTIS	+	+	+	+	+	+	+	+	+	+	+	+	+	+	+	+	+	+	+	+	+	+	+	+	+	+	+	+	+	+	+	+	+	+	+	+	+	+	+	+	+	
PROSTATE	+	+	+	+	+	+	+	+	+	+	+	+	+	+	+	+	+	+	+	+	+	+	+	+	+	+	+	+	+	+	+	+	+	+	+	+	+	+	+	+	+	
<b>NERVOUS SYSTEM</b>																																										
BRAIN	+	-	+	+	+	+	+	+	+	+	+	+	+	+	+	+	+	+	+	+	+	+	+	+	+	+	+	+	+	+	+	+	+	+	+	+	+	+	+	+	+	
<b>MUSCULOSKELETAL SYSTEM</b>																																										
BONE OSTEOSARCOMA	N	N	N	N	N	N	N	N	N	N	N	N	N	N	N	N	N	N	N	N	N	N	N	N	N	N	N	N	N	N	N	N	N	N	N	N	N	N	N	N		
JOINT HEMANGIOMA	N	N	N	N	N	N	N	N	N	N	N	N	N	N	N	N	N	N	N	N	N	N	N	N	N	N	N	N	N	N	N	N	N	N	N	N	N	N	N	N	N	
MUSCLE FIBROSARCOMA	N	+	N	N	N	N	N	N	N	N	N	N	N	N	N	N	N	N	N	N	N	N	N	N	N	N	N	N	N	N	N	N	N	N	N	N	N	N	N	N	N	
<b>ALL OTHER SYSTEMS</b>																																										
MULTIPLE ORGANS NOS MALIG. LYMPHOMA, LYMPHOBLASTIC TYPE MALIG. LYMPHOMA, HISTIOCYTIC TYPE	N	N	N	N	N	N	N	N	N	N	N	N	N	N	N	N	N	N	N	N	N	N	N	N	N	N	N	N	N	N	N	N	N	N	N	N	N	N	N	N		

+: TISSUE EXAMINED MICROSCOPICALLY  
 -: REQUIRED TISSUE NOT EXAMINED MICROSCOPICALLY  
 X: TUMOR INCIDENCE  
 N: NECROPSY, NO AUTOLYSIS, NO MICROSCOPIC EXAMINATION  
 I: NO TISSUE INFORMATION SUBMITTED  
 C: NECROPSY, NO HISTOLOGY DUE TO PROTOCOL  
 A: AUTOLYSIS  
 M: ANIMAL MISSING  
 B: NO NECROPSY PERFORMED



**TABLE D1. MALE HAMSTERS: TUMOR PATHOLOGY (CONTINUED) AMOSITE**

ANIMAL NUMBER	353	366	366	373	377	377	381	382	383	391	392	393	400	402	403	411	412	413	422	422	423	431	432	433
WEEKS ON STUDY	0	0	1	0	1	0	1	1	0	0	0	1	0	0	0	0	1	0	0	0	0	0	0	0
<b>RESPIRATORY SYSTEM</b>																								
LUNGS AND BRONCHI OSTEOSARCOMA, METASTATIC	+	+	+	+	+	+	+	+	+	+	+	+	+	+	+	+	+	+	+	+	+	+	+	+
TRACHEA	+	+	+	+	+	+	+	+	+	+	+	+	+	+	+	+	+	+	+	+	+	+	+	+
<b>HEMATOPOIETIC SYSTEM</b>																								
BOONE MARROW	+	+	+	+	+	+	+	+	+	+	+	+	+	+	+	+	+	+	+	+	+	+	+	+
SPLEEN	+	+	+	+	+	+	+	+	+	+	+	+	+	+	+	+	+	+	+	+	+	+	+	+
LYMPH NODES HEMANGIOSARCOMA	+	+	+	+	+	+	+	+	+	+	+	+	+	+	+	+	+	+	+	+	+	+	+	+
THYMUS	+	-	-	-	A	-	-	-	-	+	+	+	-	-	-	-	-	-	-	-	-	-	-	-
<b>CIRCULATORY SYSTEM</b>																								
HEART	+	+	+	+	+	+	+	+	+	+	+	+	+	+	+	+	+	+	+	+	+	+	+	+
<b>DIGESTIVE SYSTEM</b>																								
SALIVARY GLAND	-	+	+	+	+	+	+	+	+	+	+	+	+	+	+	+	+	+	+	+	+	+	+	+
LIVER	+	+	+	+	+	+	+	+	+	+	+	+	+	+	+	+	+	+	+	+	+	+	+	+
BILE DUCT	+	+	+	+	+	+	+	+	+	+	+	+	+	+	+	+	+	+	+	+	+	+	+	+
GALLBLADDER & COMMON BILE DUCT	N	N	N	N	N	N	N	N	N	N	N	N	N	N	N	N	N	N	N	N	N	N	N	N
PANCREAS	+	+	+	+	+	+	+	+	+	+	+	+	+	+	+	+	+	+	+	+	+	+	+	+
ESOPHAGUS	+	+	+	+	+	+	+	+	+	+	+	+	+	+	+	+	+	+	+	+	+	+	+	+
STOMACH SQUAMOUS CELL PAPILLOMA	+	+	+	+	+	+	+	+	+	+	+	+	+	+	+	+	+	+	+	+	+	+	+	+
SMALL INTESTINE	+	+	+	+	+	+	+	+	+	+	+	+	+	+	+	+	+	+	+	+	+	+	+	+
LARGE INTESTINE	+	+	+	+	+	+	+	+	+	+	+	+	+	+	+	+	+	+	+	+	+	+	+	+
PAPILLARY ADENOMA	+	+	+	+	+	+	+	+	+	+	+	+	+	+	+	+	+	+	+	+	+	+	+	+
RECTUM ADENOMATOUS POLYP, NOS	+	+	+	+	+	+	+	+	+	+	+	+	+	+	+	+	+	+	+	+	+	+	+	+
<b>URINARY SYSTEM</b>																								
KIDNEY TRANSITIONAL-CELL CARCINOMA ADENOCARCINOMA, NOS	+	+	+	+	+	+	+	+	+	+	+	+	+	+	+	+	+	+	+	+	+	+	+	+
URINARY BLADDER	+	+	+	+	+	+	+	+	+	+	+	+	+	+	+	+	+	+	+	+	+	+	+	+
<b>ENDOCRINE SYSTEM</b>																								
PITUITARY	-	-	+	+	-	A	+	-	+	+	+	+	+	+	+	+	-	-	+	+	+	+	+	+
ADRENAL CORTICAL ADENOMA CORTICAL CARCINOMA PHEOCHROMOCYTOMA NEUROBLASTOMA NEURILEMOMA	+	+	+	+	+	+	+	+	+	+	+	+	+	+	+	+	+	+	+	+	+	+	+	+
THYROID ADENOMA, NOS C-CELL ADENOMA C-CELL CARCINOMA	-	+	+	+	+	+	+	+	+	+	+	+	+	+	+	+	+	+	+	+	+	+	+	-
PARATHYROID ADENOMA, NOS	-	+	+	+	+	+	-	-	+	+	+	+	+	+	+	+	+	+	+	+	+	+	-	-
PANCREATIC ISLETS ISLET-CELL ADENOMA	+	-	+	+	+	+	+	+	+	+	+	+	+	+	+	+	+	+	+	+	+	+	+	+
<b>REPRODUCTIVE SYSTEM</b>																								
MAMMARY GLAND	N	N	N	N	N	N	N	N	N	N	N	N	N	N	N	N	N	N	N	N	N	N	N	N
TESTIS	+	+	+	+	+	+	+	+	+	+	+	+	+	+	+	+	+	+	+	+	+	+	+	+
PROSTATE	+	+	+	+	+	+	+	+	+	+	+	+	+	+	+	+	+	+	+	+	+	+	+	+
<b>NERVOUS SYSTEM</b>																								
BRAIN	-	-	+	+	+	A	+	+	+	+	+	+	+	+	+	+	+	+	+	+	+	+	+	+
<b>MUSCULOSKELETAL SYSTEM</b>																								
BONE OSTEOSARCOMA	N	N	N	N	N	N	N	N	N	N	N	N	N	N	N	N	N	N	N	N	N	N	N	N
JOINT HEMANGIOMA	N	N	N	N	N	N	N	N	N	N	N	N	N	N	N	N	N	N	N	N	N	N	N	N
MUSCLE FIBROSARCOMA	N	N	N	N	N	N	N	N	N	N	N	N	N	N	N	N	N	N	N	N	N	N	N	N
<b>ALL OTHER SYSTEMS</b>																								
MULTIPLE ORGANS NOS MALIG. LYMPHOMA, LYMPHOCYTIC TYPE MALIG. LYMPHOMA, HISTIOCYTIC TYPE	N	N	N	N	N	N	N	N	N	N	N	N	N	N	N	N	N	N	N	N	N	N	N	N

+: TISSUE EXAMINED MICROSCOPICALLY  
 -: REQUIRED TISSUE NOT EXAMINED MICROSCOPICALLY  
 X: TUMOR INCIDENCE  
 N: NECROPSY, NO AUTOLYSIS, NO MICROSCOPIC EXAMINATION  
 : NO TISSUE INFORMATION SUBMITTED  
 C: NECROPSY, NO HISTOLOGY DUE TO PROTOCOL  
 A: AUTOLYSIS  
 M: ANIMAL MISSING  
 B: NO NECROPSY PERFORMED

**TABLE D1. MALE HAMSTERS: TUMOR PATHOLOGY (CONTINUED) AMOSITE**

ANIMAL NUMBER	4	4	4	4	4	4	4	4	4	4	4	4	4	4	4	4	4	4	4	5	5	5	5	5	5	5	5	
WEEKS ON STUDY	1	2	3	4	5	6	7	8	9	10	11	12	13	14	15	16	17	18	19	20	21	22	23	24	25	26		
<b>RESPIRATORY SYSTEM</b>																												
LUNGS AND BRONCHI OSTEOSARCOMA, METASTATIC	+	+	+	+	+	+	+	+	+	+	+	+	+	+	+	+	+	+	+	+	+	+	+	+	+	+	+	
TRACHEA	+	+	+	+	+	+	+	+	+	+	+	+	+	+	+	+	+	+	+	+	+	+	+	+	+	+	+	
<b>HEMATOPOIETIC SYSTEM</b>																												
BONE MARROW	+	+	+	+	+	+	+	+	+	+	+	+	+	+	+	+	+	+	+	+	+	+	+	+	+	+	+	
SPLEEN	+	+	+	+	+	+	+	+	+	+	+	+	+	+	+	+	+	+	+	+	+	+	+	+	+	+	+	
LYMPH NODES HEMANGIOSARCOMA	+	+	+	+	+	+	+	+	+	+	+	+	+	+	+	+	+	+	+	+	+	+	+	+	+	+	+	
THYMUS	-	-	+	+	+	+	+	+	+	+	+	+	+	+	+	+	+	+	+	+	+	+	+	+	+	+	+	
<b>CIRCULATORY SYSTEM</b>																												
HEART	+	+	+	+	+	+	+	+	+	+	+	+	+	+	+	+	+	+	+	+	+	+	+	+	+	+	+	
<b>DIGESTIVE SYSTEM</b>																												
SALIVARY GLAND	+	+	+	+	+	+	+	+	+	+	+	+	+	+	+	+	+	+	+	+	+	+	+	+	+	+	+	
LIVER	+	+	+	+	+	+	+	+	+	+	+	+	+	+	+	+	+	+	+	+	+	+	+	+	+	+	+	
BILE DUCT	+	+	+	+	+	+	+	+	+	+	+	+	+	+	+	+	+	+	+	+	+	+	+	+	+	+	+	
GALLBLADDER & COMMON BILE DUCT	+	N	N	N	N	+	N	N	+	N	N	N	N	N	+	N	N	N	N	N	+	N	N	N	N	N	N	
PANCREAS	+	+	+	+	+	+	+	+	+	+	+	+	+	+	+	+	+	+	+	+	+	+	+	+	+	+	+	
ESOPHAGUS	+	+	+	+	+	+	+	+	+	+	+	+	+	+	+	+	+	+	+	+	+	+	+	+	+	+	+	
STOMACH SQUAMOUS CELL PAPILLOMA	+	+	+	+	+	+	+	+	+	+	+	+	+	+	+	+	+	+	+	+	+	+	+	+	+	+	+	
SMALL INTESTINE	+	+	+	+	+	+	+	+	+	+	+	+	+	+	+	+	+	+	+	+	+	+	+	+	+	+	+	
LARGE INTESTINE PAPILLARY ADENOMA	+	+	+	+	+	+	+	+	+	+	+	+	+	+	+	+	+	+	+	+	+	+	+	+	+	+	+	
RECTUM ADENOMATOUS POLYP, NOS	+	+	+	+	+	+	+	+	+	+	+	+	+	+	+	+	+	+	+	+	+	+	+	+	+	+	+	
<b>URINARY SYSTEM</b>																												
KIDNEY TRANSITIONAL-CELL CARCINOMA ADENOCARCINOMA, NOS	+	+	+	+	+	+	+	+	+	+	+	+	+	+	+	+	+	+	+	+	+	+	+	+	+	+	+	
URINARY BLADDER	+	+	+	+	+	+	+	+	+	+	+	+	+	+	+	+	+	+	+	+	+	+	+	+	+	+	+	
<b>ENDOCRINE SYSTEM</b>																												
PITUITARY	+	+	-	-	+	+	+	+	-	+	-	-	-	-	+	-	+	-	-	+	+	+	-	+	+	-	+	
ADRENAL CORTICAL ADENOMA CORTICAL CARCINOMA PHEOCHROMOCYTOMA NEUROBLASTOMA NEURILEMOMA	+	+	+	+	+	+	+	+	+	+	+	+	+	+	+	+	+	+	+	+	+	+	+	+	+	+	+	
THYROID ADENOMA, NOS C-CELL ADENOMA C-CELL CARCINOMA	+	+	+	+	+	+	+	+	-	+	+	+	+	+	+	+	+	+	+	+	+	+	+	+	+	+	+	
PARATHYROID ADENOMA, NOS	+	+	+	-	-	+	+	-	-	-	-	+	+	+	-	+	+	+	+	+	+	+	+	+	+	+	+	
PANCREATIC ISLETS ISLET-CELL ADENOMA	+	+	+	+	+	+	+	+	+	+	+	+	+	+	+	+	+	+	+	+	+	+	+	+	+	+	+	
<b>REPRODUCTIVE SYSTEM</b>																												
MAMMARY GLAND	N	N	N	N	N	N	N	N	N	N	N	N	N	N	N	N	N	N	N	N	N	N	N	N	N	N	N	
TESTIS	+	+	+	+	+	+	+	+	+	+	+	+	+	+	+	+	+	+	+	+	+	+	+	+	+	+	+	
PROSTATE	+	+	+	+	+	+	+	+	+	+	+	+	+	+	+	+	+	+	+	+	+	+	+	+	+	+	+	
<b>NERVOUS SYSTEM</b>																												
BRAIN	+	+	+	-	+	+	+	+	+	+	+	+	+	+	+	+	+	+	+	+	+	+	+	+	+	+	+	
<b>MUSCULOSKELETAL SYSTEM</b>																												
BONE OSTEOSARCOMA	N	N	N	N	N	N	N	N	N	N	N	N	N	N	N	N	N	N	N	N	N	N	N	N	N	N	N	
JOINT HEMANGIOMA	N	N	N	N	N	N	N	N	N	N	N	N	N	N	N	N	N	N	N	N	N	N	N	N	N	N	N	
MUSCLE FIBROSARCOMA	N	N	N	N	N	N	N	N	N	N	N	N	N	N	N	N	N	N	N	N	N	N	N	N	N	N	N	
<b>ALL OTHER SYSTEMS</b>																												
MULTIPLE ORGANS NOS MALIGNANT LYMPHOMA, LYMPHOCYTIC TYPE MALIGNANT LYMPHOMA, HISTIOCYTIC TYPE	N	N	N	N	N	N	N	N	N	N	N	N	N	N	N	N	N	N	N	N	N	N	N	N	N	N	N	

+: TISSUE EXAMINED MICROSCOPICALLY  
 -: REQUIRED TISSUE NOT EXAMINED MICROSCOPICALLY  
 X: TUMOR INCIDENCE  
 N: NECROPSY, NO AUTOLYSIS, NO MICROSCOPIC EXAMINATION  
 I: NO TISSUE INFORMATION SUBMITTED  
 C: NECROPSY, NO HISTOLOGY DUE TO PROTOCOL  
 A: AUTOLYSIS  
 M: ANIMAL MISSING  
 B: NO NECROPSY PERFORMED



**TABLE D1. MALE HAMSTERS: TUMOR PATHOLOGY (CONTINUED) AMOSITE**

ANIMAL NUMBER	5233	5411	5433	5433	5433	5433	5433	5433	5433	5433	5433	5433	5433	5433	5433	5433	5433	5433	5433	5433	5433	5433	5433	5433	5433	5433	5433	5433	5433	5433	5433	5433	5433	5433	5433	5433	5433	
WEEKS ON STUDY	0	1	6	6	10	10	10	10	10	10	10	10	10	10	10	10	10	10	10	10	10	10	10	10	10	10	10	10	10	10	10	10	10	10	10	10	10	
<b>RESPIRATORY SYSTEM</b>																																						
LUNGS AND BRONCHI	+	+	+	+	+	+	+	+	+	+	+	+	+	+	+	+	+	+	+	+	+	+	+	+	+	+	+	+	+	+	+	+	+	+	+	+		
OSTEOSARCOMA, METASTATIC																																						
TRACHEA	+	+	+	+	+	+	+	+	+	+	+	+	+	+	+	+	+	+	+	+	+	+	+	+	+	+	+	+	+	+	+	+	+	+	+	+	+	
<b>HEMATOPOIETIC SYSTEM</b>																																						
BONE MARROW	+	+	+	+	+	+	+	+	+	+	+	+	+	+	+	+	+	+	+	+	+	+	+	+	+	+	+	+	+	+	+	+	+	+	+	+	+	
SPLEEN	+	+	+	+	+	+	+	+	+	+	+	+	+	+	+	+	+	+	+	+	+	+	+	+	+	+	+	+	+	+	+	+	+	+	+	+	+	+
LYMPH NODES	+	+	+	+	+	+	+	+	+	+	+	+	+	+	+	+	+	+	+	+	+	+	+	+	+	+	+	+	+	+	+	+	+	+	+	+	+	+
HEMANGIOSARCOMA																																						
THYMUS	-	+	+	+	+	-	+	-	-	-	-	-	-	-	-	-	-	-	-	-	-	-	-	-	-	-	-	-	-	-	-	-	-	-	-	-	-	
<b>CIRCULATORY SYSTEM</b>																																						
HEART	+	+	+	+	+	+	+	+	+	+	+	+	+	+	+	+	+	+	+	+	+	+	+	+	+	+	+	+	+	+	+	+	+	+	+	+	+	+
<b>DIGESTIVE SYSTEM</b>																																						
SALIVARY GLAND	+	+	+	+	+	+	+	+	+	+	+	+	+	+	+	+	+	+	+	+	+	+	+	+	+	+	+	+	+	+	+	+	+	+	+	+	+	+
LIVER	+	+	+	+	+	+	+	+	+	+	+	+	+	+	+	+	+	+	+	+	+	+	+	+	+	+	+	+	+	+	+	+	+	+	+	+	+	+
BILE DUCT	+	+	+	+	+	+	+	+	+	+	+	+	+	+	+	+	+	+	+	+	+	+	+	+	+	+	+	+	+	+	+	+	+	+	+	+	+	+
GALLBLADDER & COMMON BILE DUCT	N	N	+	N	N	N	N	N	N	N	N	N	N	N	N	N	N	N	N	N	N	N	N	N	N	N	N	N	N	N	N	N	N	N	N	N	N	
PANCREAS	-	+	+	+	+	+	+	+	+	+	+	+	+	+	+	+	+	+	+	+	+	+	+	+	+	+	+	+	+	+	+	+	+	+	+	+	+	+
ESOPHAGUS	+	+	+	+	+	+	+	+	+	+	+	+	+	+	+	+	+	+	+	+	+	+	+	+	+	+	+	+	+	+	+	+	+	+	+	+	+	+
STOMACH	+	+	+	+	+	+	+	+	+	+	+	+	+	+	+	+	+	+	+	+	+	+	+	+	+	+	+	+	+	+	+	+	+	+	+	+	+	+
SQUAMOUS CELL PAPILLOMA																																						
SMALL INTESTINE	+	+	+	+	+	+	+	+	+	+	+	+	+	+	+	+	+	+	+	+	+	+	+	+	+	+	+	+	+	+	+	+	+	+	+	+	+	
LARGE INTESTINE	+	+	+	+	+	+	+	+	+	+	+	+	+	+	+	+	+	+	+	+	+	+	+	+	+	+	+	+	+	+	+	+	+	+	+	+	+	+
PAPILLARY ADENOMA																																						
RECTUM	+	+	+	+	+	+	+	+	+	+	+	+	+	+	+	+	+	+	+	+	+	+	+	+	+	+	+	+	+	+	+	+	+	+	+	+	+	
ADENOMATOUS POLYP, NOS																																						
<b>URINARY SYSTEM</b>																																						
KIDNEY	+	+	+	+	+	+	+	+	+	+	+	+	+	+	+	+	+	+	+	+	+	+	+	+	+	+	+	+	+	+	+	+	+	+	+	+	+	
TRANSITIONAL-CELL CARCINOMA																																						
ADENOCARCINOMA, NOS																																						
URINARY BLADDER	+	+	+	+	+	+	+	+	+	+	+	+	+	+	+	+	+	+	+	+	+	+	+	+	+	+	+	+	+	+	+	+	+	+	+	+	+	+
<b>ENDOCRINE SYSTEM</b>																																						
PITUITARY	-	-	+	+	+	+	+	+	+	+	+	+	+	+	+	+	+	+	+	+	+	+	+	+	+	+	+	+	+	+	+	+	+	+	+	+	+	
ADRENAL	+	+	+	+	+	+	+	+	+	+	+	+	+	+	+	+	+	+	+	+	+	+	+	+	+	+	+	+	+	+	+	+	+	+	+	+	+	+
CORTICAL ADENOMA																																						
CORTICAL CARCINOMA																																						
PHEOCHROMOCYTOMA																																						
NEUROBLASTOMA																																						
NEURILEMOMA																																						
THYROID	+	+	-	+	+	+	+	+	+	+	+	+	+	+	+	+	+	+	+	+	+	+	+	+	+	+	+	+	+	+	+	+	+	+	+	+	+	
ADENOMA, NOS																																						
C-CELL ADENOMA																																						
C-CELL CARCINOMA																																						
PARATHYROID	+	+	-	+	-	-	-	-	-	-	-	-	-	-	-	-	-	-	-	-	-	-	-	-	-	-	-	-	-	-	-	-	-	-	-	-		
ADENOMA, NOS																																						
PANCREATIC ISLETS	-	+	+	+	+	+	+	+	+	+	+	+	+	+	+	+	+	+	+	+	+	+	+	+	+	+	+	+	+	+	+	+	+	+	+	+	+	
ISLET-CELL ADENOMA	X																																					
<b>REPRODUCTIVE SYSTEM</b>																																						
MAMMARY GLAND	N	N	N	N	N	N	N	N	N	N	N	N	N	N	N	N	N	N	N	N	N	N	N	N	N	N	N	N	N	N	N	N	N	N	N	N		
TESTIS	+	+	+	+	+	+	+	+	+	+	+	+	+	+	+	+	+	+	+	+	+	+	+	+	+	+	+	+	+	+	+	+	+	+	+	+	+	
PROSTATE	+	+	+	+	+	+	+	+	+	+	+	+	+	+	+	+	+	+	+	+	+	+	+	+	+	+	+	+	+	+	+	+	+	+	+	+	+	+
<b>NERVOUS SYSTEM</b>																																						
BRAIN	+	+	+	+	+	+	+	+	+	+	+	+	+	+	+	+	+	+	+	+	+	+	+	+	+	+	+	+	+	+	+	+	+	+	+	+	+	
<b>MUSCULOSKELETAL SYSTEM</b>																																						
BONE	N	N	N	N	N	N	N	N	N	N	N	N	N	N	N	N	N	N	N	N	N	N	N	N	N	N	N	N	N	N	N	N	N	N	N	N		
OSTEOSARCOMA																																						
JOINT	N	N	N	N	N	N	N	N	N	N	N	N	N	N	N	N	N	N	N	N	N	N	N	N	N	N	N	N	N	N	N	N	N	N	N	N	N	
HEMANGIOMA																																						
MUSCLE	N	N	N	N	N	N	N	N	N	N	N	N	N	N	N	N	N	N	N	N	N	N	N	N	N	N	N	N	N	N	N	N	N	N	N	N	N	
FIBROSARCOMA																																						
<b>ALL OTHER SYSTEMS</b>																																						
MULTIPLE ORGANS NOS	N	N	N	N	N	N	N	N	N	N	N	N	N	N	N	N	N	N	N	N	N	N	N	N	N	N	N	N	N	N	N	N	N	N	N	N		
MALIG. LYMPHOMA, LYMPHOCYTIC TYPE																																						
MALIG. LYMPHOMA, HISTIOCYTIC TYPE																																						

+: TISSUE EXAMINED MICROSCOPICALLY  
 -: REQUIRED TISSUE NOT EXAMINED MICROSCOPICALLY  
 X: TUMOR INCIDENCE  
 N: NECROPSY, NO AUTOLYSIS, NO MICROSCOPIC EXAMINATION

I: NO TISSUE INFORMATION SUBMITTED  
 G: NECROPSY, NO HISTOLOGY DUE TO PROTOCOL  
 A: AUTOLYSIS  
 M: ANIMAL MISSING  
 B: NO NECROPSY PERFORMED

**TABLE D1. MALE HAMSTERS: TUMOR PATHOLOGY (CONTINUED) AMOSITE**

ANIMAL NUMBER	61	61	61	62	62	62	63	63	63	64	64	64	65	65	65	66	66	66	67	67	67	68	68	68	69	69
WEEKS ON STUDY	0	0	0	0	0	0	1	1	1	1	1	1	1	1	1	1	1	1	1	1	1	1	1	1	1	1
<b>RESPIRATORY SYSTEM</b>																										
LUNGS AND BRONCHI OSTEOSARCOMA, METASTATIC	+	+	+	+	+	+	+	+	+	+	+	+	+	+	+	+	+	+	+	+	+	+	+	+	A	+
TRACHEA	+	+	+	+	+	+	+	+	+	+	+	+	+	+	+	+	+	+	+	+	+	+	+	+	A	+
<b>HEMATOPOIETIC SYSTEM</b>																										
BONE MARROW	+	+	+	+	+	+	+	+	+	+	+	+	+	+	+	+	+	+	+	+	+	+	+	+	A	+
SPLEEN	+	+	+	+	+	+	+	+	+	+	+	+	+	+	+	+	+	+	+	+	+	+	+	+	A	+
LYMPH NODES HEMANGIOSARCOMA	+	+	+	+	+	+	+	+	+	+	+	+	+	+	+	+	+	+	+	+	+	+	+	+	A	+
THYMUS	+	+	+	+	+	+	-	-	+	-	-	-	-	-	+	+	+	-	-	-	-	-	-	A	-	-
<b>CIRCULATORY SYSTEM</b>																										
HEART	+	+	+	+	+	+	+	+	+	+	+	+	+	+	+	+	+	+	+	+	+	+	+	+	A	+
<b>DIGESTIVE SYSTEM</b>																										
SALIVARY GLAND	+	+	+	+	+	+	+	+	+	+	+	+	+	+	+	+	+	+	+	+	+	+	+	+	A	+
LIVER	+	+	+	+	+	+	+	+	+	+	+	+	+	+	+	+	+	+	+	+	+	+	+	+	A	+
BILE DUCT	+	+	+	+	+	+	+	+	+	+	+	+	+	+	+	+	+	+	+	+	+	+	+	+	A	+
GALLBLADDER & COMMON BILE DUCT	N	N	N	+	N	N	N	N	+	N	N	+	N	N	+	N	N	N	N	N	N	N	N	N	N	N
PANCREAS	+	+	+	+	+	+	+	+	+	+	+	+	+	+	+	+	+	+	+	+	+	+	+	+	A	+
ESOPHAGUS	+	+	+	+	+	+	+	+	+	+	+	+	+	+	+	+	+	+	+	+	+	+	+	+	A	+
STOMACH SQUAMOUS CELL PAPILLOMA	+	+	+	+	+	+	+	+	+	+	+	+	+	+	+	+	+	+	+	+	+	+	+	+	A	+
SMALL INTESTINE	+	+	+	+	+	+	+	+	+	+	+	+	+	+	+	+	+	+	+	+	+	+	+	+	A	+
LARGE INTESTINE PAPILLARY ADENOMA	+	+	+	+	+	+	+	+	+	+	+	+	+	+	+	+	+	+	+	+	+	+	+	+	A	+
RECTUM ADENOMATOUS POLYP, NOS	+	+	+	+	+	+	+	+	+	+	+	+	+	+	+	+	+	+	+	+	+	+	+	+	A	+
<b>URINARY SYSTEM</b>																										
KIDNEY TRANSITIONAL-CELL CARCINOMA ADENOCARCINOMA, NOS	+	+	+	+	+	+	+	+	+	+	+	+	+	+	+	+	+	+	+	+	+	+	+	+	A	+
URINARY BLADDER	+	+	+	+	+	+	+	+	+	+	+	+	+	+	+	+	+	+	+	+	+	+	+	+	A	+
<b>ENDOCRINE SYSTEM</b>																										
PITUITARY	+	+	+	+	+	+	+	-	+	+	+	-	-	+	+	+	+	+	+	+	+	+	+	+	A	+
ADRENAL CORTICAL ADENOMA CORTICAL CARCINOMA PHEOCHROMOCYTOMA NEUROBLASTOMA NEURILEHOMA	+	+	+	+	+	+	+	+	+	+	+	+	+	+	+	+	+	+	+	+	+	+	+	+	A	+
THYROID ADENOMA, NOS C-CELL ADENOMA C-CELL CARCINOMA	+	+	-	+	-	+	+	+	+	+	+	+	+	+	+	+	+	+	+	+	+	+	+	+	A	+
PARATHYROID ADENOMA, NOS	+	+	-	+	-	+	+	+	+	+	+	+	+	+	+	+	+	+	+	+	+	+	+	+	A	-
PANCREATIC ISLETS ISLET-CELL ADENOMA	+	+	+	+	+	+	+	+	+	+	+	+	+	+	+	+	+	+	+	+	+	+	+	+	A	+
<b>REPRODUCTIVE SYSTEM</b>																										
MAMMARY GLAND	N	N	N	N	N	N	N	N	N	N	N	N	N	N	N	N	N	N	N	N	N	N	N	N	N	N
TESTIS	+	+	+	+	+	+	+	+	+	+	+	+	+	+	+	+	+	+	+	+	+	+	+	+	A	+
PROSTATE	+	+	+	+	+	+	+	+	+	+	+	+	+	+	+	+	+	+	+	+	+	+	+	+	A	+
<b>NERVOUS SYSTEM</b>																										
BRAIN	+	+	+	+	+	+	+	+	+	+	+	+	+	+	+	+	+	+	+	+	+	+	+	+	A	+
<b>MUSCULOSKELETAL SYSTEM</b>																										
BONE OSTEOSARCOMA	N	N	N	N	N	N	N	N	N	N	N	N	N	N	N	N	N	N	N	N	N	N	N	N	N	N
JOINT HEMANGIOMA	N	N	N	N	N	N	N	N	N	N	N	N	N	N	N	N	N	N	N	N	N	N	N	N	N	N
MUSCLE FIBROSARCOMA	N	N	N	N	N	N	N	N	N	N	N	N	N	N	N	N	N	N	N	N	N	N	N	N	N	N
<b>ALL OTHER SYSTEMS</b>																										
MULTIPLE ORGANS NOS MALIG. LYMPHOMA, LYMPHOCYTIC TYPE MALIG. LYMPHOMA, HISTIOCYTIC TYPE	N	N	N	N	N	N	N	N	N	N	N	N	N	N	N	N	N	N	N	N	N	N	N	N	N	N

+: TISSUE EXAMINED MICROSCOPICALLY  
 -: REQUIRED TISSUE NOT EXAMINED MICROSCOPICALLY  
 X: TUMOR INCIDENCE  
 N: NECROPSY, NO AUTOLYSIS, NO MICROSCOPIC EXAMINATION  
 I: NO TISSUE INFORMATION SUBMITTED  
 C: NECROPSY, NO HISTOLOGY DUE TO PROTOCOL  
 A: AUTOLYSIS  
 M: ANIMAL MISSING  
 B: NO NECROPSY PERFORMED

**TABLE D1. MALE HAMSTERS: TUMOR PATHOLOGY (CONTINUED) AMOSITE**

ANIMAL NUMBER	6	6	7	7	7	7	7	7	7	7	7	7	7	7	7	7	7	7	7	7	7	7	7	7	7	7	7	7	7	7	7	7	7	7	7	7	7					
WEEKS ON STUDY	0	0	0	0	0	0	0	0	0	0	0	0	0	0	0	0	0	0	0	0	0	0	0	0	0	0	0	0	0	0	0	0	0	0	0	0	0	0				
<b>RESPIRATORY SYSTEM</b>																																										
LUNGS AND BRONCHI OSTEOSARCOMA, METASTATIC	+	+	+	+	+	+	+	+	+	+	+	+	+	+	+	+	+	+	+	+	+	+	+	+	+	+	+	+	+	+	+	+	+	+	+	+	+	+				
TRACHEA	+	+	+	+	+	+	+	+	+	+	+	+	+	+	+	+	+	+	+	+	+	+	+	+	+	+	+	+	+	+	+	+	+	+	+	+	+	+	+			
<b>HEMATOPOIETIC SYSTEM</b>																																										
BONE MARROW	+	+	+	+	+	+	+	+	+	+	+	+	+	+	+	+	+	+	+	+	+	+	+	+	+	+	+	+	+	+	+	+	+	+	+	+	+	+	+			
SPLEEN	+	+	+	+	+	+	+	+	+	+	+	+	+	+	+	+	+	+	+	+	+	+	+	+	+	+	+	+	+	+	+	+	+	+	+	+	+	+	+	+		
LYMPH NODES HEMANGIOSARCOMA	+	+	+	+	+	+	+	+	+	+	+	+	+	+	+	+	+	+	+	+	+	+	+	+	+	+	+	+	+	+	+	+	+	+	+	+	+	+	+	+		
THYMUS	-	+	+	+	+	+	-	+	+	+	+	+	-	+	+	-	-	-	-	-	-	-	-	-	-	-	-	-	-	-	-	-	-	-	-	-	-	-	-			
<b>CIRCULATORY SYSTEM</b>																																										
HEART	+	+	+	+	+	+	+	+	+	+	+	+	+	+	+	+	+	+	+	+	+	+	+	+	+	+	+	+	+	+	+	+	+	+	+	+	+	+	+	+		
<b>DIGESTIVE SYSTEM</b>																																										
SALIVARY GLAND	+	+	+	+	+	+	+	+	+	+	+	+	+	+	+	+	+	+	+	+	+	+	+	+	+	+	+	+	+	+	+	+	+	+	+	+	+	+	+	+		
LIVER	+	+	+	+	+	+	+	+	+	+	+	+	+	+	+	+	+	+	+	+	+	+	+	+	+	+	+	+	+	+	+	+	+	+	+	+	+	+	+	+		
BILE DUCT	+	+	+	+	+	+	+	+	+	+	+	+	+	+	+	+	+	+	+	+	+	+	+	+	+	+	+	+	+	+	+	+	+	+	+	+	+	+	+	+	+	
GALLBLADDER & COMMON BILE DUCT	N	N	N	N	N	N	N	N	N	N	N	N	N	N	N	N	N	N	N	N	N	N	N	N	N	N	N	N	N	N	N	N	N	N	N	N	N	N	N	N		
PANCREAS	+	+	+	+	+	+	+	+	+	+	+	+	+	+	+	+	+	+	+	+	+	+	+	+	+	+	+	+	+	+	+	+	+	+	+	+	+	+	+	+	+	
ESOPHAGUS	+	+	+	+	+	+	+	+	+	+	+	+	+	+	+	+	+	+	+	+	+	+	+	+	+	+	+	+	+	+	+	+	+	+	+	+	+	+	+	+	+	
STOMACH SQUAMOUS CELL PAPILLOMA	+	+	+	+	+	+	+	+	+	+	+	+	+	+	+	+	+	+	+	+	+	+	+	+	+	+	+	+	+	+	+	+	+	+	+	+	+	+	+	+	+	
SMALL INTESTINE	+	+	+	+	+	+	+	+	+	+	+	+	+	+	+	+	+	+	+	+	+	+	+	+	+	+	+	+	+	+	+	+	+	+	+	+	+	+	+	+	+	
LARGE INTESTINE PAPILLARY ADENOMA	+	+	+	+	+	+	+	+	+	+	+	+	+	+	+	+	+	+	+	+	+	+	+	+	+	+	+	+	+	+	+	+	+	+	+	+	+	+	+	+	+	
RECTUM ADENOMATOUS POLYP, NOS	+	+	+	+	+	+	+	+	+	+	+	+	+	+	+	+	+	+	+	+	+	+	+	+	+	+	+	+	+	+	+	+	+	+	+	+	+	+	+	+	+	
<b>URINARY SYSTEM</b>																																										
KIDNEY TRANSITIONAL-CELL CARCINOMA ADENOCARCINOMA, NOS	+	+	+	+	+	+	+	+	+	+	+	+	+	+	+	+	+	+	+	+	+	+	+	+	+	+	+	+	+	+	+	+	+	+	+	+	+	+	+	+	+	
URINARY BLADDER	+	+	+	+	+	+	+	+	+	+	+	+	+	+	+	+	+	+	+	+	+	+	+	+	+	+	+	+	+	+	+	+	+	+	+	+	+	+	+	+	+	
<b>ENDOCRINE SYSTEM</b>																																										
PITUITARY	-	+	+	+	+	+	-	+	+	+	+	+	+	+	+	+	+	+	+	+	+	+	+	+	+	+	+	+	+	+	+	+	+	+	+	+	+	+	+	+	+	
ADRENAL CORTICAL ADENOMA CORTICAL CARCINOMA PHEOCHROMOCYTOMA NEUROBLASTOMA NEURILEMOMA	+	+	+	+	+	+	+	+	+	+	+	+	+	+	+	+	+	+	+	+	+	+	+	+	+	+	+	+	+	+	+	+	+	+	+	+	+	+	+	+	+	+
THYROID ADENOMA, NOS C-CELL ADENOMA C-CELL CARCINOMA	+	+	+	+	+	+	+	+	+	+	+	+	+	+	+	+	+	+	+	+	+	+	+	+	+	+	+	+	+	+	+	+	+	+	+	+	+	+	+	+	+	+
PARATHYROID ADENOMA, NOS	+	+	-	+	+	+	+	+	+	+	+	+	+	+	+	+	+	+	+	+	+	+	+	+	+	+	+	+	+	+	+	+	+	+	+	+	+	+	+	+	+	+
PANCREATIC ISLETS ISLET-CELL ADENOMA	+	+	+	+	+	+	+	+	+	+	+	+	+	+	+	+	+	+	+	+	+	+	+	+	+	+	+	+	+	+	+	+	+	+	+	+	+	+	+	+	+	+
<b>REPRODUCTIVE SYSTEM</b>																																										
MAMMARY GLAND	+	N	N	N	N	N	N	N	N	N	N	N	N	N	N	N	N	N	N	N	N	N	N	N	N	N	N	N	N	N	N	N	N	N	N	N	N	N	N	N		
TESTIS	+	+	+	+	+	+	+	+	+	+	+	+	+	+	+	+	+	+	+	+	+	+	+	+	+	+	+	+	+	+	+	+	+	+	+	+	+	+	+	+	+	+
PROSTATE	+	+	+	+	+	+	+	+	+	+	+	+	+	+	+	+	+	+	+	+	+	+	+	+	+	+	+	+	+	+	+	+	+	+	+	+	+	+	+	+	+	+
<b>NERVOUS SYSTEM</b>																																										
BRAIN	+	+	+	+	+	+	+	+	+	+	+	+	+	+	+	+	+	+	+	+	+	+	+	+	+	+	+	+	+	+	+	+	+	+	+	+	+	+	+	+	+	
<b>MUSCULOSKELETAL SYSTEM</b>																																										
BONE OSTEOSARCOMA	N	N	N	N	N	N	N	N	N	N	N	N	N	N	N	N	N	N	N	N	N	N	N	N	N	N	N	N	N	N	N	N	N	N	N	N	N	N	N	N	N	
JOINT HEMANGIOMA	N	N	N	N	N	N	N	N	N	N	N	N	N	N	N	N	N	N	N	N	N	N	N	N	N	N	N	N	N	N	N	N	N	N	N	N	N	N	N	N	N	N
MUSCLE FIBROSARCOMA	N	N	N	N	N	N	N	N	N	N	N	N	N	N	N	N	N	N	N	N	N	N	N	N	N	N	N	N	N	N	N	N	N	N	N	N	N	N	N	N	N	N
<b>ALL OTHER SYSTEMS</b>																																										
MULTIPLE ORGANS NOS	N	N	N	N	N	N	N	N	N	N	N	N	N	N	N	N	N	N	N	N	N	N	N	N	N	N	N	N	N	N	N	N	N	N	N	N	N	N	N	N	N	
MALIG. LYMPHOMA, LYMPHOCYTIC TYPE	X																																									
MALIG. LYMPHOMA, HISTIOCYTIC TYPE																																										

+: TISSUE EXAMINED MICROSCOPICALLY  
 -: REQUIRED TISSUE NOT EXAMINED MICROSCOPICALLY  
 X: TUMOR INCIDENCE  
 N: NECROPSY, NO AUTOLYSIS, NO MICROSCOPIC EXAMINATION  
 I: NO TISSUE INFORMATION SUBMITTED  
 C: NECROPSY, NO HISTOLOGY DUE TO PROTOCOL  
 A: AUTOLYSIS  
 M: ANIMAL MISSING  
 B: NO NECROPSY PERFORMED



TABLE D2.

INDIVIDUAL ANIMAL TUMOR PATHOLOGY OF FEMALE HAMSTERS ADMINISTERED AMOSITE ASBESTOS IN THE DIET

CONTROL

ANIMAL NUMBER	0	1	2	3	4	5	6	7	8	9	10	11	12	13	14	15	16	17	18	19	20	
WEEKS ON STUDY	6	6	6	6	6	6	6	6	6	6	6	6	6	6	6	6	6	6	6	6	6	
RESPIRATORY SYSTEM																						
LUNGS AND BRONCHI	+	+	+	+	+	+	+	A	+	+	+	+	+	+	+	+	+	+	A	+	+	+
TRACHEA	+	+	+	+	+	+	+	A	+	+	+	+	+	+	+	+	+	+	A	-	+	+
HEMATOPOIETIC SYSTEM																						
BONE MARROW	-	+	+	+	+	+	+	A	+	+	+	+	+	+	+	+	+	+	A	+	+	+
SPLEEN	+	+	+	+	+	+	+	A	+	+	+	+	+	+	+	+	+	+	A	+	+	+
LYMPH NODES	+	+	+	+	+	+	+	A	+	+	+	+	+	+	+	+	+	+	A	+	+	+
THYMUS	+	+	+	+	+	+	+	A	-	-	+	+	+	+	+	+	+	+	A	+	+	+
CIRCULATORY SYSTEM																						
HEART	+	+	+	+	+	+	+	A	+	+	-	+	+	+	+	+	+	+	A	+	+	+
DIGESTIVE SYSTEM																						
SALIVARY GLAND	+	+	+	+	+	+	+	A	+	+	-	+	+	+	+	+	+	+	A	+	+	+
LIVER	+	+	+	+	+	+	+	A	+	+	+	+	+	+	+	+	+	+	A	+	+	+
BILE DUCT	+	+	+	+	+	+	+	A	+	+	+	+	+	+	+	+	+	+	A	+	+	+
GALLBLADDER & COMMON BILE DUCT	+	N	N	N	N	N	N	N	A	+	+	N	N	+	N	N	+	N	N	A	N	N
PANCREAS	+	+	+	+	+	+	+	A	+	+	+	+	+	+	+	+	+	+	A	+	+	+
ESOPHAGUS	+	+	+	+	+	+	+	A	+	+	+	+	+	+	+	+	+	+	A	+	+	+
STOMACH	+	+	+	+	+	+	+	A	+	+	+	+	+	+	+	+	+	+	A	+	+	+
SMALL INTESTINE	+	+	+	+	+	+	+	A	+	+	+	+	+	+	+	+	+	+	A	+	+	+
LARGE INTESTINE	+	+	+	+	+	+	+	A	+	+	+	+	+	+	+	+	+	+	A	+	+	+
RECTUM	+	+	+	+	+	+	+	A	+	+	+	+	+	+	+	+	+	+	A	+	+	+
ADENOMA, NOS	+	+	+	+	+	+	+	A	+	+	+	+	+	+	N	+	+	+	A	+	+	+
URINARY SYSTEM																						
KIDNEY	+	+	+	+	+	+	+	A	+	+	+	+	+	+	+	+	+	+	A	+	+	+
URINARY BLADDER	+	+	+	+	+	+	+	A	+	+	-	-	+	+	+	+	+	+	A	+	+	+
ENDOCRINE SYSTEM																						
PITUITARY	+	-	+	+	-	-	+	-	A	+	+	-	-	+	+	+	+	+	A	+	-	+
ADRENAL CORTICAL ADENOMA	+	+	+	+	+	+	+	A	+	+	X	+	+	+	+	+	+	+	A	+	+	+
THYROID	+	+	+	+	+	+	+	A	+	+	-	+	+	+	+	+	+	+	A	-	+	+
C-CELL ADENOMA	+	+	+	+	+	+	+	A	+	+	-	+	+	+	+	+	+	+	A	-	+	+
PARATHYROID ADENOMA, NOS	+	+	+	-	-	+	+	-	A	-	+	-	-	+	-	+	+	-	A	-	-	-
PANCREATIC ISLETS	+	+	+	-	+	+	+	A	+	+	+	+	+	+	+	+	+	+	A	+	+	+
ISLET-CELL ADENOMA	+	+	+	-	+	+	+	A	+	+	+	+	+	+	+	+	+	+	A	+	+	X
REPRODUCTIVE SYSTEM																						
MAMMARY GLAND FIBROADENOMA	N	N	N	N	N	N	N	N	A	N	N	N	N	N	N	N	N	N	A	N	N	N
UTERUS PAPILLARY CARCINOMA ADENOMA, NOS	+	+	+	+	+	+	+	A	+	+	+	+	+	+	+	+	+	+	A	+	+	+
OVARY GRANULOSA-CELL TUMOR HEMANGIOMA	+	+	+	+	+	+	+	A	+	+	-	+	+	+	+	+	+	+	A	+	+	+
HEMANGIOMA										X												
ALL OTHER SYSTEMS																						
MULTIPLE ORGANS NOS	N	N	N	N	N	N	N	N	A	N	N	N	N	N	N	N	N	N	A	N	N	N
MALIG. LYMPHOMA, LYMPHOCYTIC TYPE																						
MALIG. LYMPHOMA, HISTIOCYTIC TYPE											X											

++ : TISSUE EXAMINED MICROSCOPICALLY  
 -- : REQUIRED TISSUE NOT EXAMINED MICROSCOPICALLY  
 X : TUMOR INCIDENCE  
 N : NECROPSY, NO AUTOLYSIS, NO MICROSCOPIC EXAMINATION

! : NO TISSUE INFORMATION SUBMITTED  
 C : NECROPSY, NO HISTOLOGY DUE TO PROTOCOL  
 A : AUTOLYSIS  
 M : ANIMAL MISSING  
 B : NO NECROPSY PERFORMED





**TABLE D2. FEMALE HAMSTERS: TUMOR PATHOLOGY (CONTINUED) CONTROL**

ANIMAL NUMBER	331	332	333	334	335	336	337	338	339	340	341	342	343	344	345	346	347	348	349	350	
WEEKS ON STUDY	073	073	073	073	073	073	073	073	073	073	073	073	073	073	073	073	073	073	073	073	
<b>RESPIRATORY SYSTEM</b>																					
LUNGS AND BRONCHI	+	+	+	A	+	+	+	+	+	+	+	+	+	+	+	+	+	+	+	+	A
TRACHEA	+	+	+	A	+	+	+	+	+	+	+	+	+	+	+	+	+	+	+	+	A
<b>HEMATOPOIETIC SYSTEM</b>																					
BONE MARROW	+	+	+	A	+	+	+	+	+	+	+	+	+	+	+	+	+	+	+	+	A
SPLEEN	+	+	+	A	+	+	+	+	+	+	+	+	+	+	+	+	+	+	+	+	A
LYMPH NODES	+	+	+	A	+	+	+	+	+	+	+	+	+	+	+	+	+	+	+	+	A
THYMUS	+	+	+	A	+	+	+	+	-	-	+	+	-	+	+	+	+	+	+	-	A
<b>CIRCULATORY SYSTEM</b>																					
HEART	+	+	+	A	+	+	+	+	+	+	+	+	+	+	+	+	+	+	+	+	A
<b>DIGESTIVE SYSTEM</b>																					
SALIVARY GLAND	+	+	+	A	+	+	+	+	+	+	+	+	+	+	+	+	+	+	+	-	A
LIVER	+	+	+	A	+	+	+	+	+	+	+	+	+	+	+	+	+	+	+	+	A
BILE DUCT	+	+	+	A	+	+	+	+	+	+	+	+	+	+	+	+	+	+	+	+	A
GALLBLADDER & COMMON BILE DUCT	N	N	+	A	N	+	N	+	N	N	N	+	N	N	N	+	N	N	N	N	A
PANCREAS	+	+	+	A	+	+	+	+	+	+	+	+	+	+	+	+	+	+	+	+	A
ESOPHAGUS	+	+	+	A	+	+	+	+	+	+	+	+	+	+	+	+	+	+	+	+	A
STOMACH	+	+	+	A	+	+	+	+	+	+	+	+	+	+	+	+	+	+	+	+	A
SMALL INTESTINE	+	+	+	A	+	+	+	+	+	+	+	+	+	+	+	+	+	+	+	+	A
LARGE INTESTINE	+	+	+	A	+	+	+	+	+	+	+	+	+	+	+	+	+	+	+	+	A
RECTUM ADENOMA, NOS	+	+	+	A	N	+	+	+	+	+	+	+	+	+	+	+	+	+	+	+	A
<b>URINARY SYSTEM</b>																					
KIDNEY	+	+	+	A	+	+	+	+	+	+	+	+	+	+	+	+	+	+	+	+	A
URINARY BLADDER	+	+	+	A	+	+	+	+	+	+	+	+	+	+	+	+	+	+	+	+	A
<b>ENDOCRINE SYSTEM</b>																					
PITUITARY	+	+	+	A	-	+	-	+	+	+	+	+	+	-	+	+	-	-	+	+	A
ADRENAL CORTICAL ADENOMA	+	+	+	A	-	+	+	+	+	+	+	+	+	+	+	+	+	+	+	+	A
THYROID C-CELL ADENOMA	+	+	+	A	+	+	+	+	+	-	+	+	+	-	+	-	+	-	+	+	A
PARATHYROID ADENOMA, NOS	+	-	-	A	+	+	+	+	-	-	+	-	-	-	-	-	-	-	-	-	A
PANCREATIC ISLETS ISLET-CELL ADENOMA	+	+	+	A	+	+	+	+	+	+	+	+	+	+	+	+	+	+	+	+	A
<b>REPRODUCTIVE SYSTEM</b>																					
MAMMARY GLAND FIBROADENOMA	N	N	N	A	N	N	N	N	N	N	N	N	N	N	N	N	N	N	N	N	A
UTERUS PAPILLARY CARCINOMA ADENOMA, NOS	+	+	+	A	+	+	+	+	+	+	+	+	+	+	+	+	+	+	+	+	A
OVARY GRANULOSA-CELL TUMOR HEMANGIOMA	+	+	+	A	+	+	+	+	+	+	+	+	+	+	+	+	+	+	+	+	A
<b>ALL OTHER SYSTEMS</b>																					
MULTIPLE ORGANS NOS	N	N	N	A	N	N	N	N	N	N	N	N	N	N	N	N	N	N	N	N	A
MALIG. LYMPHOMA, LYMPHOCYTIC TYPE	N	N	N	A	N	N	N	N	N	N	N	N	N	N	N	N	N	N	N	N	A
MALIG. LYMPHOMA, HISTIOCYTIC TYPE	N	N	N	A	N	N	N	N	N	N	N	N	N	N	N	N	N	N	N	N	A

+: TISSUE EXAMINED MICROSCOPICALLY  
 -: REQUIRED TISSUE NOT EXAMINED MICROSCOPICALLY  
 X: TUMOR INCIDENCE  
 N: NECROPSY, NO AUTOLYSIS, NO MICROSCOPIC EXAMINATION  
 : NO TISSUE INFORMATION SUBMITTED  
 C: NECROPSY, NO HISTOLOGY DUE TO PROTOCOL  
 A: AUTOLYSIS  
 M: ANIMAL MISSING  
 B: NO NECROPSY PERFORMED





TABLE D2.

INDIVIDUAL ANIMAL TUMOR PATHOLOGY OF FEMALE HAMSTERS ADMINISTERED AMOSITE ASBESTOS IN THE DIET

AMOSITE

ANIMAL NUMBER	0	1	2	3	4	5	6	7	8	9	10	11	12	13	14	15	16	17	18	19	20	21	22	23	24	25	
WEEKS ON STUDY	0	0	0	0	0	0	0	0	0	0	0	0	0	0	0	0	0	0	0	0	0	0	0	0	0	0	
<b>INTEGUMENTARY SYSTEM</b>																											
SUBCUTANEOUS TISSUE FIBROSARCOMA	+	A	+	+	+	+	+	+	+	+	+	+	+	+	+	+	+	+	+	+	+	+	+	N	+	+	+
<b>RESPIRATORY SYSTEM</b>																											
LUNGS AND BRONCHI FIBROSARCOMA, METASTATIC	+	A	+	+	+	+	+	+	+	+	+	+	+	+	+	+	+	+	+	+	+	+	+	+	+	+	+
TRACHEA	+	A	+	+	+	+	+	+	+	+	+	+	+	+	+	+	+	+	+	+	+	+	+	+	+	+	+
<b>HEMATOPOIETIC SYSTEM</b>																											
BONE MARROW	+	A	+	+	+	+	+	+	+	+	+	+	+	+	+	+	+	+	+	+	+	+	+	+	+	+	+
SPLEEN FIBROSARCOMA, METASTATIC	+	A	+	+	+	+	+	+	+	+	+	+	+	+	+	+	+	+	+	+	+	+	+	+	+	+	+
HEMANGIOMA HEMANGIOSARCOMA																											
LYMPH NODES MALIG. LYMPHOMA, LYMPHOCYTIC TYPE	+	A	+	+	+	+	+	+	+	+	+	+	+	+	+	+	+	+	+	+	+	+	+	+	+	+	+
MALIG. LYMPHOMA, HISTIOCYTIC TYPE																											
THYMUS	+	A	+	+	-	+	+	+	+	+	+	+	+	+	+	+	+	+	+	+	+	+	+	+	+	-	+
<b>CIRCULATORY SYSTEM</b>																											
HEART	+	A	+	+	+	+	+	+	+	+	+	+	+	+	+	+	+	+	+	+	+	+	+	+	+	+	+
<b>DIGESTIVE SYSTEM</b>																											
SALIVARY GLAND	+	A	+	+	+	+	+	+	+	+	+	+	+	+	+	+	+	+	+	+	+	+	+	+	+	+	+
LIVER	+	A	+	+	+	+	+	+	+	+	+	+	+	+	+	+	+	+	+	+	+	+	+	+	+	+	+
BILE DUCT	+	A	+	+	+	+	+	+	+	+	+	+	+	+	+	+	+	+	+	+	+	+	+	+	+	+	+
GALLBLADDER & COMMON BILE DUCT	N	A	N	N	N	N	N	N	N	N	N	N	N	N	N	N	N	N	N	N	N	N	N	N	N	N	N
PANCREAS	+	A	+	+	+	+	+	+	+	+	+	+	+	+	+	+	+	+	+	+	+	+	+	+	+	+	+
ESOPHAGUS	+	A	-	+	+	+	+	+	+	+	+	+	+	+	+	+	+	+	+	+	+	+	+	+	+	+	+
STOMACH PAPILOMA, NOS	+	A	+	+	+	+	+	+	+	+	+	+	+	+	+	+	+	+	+	+	+	+	+	+	+	+	+
SMALL INTESTINE	+	A	+	+	+	+	+	+	+	+	+	+	+	+	+	+	+	+	+	+	+	+	+	+	+	+	+
LARGE INTESTINE	+	A	+	+	-	+	+	+	+	+	+	+	+	+	+	+	+	+	+	+	+	+	+	+	+	+	+
RECTUM SQUAMOUS CELL PAPILOMA	+	A	+	+	N	+	+	+	+	+	+	+	+	+	+	+	+	+	+	+	+	+	+	+	+	+	+
<b>URINARY SYSTEM</b>																											
KIDNEY SARCOMA, NOS, METASTATIC	+	A	+	+	+	+	+	+	+	+	+	+	+	+	+	+	+	+	+	+	+	+	+	+	+	+	+
URINARY BLADDER TRANSITIONAL-CELL PAPILOMA	+	A	+	+	+	+	+	-	+	+	+	+	+	+	+	+	+	+	+	+	+	+	-	+	+	-	+
<b>ENDOCRINE SYSTEM</b>																											
PITUITARY	+	A	-	+	+	+	+	+	-	+	+	+	+	-	+	+	+	-	+	+	-	+	-	+	-	+	+
ADRENAL CORTICAL ADENOMA PHEOCHROMOCYTOMA	+	A	+	+	+	+	+	+	+	+	+	+	+	+	+	+	+	+	+	+	+	+	+	+	+	+	+
THYROID C-CELL ADENOMA C-CELL CARCINOMA	+	A	+	+	-	+	+	+	+	+	+	+	+	+	+	+	+	+	+	+	+	+	+	+	+	+	+
PARATHYROID ADENOMA, NOS	+	A	-	-	+	+	-	+	-	+	+	-	+	+	+	+	+	-	+	+	-	+	+	-	+	-	+
PANCREATIC ISLETS ISLET-CELL ADENOMA	+	A	+	+	+	+	+	+	+	+	+	+	+	+	+	+	+	+	+	+	+	+	+	+	+	+	+
<b>REPRODUCTIVE SYSTEM</b>																											
MAMMARY GLAND	N	A	N	N	N	N	N	N	N	N	N	N	N	N	N	N	N	N	N	N	N	N	N	N	N	N	N
VAGINA PAPILOMA, NOS	N	A	N	N	N	N	N	N	N	N	N	N	N	N	N	N	N	N	N	N	N	N	N	N	N	N	N
UTERUS PAPILLARY CARCINOMA	+	A	+	+	+	+	+	+	+	+	+	+	+	+	+	+	+	+	+	+	+	+	+	+	+	+	+
OVARY	+	A	+	+	+	+	+	+	+	+	+	+	+	+	+	+	+	+	+	+	+	+	+	+	+	+	+
<b>ALL OTHER SYSTEMS</b>																											
MULTIPLE ORGANS NOS FIBROSARCOMA, METASTATIC	N	A	N	N	N	N	N	N	N	N	N	N	N	N	N	N	N	N	N	N	N	N	N	N	N	N	N

+: TISSUE EXAMINED MICROSCOPICALLY  
 -: REQUIRED TISSUE NOT EXAMINED MICROSCOPICALLY  
 X: TUMOR INCIDENCE  
 N: NECROPSY, NO AUTOLYSIS, NO MICROSCOPIC EXAMINATION  
 -: NO TISSUE INFORMATION SUBMITTED  
 C: NECROPSY, NO HISTOLOGY DUE TO PROTOCOL  
 A: AUTOLYSIS  
 M: ANIMAL MISSING  
 B: NO NECROPSY PERFORMED

**TABLE D2. FEMALE HAMSTERS: TUMOR PATHOLOGY (CONTINUED) AMOSITE**

ANIMAL NUMBER	1	1	1	1	1	1	1	1	1	1	1	1	1	1	1	1	1	1	1	1	1						
WEEKS ON STUDY	2	3	1	2	3	3	3	4	4	4	4	5	5	5	6	6	6	7	7	7	8	8	8	9	9	9	9
<b>INTEGUMENTARY SYSTEM</b>																											
SUBCUTANEOUS TISSUE FIBROSARCOMA	+	+	+	+	+	+	+	+	+	+	+	+	+	+	+	+	+	+	+	+	+	+	+	+	+	+	+
<b>RESPIRATORY SYSTEM</b>																											
LUNGS AND BRONCHI FIBROSARCOMA, METASTATIC	+	+	+	+	+	+	+	+	+	+	+	+	+	+	+	+	+	+	+	+	+	+	+	+	+	+	+
TRACHEA	+	+	+	+	+	+	+	+	+	+	+	+	+	+	+	+	+	+	+	+	+	+	+	+	+	+	+
<b>HEMATOPOIETIC SYSTEM</b>																											
BONE MARROW	+	+	+	+	+	+	+	+	+	+	+	+	+	+	+	+	+	+	+	+	+	+	+	+	+	+	+
SPLEEN FIBROSARCOMA, METASTATIC HEMANGIOMA HEMANGIOSARCOMA	+	+	+	+	+	+	+	+	+	+	+	+	+	+	+	+	+	+	+	+	+	+	+	+	+	+	+
Lymph Nodes MALIGNANT LYMPHOMA, LYMPHOCYTIC TYPE MALIGNANT LYMPHOMA, HISTIOCYTIC TYPE	+	+	+	+	+	+	+	+	+	+	+	+	+	+	+	+	+	+	+	+	+	+	+	+	+	+	+
THYMUS	-	+	+	-	+	+	+	+	+	+	+	+	+	+	-	+	-	+	+	+	+	+	+	+	+	+	+
<b>CIRCULATORY SYSTEM</b>																											
HEART	+	+	+	+	+	+	+	+	+	+	+	+	+	+	+	+	+	+	+	+	+	+	+	+	+	+	+
<b>DIGESTIVE SYSTEM</b>																											
SALIVARY GLAND	+	+	+	+	+	+	+	+	+	+	+	+	+	+	+	+	+	+	+	+	+	+	+	+	+	+	+
LIVER	+	+	+	+	+	+	+	+	+	+	+	+	+	+	+	+	+	+	+	+	+	+	+	+	+	+	+
BILE DUCT	+	+	+	+	+	+	+	+	+	+	+	+	+	+	+	+	+	+	+	+	+	+	+	+	+	+	+
GALLBLADDER & COMMON BILE DUCT	+	N	N	N	+	N	N	N	+	N	N	N	N	N	N	N	N	+	N	+	+	N	N	+	+	+	+
PANCREAS	+	+	+	+	+	+	+	+	+	+	+	+	+	+	+	+	+	+	+	+	+	+	+	+	+	+	+
ESOPHAGUS	+	+	+	+	+	+	+	+	+	+	+	+	+	+	+	+	+	+	+	+	+	+	+	+	+	+	+
STOMACH PAPILLOMA, NOS	+	+	+	+	+	+	+	+	+	+	+	+	+	+	+	+	+	+	+	+	+	+	+	+	+	+	+
SMALL INTESTINE	+	+	+	+	+	+	+	+	+	+	+	+	+	+	+	+	+	+	+	+	+	+	+	+	+	+	+
LARGE INTESTINE	+	+	+	+	+	+	+	+	+	+	+	+	+	+	+	+	+	+	+	+	+	+	+	+	+	+	+
RECTUM SQUAMOUS CELL PAPILLOMA	+	+	+	+	+	+	+	+	+	N	+	+	+	+	+	+	+	+	+	+	+	+	+	+	+	+	+
<b>URINARY SYSTEM</b>																											
KIDNEY SARCOMA, NOS, METASTATIC	+	+	+	+	+	+	+	+	+	+	+	+	+	+	+	+	+	+	+	+	+	+	+	+	+	+	+
URINARY BLADDER TRANSITIONAL-CELL PAPILLOMA	+	+	+	+	-	+	+	+	+	+	+	+	+	+	+	+	+	+	+	+	+	+	+	+	+	+	+
<b>ENDOCRINE SYSTEM</b>																											
PITUITARY	+	-	+	+	+	+	+	-	+	+	-	+	-	+	-	+	-	+	+	+	+	+	+	+	+	+	+
ADRENAL CORTICAL ADENOMA PHEOCHROMOCYTOMA	+	+	+	+	+	+	+	+	+	+	+	+	+	+	+	+	+	+	+	+	+	+	+	+	+	+	+
THYROID C-CELL ADENOMA C-CELL CARCINOMA	+	+	+	+	+	+	+	+	+	+	+	+	+	+	+	+	+	+	+	+	+	+	+	+	+	+	+
PARATHYROID ADENOMA, NOS	+	+	+	+	+	-	-	+	+	-	-	+	-	-	-	-	-	+	-	-	-	+	+	+	+	+	
PANCREATIC ISLETS ISLET-CELL ADENOMA	+	+	+	+	+	+	+	+	+	+	+	+	+	+	+	+	+	+	+	+	+	+	+	+	+	+	+
<b>REPRODUCTIVE SYSTEM</b>																											
MAMMARY GLAND	N	N	N	N	N	N	N	N	N	N	N	N	N	N	N	N	N	N	N	N	N	N	N	N	N	N	N
VAGINA PAPILLOMA, NOS	N	N	N	N	N	N	N	N	N	N	N	N	N	N	N	N	N	N	N	N	N	N	N	N	N	N	N
UTERUS PAPILLARY CARCINOMA	+	+	+	+	+	+	+	+	+	+	+	+	+	+	+	+	+	+	+	+	+	+	+	+	+	+	+
OVARY	+	+	+	+	+	+	+	+	+	+	+	+	+	+	+	+	+	+	+	+	+	+	+	+	+	+	+
<b>ALL OTHER SYSTEMS</b>																											
MULTIPLE ORGANS NOS FIBROSARCOMA, METASTATIC	N	N	N	N	N	N	N	N	N	N	N	N	N	N	N	N	N	N	N	N	N	N	N	N	N	N	N

+: TISSUE EXAMINED MICROSCOPICALLY  
 -: REQUIRED TISSUE NOT EXAMINED MICROSCOPICALLY  
 X: TUMOR INCIDENCE  
 N: NECROPSY, NO AUTOLYSIS, NO MICROSCOPIC EXAMINATION  
 1: NO TISSUE INFORMATION SUBMITTED  
 C: NECROPSY, NO HISTOLOGY DUE TO PROTOCOL  
 A: AUTOLYSIS  
 M: ANIMAL MISSING  
 B: NO NECROPSY PERFORMED

**TABLE D2. FEMALE HAMSTERS: TUMOR PATHOLOGY (CONTINUED) AMOSITE**

ANIMAL NUMBER	1	2	2	2	2	2	2	2	2	2	2	2	2	2	2	2	2	2	2	2	2	2	2	2	2	2	2	2	2	2	2	2	2	2	2	2	2	2					
WEEKS ON STUDY	0	0	0	0	0	0	0	0	0	0	0	0	0	0	0	0	0	0	0	0	0	0	0	0	0	0	0	0	0	0	0	0	0	0	0	0	0	0	0	0			
<b>INTEGUMENTARY SYSTEM</b>																																											
SUBCUTANEOUS TISSUE FIBROSARCOMA	A	+	N	+	+	+	+	+	+	+	+	+	+	+	+	A	+	+	+	+	A	+	A	+	+	+	+	+	+	+	+	+	+	+	+	+	+	+	+	+			
<b>RESPIRATORY SYSTEM</b>																																											
LUNGS AND BRONCHI FIBROSARCOMA, METASTATIC	A	+	+	+	+	+	+	+	+	+	+	+	+	+	+	A	+	+	+	+	A	+	A	+	+	+	+	+	+	+	+	+	+	+	+	+	+	+	+	+			
TRACHEA	A	+	+	+	+	+	+	+	+	+	+	+	+	+	+	A	+	+	+	+	A	+	A	+	+	+	+	+	+	+	+	+	+	+	+	+	+	+	+	+	+		
<b>HEMATOPOIETIC SYSTEM</b>																																											
BONE MARROW	A	+	-	+	+	+	+	+	+	+	+	+	+	+	-	+	+	+	+	A	+	+	+	+	+	+	+	+	+	+	+	+	+	+	+	+	+	+	+	+			
SPLEEN FIBROSARCOMA, METASTATIC HEMANGIOMA HEMANGIOSARCOMA	A	+	+	+	+	+	+	+	+	+	+	+	+	+	+	A	+	+	+	+	A	+	A	+	+	+	+	+	+	+	+	+	+	+	+	+	+	+	+	+	+		
LYMPH NODES MALIG. LYMPHOMA, LYMPHOCYTTIC TYPE MALIG. LYMPHOMA, HISTIOCYTTIC TYPE	A	+	+	+	+	+	+	+	+	+	+	+	+	+	+	A	+	+	+	+	A	+	A	+	+	+	+	+	+	+	+	+	+	+	+	+	+	+	+	+	+		
THYMUS	A	+	+	-	-	+	+	+	+	+	+	+	+	+	-	+	+	+	+	A	+	+	+	+	A	-	A	+	+	-	+	+	+	+	+	+	+	+	+	+	+		
<b>CIRCULATORY SYSTEM</b>																																											
HEART	A	+	+	+	+	+	+	+	+	+	+	+	+	+	+	A	+	+	+	+	A	+	A	+	+	+	+	+	+	+	+	+	+	+	+	+	+	+	+	+	+		
<b>DIGESTIVE SYSTEM</b>																																											
SALIVARY GLAND	A	+	+	+	+	+	+	+	+	+	+	+	+	+	+	-	+	+	+	A	+	+	+	A	-	A	+	+	+	+	+	+	+	+	+	+	+	+	+	+	+		
LIVER	A	+	+	+	+	+	+	+	+	+	+	+	+	+	+	+	+	+	+	A	+	+	+	A	+	A	+	+	+	+	+	+	+	+	+	+	+	+	+	+	+	+	
BILE DUCT	A	+	+	+	+	+	+	+	+	+	+	+	+	+	+	+	+	+	+	A	+	+	+	A	+	A	+	+	+	+	+	+	+	+	+	+	+	+	+	+	+	+	
GALLBLADDER & COMMON BILE DUCT	A	N	+	+	+	+	+	+	N	N	N	N	N	N	N	A	+	N	N	A	N	N	A	N	N	N	N	N	N	N	N	N	N	N	N	N	N	N	N	N	N	N	
PANCREAS	A	+	+	+	+	+	+	+	+	+	+	+	+	+	+	-	+	+	+	A	+	+	+	A	+	A	+	+	+	+	+	+	+	+	+	+	+	+	+	+	+	+	+
ESOPHAGUS	A	+	+	+	+	+	+	+	+	+	+	+	+	+	+	+	+	+	+	A	+	+	+	A	+	A	+	+	+	+	+	+	+	+	+	+	+	+	+	+	+	+	+
STOMACH PAPILOMA, NOS	A	+	+	+	+	+	+	+	+	+	+	+	+	+	+	+	+	+	+	A	+	+	+	X	+	A	+	A	+	+	+	+	+	+	+	+	+	+	+	+	+	+	
SMALL INTESTINE	A	+	+	+	+	+	+	+	+	+	+	+	+	+	+	+	+	+	+	A	+	+	+	A	+	A	+	+	+	+	+	+	+	+	+	+	+	+	+	+	+	+	
LARGE INTESTINE	A	+	+	+	+	+	+	+	+	+	+	+	+	+	+	+	+	+	+	A	+	+	+	A	+	A	+	+	+	+	+	+	+	+	+	+	+	+	+	+	+	+	
RECTUM SQUAMOUS CELL PAPILOMA	A	+	+	+	+	+	+	+	+	+	+	+	+	+	+	+	N	+	A	+	+	+	A	+	A	+	+	+	+	+	+	+	+	+	+	+	+	+	+	+	+	+	
<b>URINARY SYSTEM</b>																																											
KIDNEY SARCOMA, NOS, METASTATIC	A	+	+	+	+	+	+	+	+	+	+	+	+	+	+	+	A	+	+	+	A	+	A	+	+	+	+	+	+	+	+	+	+	+	+	+	+	+	+	+	+	+	
URINARY BLADDER TRANSITIONAL-CELL PAPILOMA	A	+	+	+	+	+	+	+	+	+	+	+	+	+	+	+	+	+	+	A	+	+	+	A	+	A	+	+	-	+	+	+	+	+	+	+	+	+	+	+	+	+	
<b>ENDOCRINE SYSTEM</b>																																											
PITUITARY	A	-	+	+	+	+	+	+	+	+	+	+	+	+	+	-	-	+	-	A	+	+	+	A	+	A	+	+	+	+	+	+	+	+	+	+	+	+	+	+	+		
ADRENAL CORTICAL ADENOMA PHEOCHROMOCYTOMA	A	+	+	+	+	+	+	+	+	+	+	+	+	+	+	+	+	+	+	A	+	+	+	A	+	A	+	+	+	+	+	+	+	+	+	+	+	+	+	+	+	+	
THYROID C-CELL ADENOMA C-CELL CARCINOMA	A	+	+	+	+	+	+	+	+	+	+	+	+	+	+	-	-	+	+	A	+	+	+	A	+	A	+	+	+	+	+	+	+	+	+	+	+	+	+	+	+	+	
PARATHYROID ADENOMA, NOS	A	-	+	-	-	+	+	-	-	-	-	-	-	-	-	-	-	-	-	+	+	+	-	A	+	A	+	+	+	+	+	+	+	+	+	+	+	+	+	+	+	+	
PANCREATIC ISLETS ISLET-CELL ADENOMA	A	+	+	+	+	+	+	+	+	+	+	+	+	+	+	+	+	+	+	A	+	+	+	A	+	A	+	+	+	+	+	+	+	+	+	+	+	+	+	+	+	+	
<b>REPRODUCTIVE SYSTEM</b>																																											
MAMMARY GLAND	A	N	N	N	N	N	N	N	N	N	N	N	N	N	N	N	N	N	N	N	N	N	N	N	N	N	N	N	N	N	N	N	N	N	N	N	N	N	N	N	N	N	
VAGINA PAPILOMA, NOS	A	N	N	N	N	N	N	N	N	N	N	N	N	N	N	N	N	N	N	N	N	N	N	N	N	N	N	N	N	N	N	N	N	N	N	N	N	N	N	N	N	N	N
UTERUS PAPILLARY CARCINOMA	A	+	+	+	+	+	+	+	+	+	+	+	+	+	+	+	+	+	+	A	+	+	+	A	+	A	+	+	+	+	+	+	+	+	+	+	+	+	+	+	+	+	+
OVARY	A	+	+	+	+	+	+	+	+	+	+	+	+	+	+	+	+	+	+	+	A	+	+	+	A	+	A	+	+	+	+	+	+	+	+	+	+	+	+	+	+	+	+
<b>ALL OTHER SYSTEMS</b>																																											
MULTIPLE ORGANS NOS FIBROSARCOMA, METASTATIC	A	N	N	N	N	N	N	N	N	N	N	N	N	N	N	N	N	N	N	N	N	N	N	N	N	N	N	N	N	N	N	N	N	N	N	N	N	N	N	N	N	N	

++ TISSUE EXAMINED MICROSCOPICALLY  
 -I REQUIRED TISSUE NOT EXAMINED MICROSCOPICALLY  
 X: TUMOR INCIDENCE  
 N: NECROPSY, NO AUTOLYSIS, NO MICROSCOPIC EXAMINATION  
 I NO TISSUE INFORMATION SUBMITTED  
 C: NECROPSY, NO HISTOLOGY DUE TO PROTOCOL  
 A: AUTOLYSIS  
 M: ANIMAL MISSING  
 B: NO NECROPSY PERFORMED



**TABLE D2. FEMALE HAMSTERS: TUMOR PATHOLOGY (CONTINUED) AMOSITE**

ANIMAL NUMBER	372	373	381	382	383	401	402	403	411	412	413	421	422	423	431	432	433	441	442	443	451	452	453	461	462	463	471	472	473
WEEKS ON STUDY	2	3	4	5	6	9	10	11	12	13	14	15	16	17	18	19	20	21	22	23	24	25	26	27	28	29	30	31	32
<b>INTEGUMENTARY SYSTEM</b>																													
SUBCUTANEOUS TISSUE FIBROSARCOMA	+	+	+	+	+	+	+	+	+	+	+	A	+	+	+	+	+	+	+	+	+	+	+	+	+	+	A	+	+
<b>RESPIRATORY SYSTEM</b>																													
LUNGS AND BRONCHI FIBROSARCOMA, METASTATIC	+	+	+	+	+	+	+	+	+	+	+	A	+	+	+	+	+	+	+	+	+	+	+	+	+	+	A	+	+
TRACHEA	+	+	+	+	+	+	+	+	+	+	+	A	+	+	+	+	+	+	+	+	+	+	+	+	+	+	A	+	+
<b>HEMATOPOIETIC SYSTEM</b>																													
BONE MARROW	+	+	+	+	+	+	+	+	+	+	+	A	+	+	+	+	+	+	+	+	+	+	+	+	+	+	A	+	+
SPLEEN FIBROSARCOMA, METASTATIC	+	+	+	+	+	+	+	+	+	+	+	A	+	+	+	+	+	+	+	+	+	+	+	+	+	+	A	+	+
HEMANGIOMA																													
HEMANGIOSARCOMA																													
LYMPH NODES	+	+	+	+	+	+	+	+	+	+	+	A	+	+	+	+	+	+	+	+	+	+	+	+	+	+	A	+	+
MALIG. LYMPHOMA, LYMPHOCTIC TYPE																													
MALIG. LYMPHOMA, HISTIOCYTIC TYPE																													
THYMUS	+	+	+	+	+	+	+	+	+	+	+	A	+	+	+	+	+	+	+	+	+	+	+	+	+	+	A	+	+
<b>CIRCULATORY SYSTEM</b>																													
HEART	+	+	+	+	+	+	+	+	+	+	+	A	+	+	+	+	+	+	+	+	+	+	+	+	+	+	A	+	+
<b>DIGESTIVE SYSTEM</b>																													
SALIVARY GLAND	+	-	+	+	+	+	+	+	+	+	+	A	+	+	+	+	+	+	+	+	+	+	+	+	+	+	A	+	+
LIVER	+	+	+	+	+	+	+	+	+	+	+	A	+	+	+	+	+	+	+	+	+	+	+	+	+	+	A	+	+
BILE DUCT	+	+	+	+	+	+	+	+	+	+	+	A	+	+	+	+	+	+	+	+	+	+	+	+	+	+	A	+	+
GALLBLADDER & COMMON BILE DUCT	N	N	N	+	N	N	N	N	N	N	N	N	N	N	N	N	N	N	N	N	N	N	N	N	N	N	N	N	N
PANCREAS	+	+	+	+	+	+	+	+	+	+	+	A	+	+	+	+	+	+	+	+	+	+	+	+	+	+	A	+	+
ESOPHAGUS	+	+	+	+	+	+	+	+	+	+	+	A	+	+	+	+	+	+	+	+	+	+	+	+	+	+	A	+	+
STOMACH PAPILLOMA, NOS	+	+	+	+	+	+	+	+	+	+	+	A	+	+	+	+	+	+	+	+	+	+	+	+	+	+	A	+	+
SMALL INTESTINE	+	+	+	+	+	+	+	+	+	+	+	A	+	+	+	+	+	+	+	+	+	+	+	+	+	+	A	+	+
LARGE INTESTINE	+	+	+	+	+	+	+	+	+	+	+	A	+	+	+	+	+	+	+	+	+	+	+	+	+	+	A	+	+
RECTUM SQUAMOUS CELL PAPILLOMA	+	+	+	+	+	+	+	+	+	+	+	A	+	+	+	+	+	+	+	+	+	+	+	+	+	+	A	+	+
<b>URINARY SYSTEM</b>																													
KIDNEY SARCOMA, NOS, METASTATIC	+	+	+	+	+	+	+	+	+	+	+	A	+	+	+	+	+	+	+	+	+	+	+	+	+	+	A	+	+
URINARY BLADDER TRANSITIONAL-CELL PAPILLOMA	+	+	+	+	+	+	+	+	+	+	+	A	+	-	-	+	+	+	+	+	+	+	+	+	+	+	A	+	+
<b>ENDOCRINE SYSTEM</b>																													
PITUITARY	+	-	+	+	+	+	+	+	+	+	+	A	-	-	+	+	-	-	-	-	-	-	-	-	-	+	A	-	+
ADRENAL CORTICAL ADENOMA	+	+	+	+	+	+	+	+	+	+	+	A	+	+	+	+	+	+	+	+	+	+	+	+	+	+	A	+	+
PHEOCHROMOCYTOMA																													
THYROID C-CELL ADENOMA	+	+	+	+	+	+	+	+	+	+	+	A	+	+	+	+	+	+	+	+	+	+	+	+	+	+	A	+	+
C-CELL CARCINOMA																													
PARATHYROID ADENOMA, NOS	+	-	-	-	-	-	+	+	+	+	+	A	+	+	+	+	+	+	+	+	+	+	+	+	+	+	A	+	-
PANCREATIC ISLETS ISLET-CELL ADENOMA	+	+	+	+	+	+	+	+	+	+	+	A	+	+	+	+	+	+	+	+	+	+	+	+	+	+	A	+	+
<b>REPRODUCTIVE SYSTEM</b>																													
MAMMARY GLAND	N	N	N	N	N	N	N	N	N	N	N	N	N	N	N	N	N	N	N	N	N	N	N	N	N	N	N	N	N
VAGINA PAPILLOMA, NOS	N	N	N	N	N	N	N	N	N	N	N	N	N	N	N	N	N	N	N	N	N	N	N	N	N	N	N	N	N
UTERUS PAPILLARY CARCINOMA	+	+	+	+	+	+	+	+	+	+	+	A	+	+	+	+	+	+	+	+	+	+	+	+	+	+	A	+	+
OVARY	+	+	+	+	+	+	+	+	+	+	+	A	+	+	+	+	+	+	+	+	+	+	+	+	+	+	A	+	+
<b>ALL OTHER SYSTEMS</b>																													
MULTIPLE ORGANS NOS FIBROSARCOMA, METASTATIC	N	N	N	N	N	N	N	N	N	N	N	N	N	N	N	N	N	N	N	N	N	N	N	N	N	N	N	N	N

+: TISSUE EXAMINED MICROSCOPICALLY  
 -: REQUIRED TISSUE NOT EXAMINED MICROSCOPICALLY  
 X: TUMOR INCIDENCE  
 N: NECROPSY, NO AUTOLYSIS, NO MICROSCOPIC EXAMINATION  
 I: NO TISSUE INFORMATION SUBMITTED  
 C: NECROPSY, NO HISTOLOGY DUE TO PROTOCOL  
 A: AUTOLYSIS  
 M: ANIMAL MISSING  
 B: NO NECROPSY PERFORMED

**TABLE D2. FEMALE HAMSTERS: TUMOR PATHOLOGY (CONTINUED) AMOSITE**

ANIMAL NUMBER	473	481	482	483	491	492	493	501	502	503	511	513	521	522	523	531	532	533	541	542	543	551	552	553	561	562	563		
WEEKS ON STUDY	0	0	0	0	0	0	0	0	0	0	0	0	0	0	0	0	0	0	0	0	0	0	0	0	0	0	0		
<b>INTEGUMENTARY SYSTEM</b>																													
SUBCUTANEOUS TISSUE FIBROSARCOMA	+	N	+	+	+	M	A	+	N	+	+	+	+	+	+	+	+	+	+	+	+	+	+	N	+	+	N	+	
<b>RESPIRATORY SYSTEM</b>																													
LUNGS AND BRONCHI FIBROSARCOMA, METASTATIC	+	+	+	+	+	M	A	+	+	+	+	+	+	+	+	+	+	+	+	+	+	+	+	+	+	+	+	+	+
TRACHEA	+	+	+	+	+	M	A	+	+	+	+	+	+	+	+	+	+	+	+	+	+	+	+	+	+	+	+	+	+
<b>HEMATOPOIETIC SYSTEM</b>																													
BONE MARROW	+	+	+	+	+	M	A	+	+	+	+	+	+	+	+	+	+	+	+	+	+	+	+	+	+	+	+	-	+
SPLEEN FIBROSARCOMA, METASTATIC	+	+	+	+	+	M	A	+	+	+	+	+	+	+	+	+	+	+	+	+	+	+	+	+	+	+	+	+	+
HEMANGIOMA	+	+	+	+	+	M	A	+	+	+	+	+	+	+	+	+	+	+	+	+	+	+	+	+	+	+	+	+	+
HEMANGIOSARCOMA	+	+	+	+	+	M	A	+	+	+	+	+	+	+	+	+	+	+	+	+	+	+	+	+	+	+	+	+	+
LYMPH NODES	+	+	+	+	+	M	A	+	+	+	+	+	+	+	+	+	+	+	+	+	+	+	+	+	+	+	+	+	+
MALIG. LYMPHOMA, LYMPHOCYTIC TYPE																													
MALIG. LYMPHOMA, HISTIOCYTIC TYPE																													
THYMUS	+	+	+	+	+	M	A	+	+	+	+	+	+	+	+	+	+	+	+	+	+	+	+	+	+	+	+	+	+
<b>CIRCULATORY SYSTEM</b>																													
HEART	+	+	+	+	+	M	A	+	+	+	+	+	+	+	+	+	+	+	+	+	+	+	+	+	+	+	+	+	+
<b>DIGESTIVE SYSTEM</b>																													
SALIVARY GLAND	+	+	-	+	+	M	A	+	+	+	+	+	+	+	+	+	+	+	+	+	+	+	+	+	+	+	+	+	+
LIVER	+	+	+	+	+	M	A	+	+	+	+	+	+	+	+	+	+	+	+	+	+	+	+	+	+	+	+	+	+
BILE DUCT	+	+	+	+	+	M	A	+	+	+	+	+	+	+	+	+	+	+	+	+	+	+	+	+	+	+	+	+	+
GALLBLADDER & COMMON BILE DUCT	N	N	N	N	N	M	A	+	N	+	N	N	N	N	N	N	N	N	N	N	N	N	N	N	N	N	N	N	N
PANCREAS	+	+	-	+	+	M	A	+	-	+	+	+	+	+	+	+	+	+	+	+	+	+	+	+	+	+	+	+	+
ESOPHAGUS	+	+	+	+	+	M	A	+	+	+	+	+	+	+	+	+	+	+	+	+	+	+	+	+	+	+	+	+	+
STOMACH PAPILOMA, NOS	+	+	+	+	+	M	A	+	+	+	+	+	+	+	+	+	+	+	+	+	+	+	+	+	+	+	+	+	X
SMALL INTESTINE	+	+	+	+	+	M	A	+	+	+	+	+	+	+	+	+	+	+	+	+	+	+	+	+	+	+	+	+	+
LARGE INTESTINE	+	+	+	+	+	M	A	+	+	+	+	+	+	+	+	+	+	+	+	+	+	+	+	+	+	+	+	+	+
RECTUM SQUAMOUS CELL PAPILOMA	+	+	+	+	+	M	A	+	N	+	+	+	+	+	+	+	+	+	+	+	+	+	+	+	+	+	+	+	+
<b>URINARY SYSTEM</b>																													
KIDNEY SARCOMA, NOS, METASTATIC	+	+	+	+	+	M	A	+	+	+	+	+	+	+	+	+	+	+	+	+	+	+	+	+	+	+	+	+	+
URINARY BLADDER TRANSITIONAL-CELL PAPILOMA	-	+	+	+	+	M	A	+	-	+	+	+	+	+	+	+	+	+	+	+	+	+	+	+	+	+	+	+	+
<b>ENDOCRINE SYSTEM</b>																													
PITUITARY	-	+	-	+	+	M	A	-	+	+	-	+	+	-	+	-	+	-	+	-	+	-	+	-	+	-	+	-	+
ADRENAL CORTICAL ADENOMA PHEOCHROMOCYTOMA	+	+	+	+	+	M	A	+	+	+	+	+	+	+	+	+	+	+	+	+	+	+	+	+	+	+	+	+	+
THYROID C-CELL ADENOMA C-CELL CARCINOMA	+	+	+	+	-	M	A	+	+	-	+	+	+	+	+	+	+	+	+	+	+	+	+	+	+	+	+	+	+
PARATHYROID ADENOMA, NOS	+	+	+	-	-	M	A	+	+	+	-	-	+	+	+	+	+	+	+	+	+	+	+	+	+	+	+	+	+
PANCREATIC ISLETS ISLET-CELL ADENOMA	+	+	-	+	+	M	A	+	-	+	+	+	+	+	+	+	+	+	+	+	+	+	+	+	+	+	+	+	+
<b>REPRODUCTIVE SYSTEM</b>																													
MAMMARY GLAND	N	N	N	N	N	M	A	N	N	N	N	N	N	N	N	N	N	N	N	N	N	N	N	N	N	N	N	N	N
VAGINA PAPILOMA, NOS	N	N	N	N	N	M	A	N	N	N	N	N	N	N	N	N	N	N	N	N	N	N	N	N	N	N	N	N	N
UTERUS PAPILLARY CARCINOMA	+	+	+	+	+	M	A	+	+	+	+	+	+	+	+	+	+	+	+	+	+	+	+	+	+	+	+	+	+
OVARY	+	+	-	+	+	M	A	+	+	+	+	+	+	+	+	+	+	+	+	+	+	+	+	+	+	+	+	+	+
<b>ALL OTHER SYSTEMS</b>																													
MULTIPLE ORGANS NOS FIBROSARCOMA, METASTATIC	N	N	N	N	N	M	A	N	N	N	N	N	N	N	N	N	N	N	N	N	N	N	N	N	N	N	N	N	N

+: TISSUE EXAMINED MICROSCOPICALLY  
 -: REQUIRED TISSUE NOT EXAMINED MICROSCOPICALLY  
 X: TUMOR INCIDENCE  
 N: NECROPSY, NO AUTOLYSIS, NO MICROSCOPIC EXAMINATION  
 ! NO TISSUE INFORMATION SUBMITTED  
 C: NECROPSY, NO HISTOLOGY DUE TO PROTOCOL  
 A: AUTOLYSIS  
 M: ANIMAL MISSING  
 B: NO NECROPSY PERFORMED

**TABLE D2. FEMALE HAMSTERS: TUMOR PATHOLOGY (CONTINUED) AMOSITE**

ANIMAL NUMBER	571	572	573	581	582	583	591	592	593	601	602	603	611	612	621	622	631	632	633	641	642	643	651	652	653	661	662	663	
WEEKS ON STUDY	0	0	0	0	0	0	0	0	0	0	0	0	0	0	0	0	0	0	0	0	0	0	0	0	0	0	0	0	0
<b>INTEGUMENTARY SYSTEM</b>																													
SUBCUTANEOUS TISSUE FIBROSARCOMA	+	+	+	N	+	+	N	+	N	N	+	N	+	+	+	+	+	+	+	+	+	+	+	+	+	+	+	+	
<b>RESPIRATORY SYSTEM</b>																													
LUNGS AND BRONCHI FIBROSARCOMA, METASTATIC	+	+	+	+	+	+	+	+	+	+	+	+	+	+	+	+	+	+	+	+	A	+	+	+	+	+	+	+	
TRACHEA	+	+	+	+	+	+	+	+	+	+	+	+	+	+	+	+	+	+	+	+	A	+	+	+	+	+	+	+	
<b>HEMATOPOIETIC SYSTEM</b>																													
BONE MARROW	+	+	+	+	+	+	+	+	+	+	+	+	+	+	+	+	+	+	+	+	+	+	+	+	+	+	+	+	
SPLEEN FIBROSARCOMA, METASTATIC	+	+	+	+	+	+	+	+	+	+	+	+	+	+	+	+	+	+	+	+	+	+	+	+	+	+	+	+	
HEMANGIOMA																													
HEMANGIOSARCOMA																													
LYMPH NODES	+	+	+	+	+	+	+	+	+	+	+	+	+	+	+	+	+	+	+	+	+	+	+	+	+	+	+	+	
MALIG. LYMPHOMA, LYMPHOCTIC TYPE																													
MALIG. LYMPHOMA, HISTIOCYTIC TYPE																													
THYMUS	+	+	+	+	+	+	+	+	+	+	+	+	+	+	+	+	+	+	+	+	A	-	-	+	-	+	+	+	
<b>CIRCULATORY SYSTEM</b>																													
HEART	+	+	+	+	+	+	+	+	+	+	+	+	+	+	+	+	+	+	+	+	A	+	+	+	+	+	+	+	
<b>DIGESTIVE SYSTEM</b>																													
SALIVARY GLAND	+	+	+	+	+	+	+	+	+	+	+	+	+	+	+	+	+	+	+	+	A	+	+	+	+	+	+	+	
LIVER	+	+	+	+	+	+	+	+	+	+	+	+	+	+	+	+	+	+	+	+	+	+	+	+	+	+	+	+	
BILE DUCT	+	+	+	+	+	+	+	+	+	+	+	+	+	+	+	+	+	+	+	+	+	+	+	+	+	+	+	+	
GALLBLADDER & COMMON BILE DUCT	N	+	N	N	N	N	+	N	N	N	N	N	N	N	N	N	N	N	N	N	N	N	+	N	N	N	N	+	
PANCREAS	+	+	+	+	+	+	+	+	+	+	+	+	+	+	+	+	+	+	+	+	+	+	+	+	+	+	+	+	
ESOPHAGUS	+	+	+	+	+	+	+	+	+	+	+	+	+	+	+	+	+	+	+	+	A	+	+	+	+	+	+	+	
STOMACH PAPILOMA, NOS	+	+	+	+	+	+	+	+	+	+	+	+	+	+	+	+	+	+	+	+	+	+	+	+	+	+	+	+	
SMALL INTESTINE	+	+	+	+	+	+	+	+	+	+	+	+	+	+	+	+	+	+	+	+	+	+	+	+	+	+	+	+	
LARGE INTESTINE	+	+	+	+	+	+	+	+	+	+	+	+	+	+	+	+	+	+	+	+	+	+	+	+	+	+	+	+	
RECTUM SQUAMOUS CELL PAPILOMA	+	+	+	+	+	+	+	+	+	+	+	+	+	+	+	+	+	+	+	+	+	+	+	+	+	+	+	+	
<b>URINARY SYSTEM</b>																													
KIDNEY SARCOMA, NOS, METASTATIC	+	+	+	+	+	+	+	+	+	+	+	+	+	+	+	+	+	+	+	+	+	+	+	+	+	+	+	+	
URINARY BLADDER TRANSITIONAL-CELL PAPILOMA	-	+	+	+	+	+	+	+	+	+	+	+	+	+	+	+	+	+	+	+	+	+	+	+	+	+	+	+	
<b>ENDOCRINE SYSTEM</b>																													
PITUITARY	-	+	+	-	-	+	+	-	-	-	+	+	-	+	-	+	-	+	-	+	-	+	-	+	-	+	-	+	
ADRENAL CORTICAL ADENOMA	-	+	+	+	+	+	+	+	+	+	+	+	+	+	+	+	+	+	+	+	+	+	+	+	+	+	+	+	
PHEOCHROMOCYTOMA			X			X																							
THYROID C-CELL ADENOMA	+	+	+	+	+	+	+	+	+	+	+	+	+	+	+	+	+	+	+	+	A	+	+	+	+	+	+	+	
C-CELL CARCINOMA																													
PARATHYROID ADENOMA, NOS	-	-	-	-	+	-	+	+	+	+	+	+	+	+	+	+	+	+	+	+	A	-	+	+	-	-	+	-	
PANCREATIC ISLETS ISLET-CELL ADENOMA	+	+	+	+	+	+	+	+	+	+	+	+	+	+	+	+	+	+	+	+	+	+	+	+	+	+	+	+	
<b>REPRODUCTIVE SYSTEM</b>																													
MAMMARY GLAND	N	N	N	N	N	N	N	N	N	N	N	N	N	N	N	N	N	N	N	N	N	N	N	N	N	N	N	N	
VAGINA PAPILOMA, NOS	N	N	N	N	N	N	N	N	N	N	N	N	N	N	N	N	N	N	N	N	N	N	N	N	N	N	N	N	
UTERUS PAPILLARY CARCINOMA	-	+	+	+	+	+	+	+	+	+	+	+	+	+	+	+	+	+	+	+	+	+	+	+	+	+	+	+	
OVARY	-	+	-	+	+	+	+	-	+	+	+	+	+	+	+	+	+	+	+	+	+	+	+	+	+	+	+	+	
<b>ALL OTHER SYSTEMS</b>																													
MULTIPLE ORGANS NOS FIBROSARCOMA, METASTATIC	N	N	N	N	N	N	N	N	N	N	N	N	N	N	N	N	N	N	N	N	N	N	N	N	N	N	N	N	

+: TISSUE EXAMINED MICROSCOPICALLY  
 -: REQUIRED TISSUE NOT EXAMINED MICROSCOPICALLY  
 X: TUMOR INCIDENCE  
 N: NECROPSY, NO AUTOLYSIS, NO MICROSCOPIC EXAMINATION  
 I: NO TISSUE INFORMATION SUBMITTED  
 C: NECROPSY, NO HISTOLOGY DUE TO PROTOCOL  
 A: AUTOLYSIS  
 M: ANIMAL MISSING  
 B: NO NECROPSY PERFORMED



**TABLE D2. FEMALE HAMSTERS: TUMOR PATHOLOGY (CONTINUED) AMOSITE**

ANIMAL NUMBER	662	663	667	668	669	670	671	672	673	674	675	676	677	678	679	680	681	682	683	684	685	686	687	688	689	690
WEEKS ON STUDY	0	0	0	0	0	0	0	0	0	0	0	0	0	0	0	0	0	0	0	0	0	0	0	0	0	0
<b>INTEGUMENTARY SYSTEM</b>																										
SUBCUTANEOUS TISSUE FIBROSARCOMA	+	+	+	+	+	+	+	+	+	+	+	+	+	+	+	+	+	+	+	+	+	+	+	+	+	+
<b>RESPIRATORY SYSTEM</b>																										
LUNGS AND BRONCHI FIBROSARCOMA, METASTATIC	+	+	+	+	+	+	+	-	+	+	+	+	+	+	+	+	+	+	+	+	+	+	+	+	+	+
TRACHEA	+	-	+	+	+	+	+	+	+	+	+	+	+	+	+	+	+	+	+	+	+	+	+	+	+	+
<b>HEMATOPOIETIC SYSTEM</b>																										
BONE MARROW	+	+	+	+	+	+	+	+	+	+	+	+	+	+	+	+	+	+	+	+	+	+	+	+	+	+
SPLEEN FIBROSARCOMA, METASTATIC	+	+	+	+	+	+	+	+	+	+	+	+	+	+	+	+	+	+	+	+	+	+	+	+	+	+
HEMANGIOMA	+	+	+	+	+	+	+	+	+	+	+	+	+	+	+	+	+	+	+	+	+	+	+	+	+	+
HEMANGIOSARCOMA	+	+	+	+	+	+	+	+	+	+	+	+	+	+	+	+	+	+	+	+	+	+	+	+	+	+
LYMPH NODES	+	+	+	+	+	+	+	+	+	+	+	+	+	+	+	+	+	+	+	+	+	+	+	+	+	+
MALIG. LYMPHOMA, LYMPHOCYTIC TYPE	+	+	+	+	+	+	+	+	+	+	+	+	+	+	+	+	+	+	+	+	+	+	+	+	+	+
MALIG. LYMPHOMA, HISTIOCYTIC TYPE	+	+	+	+	+	+	+	+	+	+	+	+	+	+	+	+	+	+	+	+	+	+	+	+	+	+
THYMUS	-	+	-	-	+	+	+	+	+	+	+	+	+	+	+	+	+	+	+	+	+	+	+	+	+	+
<b>CIRCULATORY SYSTEM</b>																										
HEART	+	+	+	+	+	+	+	+	+	+	+	+	+	+	+	+	+	+	+	+	+	+	+	+	+	+
<b>DIGESTIVE SYSTEM</b>																										
SALIVARY GLAND	+	+	+	+	+	+	+	+	+	+	+	+	+	+	+	+	+	+	+	+	+	+	+	+	+	+
LIVER	+	+	+	+	+	+	+	+	+	+	+	+	+	+	+	+	+	+	+	+	+	+	+	+	+	+
BILE DUCT	+	+	+	+	+	+	+	+	+	+	+	+	+	+	+	+	+	+	+	+	+	+	+	+	+	+
GALLBLADDER & COMMON BILE DUCT	N	N	N	N	N	N	N	N	N	N	N	N	N	N	N	N	N	N	N	N	N	N	N	N	N	N
PANCREAS	+	+	+	+	+	+	+	+	+	+	+	+	+	+	+	+	+	+	+	+	+	+	+	+	+	+
ESOPHAGUS	+	+	+	+	+	+	+	+	+	+	+	+	+	+	+	+	+	+	+	+	+	+	+	+	+	+
STOMACH PAPILOMA, NOS	+	+	+	+	+	+	+	+	+	+	+	+	+	+	+	+	+	+	+	+	+	+	+	+	+	+
SMALL INTESTINE	+	+	+	+	+	+	+	+	+	+	+	+	+	+	+	+	+	+	+	+	+	+	+	+	+	+
LARGE INTESTINE	+	+	+	+	+	+	+	+	+	+	+	+	+	+	+	+	+	+	+	+	+	+	+	+	+	+
RECTUM SQUAMOUS CELL PAPILOMA	+	+	+	+	+	+	+	+	+	+	+	+	+	+	+	+	+	+	+	+	+	+	+	+	+	+
<b>URINARY SYSTEM</b>																										
KIDNEY SARCOMA, NOS, METASTATIC	+	+	+	+	+	+	+	+	+	+	+	+	+	+	+	+	+	+	+	+	+	+	+	+	+	+
URINARY BLADDER TRANSITIONAL-CELL PAPILOMA	+	+	+	+	+	+	+	+	+	+	+	+	+	+	+	+	+	+	+	+	+	+	+	+	+	+
<b>ENDOCRINE SYSTEM</b>																										
PITUITARY	+	+	+	+	+	-	-	-	+	-	-	+	+	+	+	+	+	-	-	-	+	+	+	+	+	+
ADRENAL CORTICAL ADENOMA	+	+	+	+	+	+	+	+	+	+	+	+	+	+	+	+	+	+	+	+	+	+	+	+	+	+
PHEOCHROMOCYTOMA																										
THYROID C-CELL ADENOMA	+	+	+	+	+	+	+	+	+	+	+	+	+	+	+	+	+	+	+	+	+	+	+	+	+	+
C-CELL CARCINOMA																										
PARATHYROID ADENOMA, NOS	-	+	+	+	+	+	+	+	+	+	+	+	+	+	+	+	+	+	+	+	+	+	+	+	+	+
PANCREATIC ISLETS ISLET-CELL ADENOMA	+	+	+	+	+	+	+	+	+	+	+	+	+	+	+	+	+	+	+	+	+	+	+	+	+	+
<b>REPRODUCTIVE SYSTEM</b>																										
MAMMARY GLAND	N	N	N	N	N	N	N	N	N	N	N	N	N	N	N	N	N	N	N	N	N	N	N	N	N	N
VAGINA PAPILOMA, NOS	N	N	N	N	N	N	N	N	N	N	N	N	N	N	N	N	N	N	N	N	N	N	N	N	N	N
UTERUS PAPILLARY CARCINOMA	+	+	+	+	+	+	+	+	+	+	+	+	+	+	+	+	+	+	+	+	+	+	+	+	+	+
OVARY	+	+	+	+	+	+	+	+	+	+	+	+	+	+	+	+	+	+	+	+	+	+	+	+	+	+
<b>ALL OTHER SYSTEMS</b>																										
MULTIPLE ORGANS NOS FIBROSARCOMA, METASTATIC	N	N	N	N	N	N	N	N	N	N	N	N	N	N	N	N	N	N	N	N	N	N	N	N	N	N

+: TISSUE EXAMINED MICROSCOPICALLY  
 -: REQUIRED TISSUE NOT EXAMINED MICROSCOPICALLY  
 X: TUMOR INCIDENCE  
 N: NECROPSY, NO AUTOLYSIS, NO MICROSCOPIC EXAMINATION  
 -: NO TISSUE INFORMATION SUBMITTED  
 C: NECROPSY, NO HISTOLOGY DUE TO PROTOCOL  
 A: AUTOLYSIS  
 M: ANIMAL MISSING  
 B: NO NECROPSY PERFORMED

**TABLE D2. FEMALE HAMSTERS: TUMOR PATHOLOGY (CONTINUED) AMOSITE**

ANIMAL NUMBER	7 5	7 6	7 6	7 6	7 7	7 7	7 8	7 8	7 8	7 9	7 9	7 9	8 0	8 0	8 1	8 1	8 1	8 2	8 2	8 3	8 3	8 3	8 3	
WEEKS ON STUDY	0	0	0	0	0	0	0	0	0	0	0	0	0	0	0	0	0	0	0	0	0	0	0	
	5	9	5	9	5	9	5	9	5	9	5	9	5	9	5	9	5	9	5	9	5	9	5	
<b>INTEGUMENTARY SYSTEM</b>																								
SUBCUTANEOUS TISSUE FIBROSARCOMA	+	+	+	+	N	+	+	+	+	+	+	A	+	+	+	+	+	+	+	+	+	+	N	+
<b>RESPIRATORY SYSTEM</b>																								
LUNGS AND BRONCHI FIBROSARCOMA, METASTATIC	+	+	+	+	+	+	+	+	+	+	+	A	+	+	+	+	+	+	+	+	+	+	+	+
TRACHEA	+	+	+	+	+	+	+	+	+	+	+	A	+	+	+	+	+	+	+	+	+	+	+	+
<b>HEMATOPOIETIC SYSTEM</b>																								
BONE MARROW	+	+	+	+	-	+	+	+	+	+	+	A	+	+	+	+	+	-	+	+	+	+	+	+
SPLEEN FIBROSARCOMA, METASTATIC	+	+	+	+	+	+	+	+	+	+	+	A	+	+	+	+	+	+	+	+	+	+	+	+
HEMANGIOMA	+	+	+	+	+	+	+	+	+	+	+	A	+	+	+	+	+	+	+	+	+	+	+	+
HEMANGIOSARCOMA	+	+	+	+	+	+	+	+	+	+	+	A	+	+	+	+	+	+	+	+	+	+	+	+
LYMPH NODES	+	+	+	+	+	+	+	+	+	+	+	A	+	+	+	+	+	+	+	+	+	+	+	+
MALIG.LYMPHOMA, LYMPHOCYTIC TYPE	+	+	+	+	+	+	+	+	+	+	+	A	+	+	+	+	+	+	+	+	+	+	+	+
MALIG.LYMPHOMA, HISTIOCYTIC TYPE	+	+	+	+	+	+	+	+	+	+	+	A	+	+	+	+	+	+	+	+	+	+	+	+
THYMUS	+	-	-	-	+	+	+	+	+	+	+	A	+	+	+	+	+	-	-	-	-	+	+	+
<b>CIRCULATORY SYSTEM</b>																								
HEART	+	+	+	+	+	+	+	+	+	+	+	A	+	+	+	+	+	+	+	+	+	+	+	+
<b>DIGESTIVE SYSTEM</b>																								
SALIVARY GLAND	+	+	+	-	+	+	+	+	+	+	+	A	+	+	+	+	+	+	-	+	-	+	+	+
LIVER	+	+	+	+	+	+	+	+	+	+	+	A	+	+	+	+	+	+	+	+	+	+	+	+
BILE DUCT	+	+	+	+	+	+	+	+	+	+	+	A	+	+	+	+	+	+	+	+	+	+	+	+
GALLBLADDER & COMMON BILE DUCT	N	N	N	N	N	+	N	N	N	+	A	N	N	+	N	N	N	+	N	N	N	N	N	N
PANCREAS	+	+	+	+	+	+	+	+	+	+	+	A	+	+	+	+	+	+	+	+	+	+	+	+
ESOPHAGUS	+	+	+	+	+	+	+	+	+	+	+	A	+	+	+	+	+	+	+	+	+	+	+	+
STOMACH PAPILOMA, NOS	+	+	+	+	+	+	+	+	+	+	+	A	+	+	+	+	+	+	+	+	+	+	+	+
SMALL INTESTINE	+	+	+	+	+	+	+	+	+	+	+	A	+	+	+	+	+	+	+	+	+	+	+	+
LARGE INTESTINE	+	+	+	+	+	+	+	+	+	+	+	A	+	+	+	+	+	+	+	+	+	+	+	+
RECTUM SQUAMOUS CELL PAPILOMA	+	+	+	+	+	+	+	+	+	+	+	A	+	+	+	+	+	+	+	+	+	+	+	+
	X																							
<b>URINARY SYSTEM</b>																								
KIDNEY SARCOMA, NOS, METASTATIC	+	+	+	+	+	+	+	+	+	+	+	A	+	+	+	+	+	+	+	+	+	+	+	+
URINARY BLADDER TRANSITIONAL-CELL PAPILOMA	+	+	+	+	+	+	+	+	+	+	+	A	+	+	+	+	+	+	+	+	+	+	+	+
<b>ENDOCRINE SYSTEM</b>																								
PITUITARY	+	+	+	-	-	+	-	+	+	+	-	A	+	+	-	-	-	-	+	+	-	+	-	-
ADRENAL CORTICAL ADENOMA PHEOCHROMOCYTOMA	+	+	+	+	+	+	+	+	+	+	+	A	+	+	+	-	+	+	+	+	+	+	+	+
THYROID C-CELL ADENOMA C-CELL CARCINOMA	+	+	+	+	+	+	+	+	+	+	+	A	+	+	+	+	+	+	-	+	+	-	-	+
PARATHYROID ADENOMA, NOS	+	+	-	+	-	-	+	-	+	+	+	A	+	+	+	+	-	-	-	-	-	-	-	X
PANCREATIC ISLETS ISLET-CELL ADENOMA	+	+	+	+	-	+	+	-	+	+	+	A	+	+	+	-	+	+	+	+	+	+	+	+
<b>REPRODUCTIVE SYSTEM</b>																								
MAMMARY GLAND	N	N	N	N	N	N	N	N	N	N	N	A	N	N	N	N	N	N	N	N	N	N	N	N
VAGINA PAPILOMA, NOS	N	N	N	N	N	N	N	N	N	N	N	A	N	N	N	N	N	N	N	N	N	N	N	N
	X																							
UTERUS PAPILLARY CARCINOMA	+	+	+	+	+	+	+	+	+	+	+	A	+	+	+	+	+	+	+	+	+	+	+	+
OVARY	+	+	+	+	+	+	+	+	+	+	+	A	+	+	+	+	+	+	+	+	+	+	+	+
<b>ALL OTHER SYSTEMS</b>																								
MULTIPLE ORGANS NOS FIBROSARCOMA, METASTATIC	N	N	N	N	N	N	N	N	N	N	N	A	N	N	N	N	N	N	N	N	N	N	N	N

+: TISSUE EXAMINED MICROSCOPICALLY  
 -: REQUIRED TISSUE NOT EXAMINED MICROSCOPICALLY  
 X: TUMOR INCIDENCE  
 N: NECROPSY, NO AUTOLYSIS, NO MICROSCOPIC EXAMINATION  
 I: NO TISSUE INFORMATION SUBMITTED  
 C: NECROPSY, NO HISTOLOGY DUE TO PROTOCOL  
 A: AUTOLYSIS  
 M: ANIMAL MISSING  
 B: NO NECROPSY PERFORMED

TABLE D2. FEMALE HAMSTERS: TUMOR PATHOLOGY (CONTINUED) AMOSITE

ANIMAL NUMBER	851	852	853	864	865	866	867	868	869	870	871	872	873	874	875	876	877	878	879	880	881	882	883	884	885	886	887	888	889	890	891	892	893	894	895	896	897	898	899	900	TOTAL TISSUES TUMORS							
WEEKS ON STUDY	0	0	0	0	0	0	0	0	0	0	0	0	0	0	0	0	0	0	0	0	0	0	0	0	0	0	0	0	0	0	0	0	0	0	0	0	0	0	0	0	0	0						
<b>INTEGUMENTARY SYSTEM</b>																																																
SUBCUTANEOUS TISSUE FIBROSARCOMA	+	+	+	A	+	+	+	M	A	+	+	+	M	+	+	+	N	+	+	+	+	+	N	+	+	+	+	+	+	+	+	+	+	+	+	+	+	+	+	+	+	+	237M 2					
<b>RESPIRATORY SYSTEM</b>																																																
LUNGS AND BRONCHI FIBROSARCOMA, METASTATIC	+	+	+	A	+	+	+	M	A	+	+	+	M	+	+	+	+	+	+	+	+	+	+	+	+	+	+	+	+	+	+	+	+	+	+	+	+	+	+	+	+	+	+	234 1				
TRACHEA	+	+	+	A	+	+	+	M	A	+	+	+	M	+	+	+	+	+	+	+	+	+	+	+	+	+	+	+	+	+	+	+	+	+	+	+	+	+	+	+	+	+	+	+	233			
<b>HEMATOPOIETIC SYSTEM</b>																																																
BONE MARROW	+	+	+	A	+	+	+	M	A	+	+	+	M	+	+	+	+	+	+	+	+	+	+	+	+	+	+	+	+	+	+	+	+	+	+	+	+	+	+	+	+	+	-	+	229			
SPLEEN FIBROSARCOMA, METASTATIC HEMANGIOMA HEMANGIOSARCOMA	+	+	+	A	+	+	+	M	A	+	+	+	M	+	+	+	+	+	+	+	+	+	+	+	+	+	+	+	+	+	+	+	+	+	+	+	+	+	+	+	+	+	+	+	+	237 1 2		
LYMPH NODES MALIG.LYMPHOMA, LYMPHOCYTIC TYPE MALIG.LYMPHOMA, HISTIOCYTIC TYPE	+	+	+	A	+	+	+	M	A	+	+	+	M	+	+	+	-	+	+	+	+	+	+	+	+	+	+	+	+	+	+	+	+	+	+	+	+	+	+	+	+	+	+	+	236 1 2			
THYMUS	-	-	+	A	+	+	+	M	A	-	-	+	M	+	+	+	+	+	+	+	+	+	+	+	+	+	+	+	+	+	+	+	+	+	+	+	+	+	+	+	+	+	-	-	179			
<b>CIRCULATORY SYSTEM</b>																																																
HEART	+	+	+	A	+	+	+	M	A	+	+	+	M	+	+	+	+	+	+	+	+	+	+	+	+	+	+	+	+	+	+	+	+	+	+	+	+	+	+	+	+	+	+	+	+	234		
<b>DIGESTIVE SYSTEM</b>																																																
SALIVARY GLAND	+	+	+	A	+	+	+	M	A	+	+	+	M	+	+	+	-	+	+	+	-	+	+	+	+	+	+	+	+	+	+	+	+	+	+	+	+	+	+	+	+	+	+	+	+	223		
LIVER	+	+	+	A	+	+	+	M	A	+	+	+	M	+	+	+	+	+	+	+	+	+	+	+	+	+	+	+	+	+	+	+	+	+	+	+	+	+	+	+	+	+	+	+	+	+	234	
BILE DUCT	+	+	+	A	+	+	+	M	A	+	+	+	M	+	+	+	+	+	+	+	+	+	+	+	+	+	+	+	+	+	+	+	+	+	+	+	+	+	+	+	+	+	+	+	+	+	234	
GALLBLADDER & COMMON BILE DUCT	N	N	N	A	N	N	N	M	A	N	N	N	M	N	N	N	N	N	N	N	N	N	N	N	N	N	N	N	N	N	N	N	N	N	N	N	N	N	N	N	N	N	N	N	N	237M		
PANCREAS	+	+	+	A	+	+	+	M	A	+	+	+	M	+	+	+	+	+	+	+	+	+	+	+	+	+	+	+	+	+	+	+	+	+	+	+	+	+	+	+	+	+	+	+	+	+	+	222
ESOPHAGUS	+	+	+	A	+	+	+	M	A	+	+	+	M	+	+	+	-	+	+	+	+	+	+	+	+	+	+	+	+	+	+	+	+	+	+	+	+	+	+	+	+	+	+	+	+	+	233	
STOMACH PAPILOMA, NOS	+	+	+	A	+	+	+	M	A	+	+	+	M	+	+	+	-	+	+	+	+	+	+	+	+	+	+	+	+	+	+	+	+	+	+	+	+	+	+	+	+	+	+	+	+	+	+	236 3
SMALL INTESTINE	+	+	+	A	+	+	+	M	A	+	+	+	M	+	+	+	-	+	+	+	+	+	+	+	+	+	+	+	+	+	+	+	+	+	+	+	+	+	+	+	+	+	+	+	+	+	236	
LARGE INTESTINE	+	+	+	A	+	+	+	M	A	+	+	+	M	+	+	+	-	+	+	+	+	+	+	+	+	+	+	+	+	+	+	+	+	+	+	+	+	+	+	+	+	+	+	+	+	+	+	235
RECTUM SQUAMOUS CELL PAPILOMA	+	+	+	A	+	+	+	M	A	+	+	+	M	+	+	+	N	+	+	+	+	+	+	+	+	+	+	+	+	+	+	+	+	+	+	+	+	+	+	+	+	+	+	+	+	+	+	237M 1
<b>URINARY SYSTEM</b>																																																
KIDNEY SARCOMA, NOS, METASTATIC	+	+	+	A	+	+	+	M	A	+	+	+	M	+	+	+	+	+	+	+	+	+	+	+	+	+	+	+	+	+	+	+	+	+	+	+	+	+	+	+	+	+	+	+	+	+	236 1	
URINARY BLADDER TRANSITIONAL-CELL PAPILOMA	+	+	+	A	+	+	+	M	A	+	+	+	M	+	+	+	+	+	+	X	+	+	+	+	+	+	+	+	+	+	+	+	+	+	+	+	+	+	+	+	+	+	+	+	+	+	225 1	
<b>ENDOCRINE SYSTEM</b>																																																
PITUITARY	+	-	-	A	+	+	+	M	A	-	-	+	M	+	+	+	-	-	+	+	+	-	-	+	+	+	+	+	+	+	+	+	+	+	+	+	+	+	+	+	+	+	+	+	+	149		
ADRENAL CORTICAL ADENOMA PHEOCHROMOCYTOMA	+	+	+	A	+	+	+	M	A	+	+	+	M	+	+	+	+	+	+	+	+	+	+	+	+	+	+	+	+	+	+	+	+	+	+	+	+	+	+	+	+	+	+	+	+	+	234 6 2	
THYROID C-CELL ADENOMA C-CELL CARCINOMA	+	+	+	A	+	+	+	M	A	+	+	+	M	+	+	+	+	+	+	+	+	+	+	+	+	+	+	+	+	+	+	+	+	+	+	+	+	+	+	+	+	+	+	+	+	+	215 4 1	
PARATHYROID ADENOMA, NOS	+	+	+	A	+	+	+	M	A	-	-	+	M	+	+	+	+	+	+	+	+	+	+	+	+	+	+	+	+	+	+	+	+	+	+	+	+	+	+	+	+	+	+	+	+	+	141 1	
PANCREATIC ISLETS ISLET-CELL ADENOMA	+	+	+	A	+	+	+	M	A	+	+	+	M	+	+	+	+	+	+	+	+	+	+	+	+	+	+	+	+	+	+	+	+	+	+	+	+	+	+	+	+	+	+	+	+	+	+	222 2
<b>REPRODUCTIVE SYSTEM</b>																																																
MAMMARY GLAND	N	N	N	A	N	N	N	M	A	N	N	N	M	N	N	N	N	N	N	N	N	N	N	N	N	N	N	N	N	N	N	N	N	N	N	N	N	N	N	N	N	N	N	N	N	237M		
VAGINA PAPILOMA, NOS	N	N	N	A	N	N	N	M	A	N	N	N	M	N	N	N	N	N	N	N	N	N	N	N	N	N	N	N	N	N	N	N	N	N	N	N	N	N	N	N	N	N	N	N	N	N	237M 1	
UTERUS PAPILLARY CARCINOMA	+	+	+	A	+	+	+	M	A	+	+	+	M	+	+	+	+	+	+	+	+	+	+	+	+	+	+	+	+	+	+	+	+	+	+	+	+	+	+	+	+	+	+	+	+	+	+	236 1
OVARY	+	+	+	A	+	+	+	M	A	+	+	+	M	+	+	+	-	+	+	+	+	+	+	+	+	+	+	+	+	+	+	+	+	+	+	+	+	+	+	+	+	+	+	+	+	+	225	
<b>ALL OTHER SYSTEMS</b>																																																
MULTIPLE ORGANS NOS FIBROSARCOMA, METASTATIC	M	N	N	A	N	N	N	M	A	N	N	N	M	N	N	N	N	N	N	N	N	N	N	N	N	N	N	N	N	N	N	N	N	N	N	N	N	N	N	N	N	N	N	N	N	237M 1		

+: TISSUE EXAMINED MICROSCOPICALLY  
 -: REQUIRED TISSUE NOT EXAMINED MICROSCOPICALLY  
 X: TUMOR INCIDENCE  
 N: NECROPSY, NO AUTOLYSIS, NO MICROSCOPIC EXAMINATION  
 : NO TISSUE INFORMATION SUBMITTED  
 -: NECROPSY, NO HISTOLOGY DUE TO PROTOCOL  
 A: AUTOLYSIS  
 M: ANIMAL MISSING  
 B: NO NECROPSY PERFORMED

\* U.S. GOVERNMENT PRINTING OFFICE: 1983-420-910:1