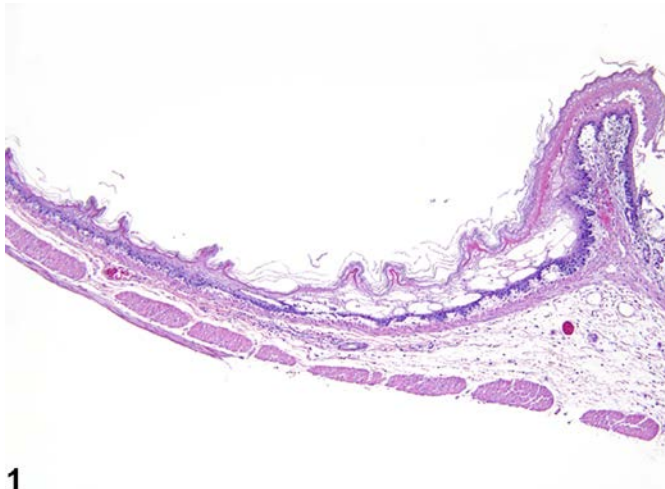
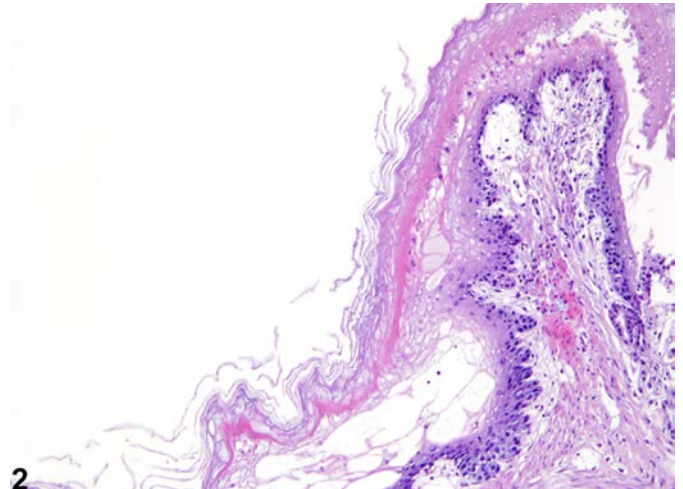


# NTP Nonneoplastic Lesion Atlas

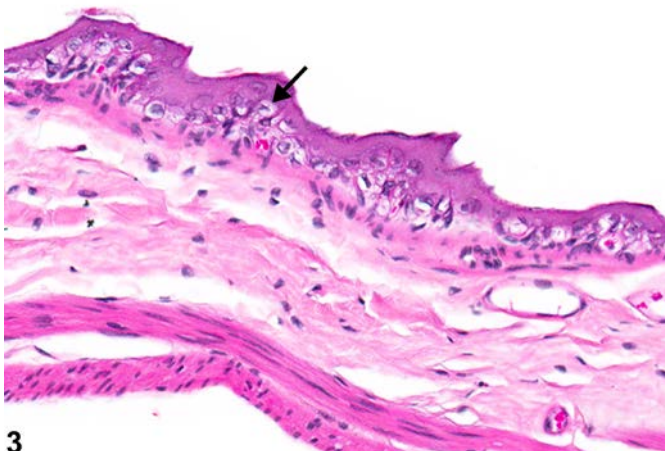
## *Stomach, Forestomach, Epithelium – Degeneration*



1



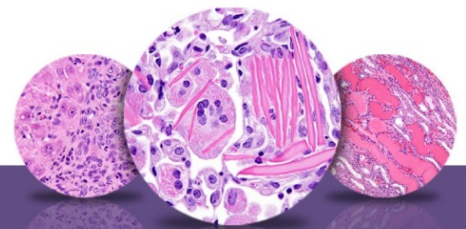
2



3

**Figure Legend:** **Figure 1** Stomach, Forestomach, Epithelium - Degeneration in a female F344/N rat from a subchronic study. There is vacuolation along the basement membrane and below the keratin layer. **Figure 2** Stomach, Forestomach, Epithelium - Degeneration in a female F344/N rat from a subchronic study (higher magnification of Figure 1). **Figure 3** Stomach, Forestomach, Epithelium - Degeneration in a male B6C3F1 mouse from a chronic study. Degeneration characterized by vacuolated cells (arrow) is present.

**Comment:** Cytoplasmic vacuolization, cystic degeneration, and vesicle/bulla formation are forms of degeneration of the squamous epithelium that can occur in any squamous epithelium in the body. Vacuolization of the squamous epithelium is characterized by superficial epithelial cells with a pale



# NTP Nonneoplastic Lesion Atlas

## *Stomach, Forestomach, Epithelium – Degeneration*

staining and vacuolated cytoplasm. Associated mucosa may be ulcerated, and epithelial cells may be degenerate or necrotic. Subjacent tissue is variably infiltrated by inflammatory cells. This change may represent a milder change than necrosis and can be observed in studies involving gavage methods. This lesion may also be due to ulcerogenic or anti-inflammatory compounds.

Cystic degeneration is characterized by vacuolization and ballooning swelling of epithelial cells, resulting in rupture of cell membranes to form irregular spaces in the epithelium, potentially leading to development of vesicles or bulla. Associated mucosa may be ulcerated, and epithelial cells may be degenerate or necrotic. Subjacent tissue is variably infiltrated by inflammatory cells. This change may represent a progression of vacuolar degeneration and can be observed in studies involving gavage methods. This lesion may also be due to ulcerogenic or anti-inflammatory compounds.

Bulla are characterized as a localized collection of fluid in or beneath the epithelial layer. Vesicles are < 1 cm and bulla are  $\geq 1.0$  cm. Bulla can form as the result of acantholysis, epidermal or dermal edema, degeneration of basal cells and keratinocytes, or other processes, such as frictional trauma and burns that cause a lack of cohesion between cells. Bulla can lead to erosions and ulceration.

**Recommendation:** Degeneration should be diagnosed and graded when present as a primary lesion. When degeneration is present as a secondary lesion (e.g., when secondary to inflammation) it should not be diagnosed but should be described in the pathology narrative. If the degeneration is a prominent feature of the lesion but is not considered the primary lesion, it may be diagnosed concurrently the primary lesion if the pathologist feels it is warranted. Grading should be based on the degree of cellular swelling and extent and number of areas affected. If both degeneration and necrosis are present, both should be diagnosed and graded. Inflammation should not be diagnosed separately, unless it is a prominent feature of the lesion.

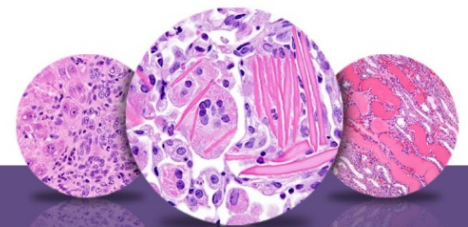
### **References:**

Beattie D. 1977. Effect of drugs on rats exposed to cold-restraint-stress. *J Pharm Pharmacol* 29:748-751.

Abstract: <http://onlinelibrary.wiley.com/doi/10.1111/j.2042-7158.1977.tb11454.x/abstract>

Bertram TA, Markovits JE, Juliana MM. 1996. Non-proliferative lesions of the alimentary canal in rats GI-1. In *Guides for Toxicologic Pathology*. STP/ARP/AFIP, Washington, DC, 1-16.

Full-Text: <https://www.toxpath.org/ssdnc/GINonproliferativeRat.pdf>



# NTP Nonneoplastic Lesion Atlas

## *Stomach, Forestomach, Epithelium – Degeneration*

### References:

- Boyd EM, Cehm CP, Muis LF. 1970. Resistance to starvation in albino rats fed from weaning on diets containing from 0 to 81% of protein as casein. *Growth* 34:99-112.  
Abstract: <http://www.cabdirect.org/abstracts/19711400619.html>
- Hargis AM, Ginn PE. 2007. The integument. In: *Pathologic Basis of Veterinary Disease*, 4th ed (McGavin MD, Zachary JF, ed). Mosby, St Louis, MO, 1107-1261.
- Myers RK, McGavin MD. 2007. Cellular and tissue responses to injury. In: *Pathologic Basis of Veterinary Disease*, 4th ed (McGavin MD, Zachary JF, ed). Mosby, St Louis, MO, 3-62.
- National Toxicology Program. 1986. NTP TR-257. Toxicology and Carcinogenesis Studies of Diglycidyl Resorcinol Ether (Technical Grade) (CAS No. 101-90-6) in F344/N Rats and B6C3F1 Mice (Gavage Studies). NTP, Research Triangle Park, NC.  
Abstract: <http://ntp.niehs.nih.gov/go/8568>
- Puurunen J, Huttunen P, Hirvonen H. 1980. Is ethanol-induced damage of the gastric mucosa a hyperosmotic effect? Comparative studies on the effects of ethanol, some other hyperosmotic solutions, and acetyl-salicylic acid on rat gastric mucosa. *Acta Pharmacol Toxicol (Copenh)* 47:321-327.  
Abstract: <http://onlinelibrary.wiley.com/doi/10.1111/j.1600-0773.1980.tb01567.x/abstract>
- Satoh H, Inada I, Hirata T, Mak Y. 1970. Indomethacin produces gastric antral ulcers in the refed rat. *Gastroenterology* 81:719-725.  
Abstract: <http://www.ncbi.nlm.nih.gov/pubmed/7262516>

### Authors:

Linda H. Kooistra, DVM, PhD, DACVP  
Pathologist  
Charles River Laboratories, Inc.  
Research Triangle Park, NC

Abraham Nyska, DVM, Diplomate ECVP, Fellow IATP  
Expert in Toxicologic Pathology  
Visiting Full Professor of Pathology  
Sackler School of Medicine, Tel Aviv University  
Timrat Israel