



NTP Nonneoplastic Lesion Atlas

Uterus, Cervix – Cyst, Squamous

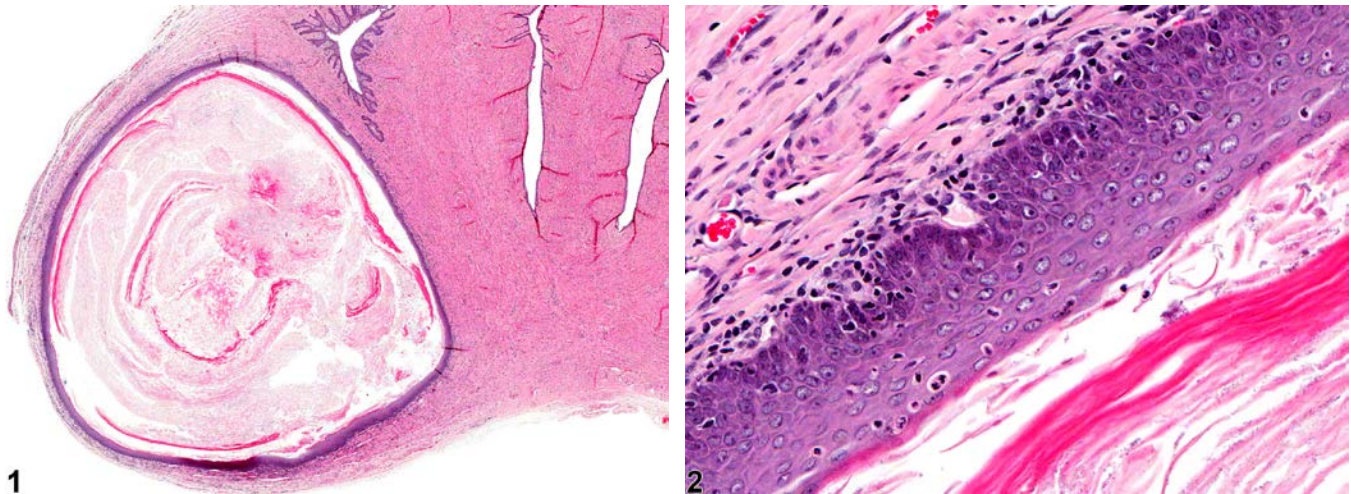


Figure Legend: **Figure 1** Uterus, Cervix - Cyst, Squamous in a female F344/N rat from a chronic study. There is a cyst lined by squamous epithelium adjacent to the uterine cervix. **Figure 2** Uterus, Cervix - Cyst, Squamous in a female F344/N rat from a chronic study (higher magnification of Figure 1). Squamous epithelium lines the cyst, and keratin is evident in the lumen of the cyst.

Comment: Squamous epithelial cysts (Figure 1 and Figure 2) are occasionally seen in the cervix and less frequently in the vagina of rats. They resemble epidermal cysts seen in the skin and have a wall of stratified squamous epithelium, and they may have a central lumen of keratin and variable numbers of inflammatory cells. These cysts are sometimes bilateral. These cysts must be distinguished from focal necrosis or abscess, neither of which would be lined by epithelium. They may arise from vestigial structures. Squamous cysts must be differentiated from squamous metaplasia of the uterus, which is observed within the body away from the cervix or in the horns of the uterus.

Recommendation: Squamous cysts occurring in the cervix should be diagnosed as Uterus, Cervix – Cyst, Squamous (in NTP studies, the cervix is classified as a subsite of the uterus). Cysts need not be graded unless grading would help characterize a treatment effect. Inflammatory changes secondary to the cyst should not be diagnosed separately unless warranted by severity.

References:

Greaves P. 2012. Female genital tract. In: *Histopathology of Preclinical Toxicity Studies: Interpretation and Relevance in Drug Safety Evaluation*, 4th ed. Elsevier, Amsterdam, 667-724.



NTP Nonneoplastic Lesion Atlas

Uterus, Cervix – Cyst, Squamous

References:

Leininger JR, Jokinen MP. 1990. Oviduct, uterus and vagina. In: Pathology of the Fischer Rat (Boorman GA, Eustis SL, Elwell MR, Montgomery CA, MacKenzie WF, eds). Academic Press, San Diego, CA, 443-459.

National Toxicology Program. 1994. NTP TR-433. Toxicology and Carcinogenesis Studies of Tricresyl Phosphate (CAS No. 1330-78-5) in F344/N Rats and B6C3F₁ Mice (Gavage and Feed Studies). NTP, Research Triangle Park, NC.

Abstract: <http://ntp.niehs.nih.gov/go/6010>

Yoshitomi K. 1990. Cystic dilatation of the vaginal fornix in aged female Crj:F344/Du rats. Vet Pathol 27:282-284.

Authors:

Gabrielle Willson, BVMS, DipRCPath, FRCPath, MRCVS
Senior Pathologist
Experimental Pathology Laboratories, Inc.
Research Triangle Park, NC

Karen Y. Cimon, DVM, MS
Senior Pathologist
Experimental Pathology Laboratories, Inc.
Research Triangle Park, NC