

NTP Nonneoplastic Lesion Atlas

Liver – Intrahepatocellular erythrocytes

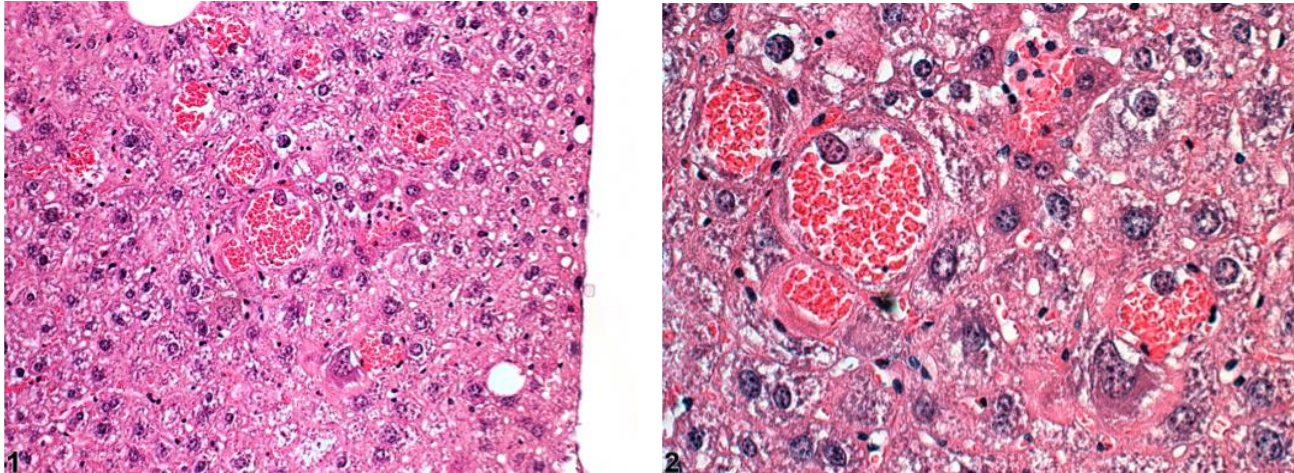
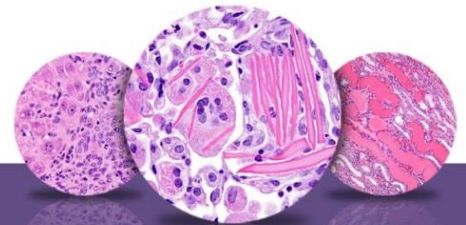


Figure Legend: **Figure 1** Intrahepatocellular erythrocytes in a B6C3F1 mouse from a chronic study. **Figure 2** Intrahepatocellular erythrocytes in a B6C3F1 mouse from a chronic study (higher magnification of Figure 1).

Comment: Intrahepatocellular erythrocytes are uncommon and may be seen as a spontaneous change in aging mice. However, in some NTP studies, this change appears to have been exacerbated by treatment. At low magnification, it may be confused with angiectasis; at higher magnification, enlarged hepatocytes are filled and expanded by numerous erythrocytes. Speculation that this change occurs by erythrophagocytosis or emperipolesis has not been confirmed by ultrastructural studies.

Recommendation: Intrahepatocellular erythrocytes should be documented whenever present, and the pathology narrative should include a description of the extent of the change. Any associated degenerative or other changes in the hepatic parenchyma should be diagnosed separately if warranted by the severity of these lesions; otherwise, they should be mentioned in the pathology narrative.



NTP Nonneoplastic Lesion Atlas

Liver – Intrahepatocellular erythrocytes

References:

Barni S, Bernocchi G. 1991. Internalization of erythrocytes into liver parenchymal cells in naturally hibernating frogs (*Rana esculenta* L.). *J Exp Zool* 258:143–150.

Abstract: <http://www.ncbi.nlm.nih.gov/pubmed/2022945>

Harada T, Enomoto A, Boorman GA, Maronpot RR. 1999. Liver and gallbladder. In: *Pathology of the Mouse: Reference and Atlas* (Maronpot RR, Boorman GA, Gaul BW, eds). Cache River Press, Vienna, IL, 119–183.

Abstract: <http://www.cacheriverpress.com/books/pathmouse.htm>

Lee KP. 1983. Peliosis hepatitis-like lesion in aging rats. *Vet Pathol* 20:410–423.

Abstract: <http://www.ncbi.nlm.nih.gov/pubmed/6623845>

Thoolen B, Maronpot RR, Harada T, Nyska A, Rousseaux C, Nolte T, Malarkey D, Kaufmann W, Kutter K, Deschl U, Nakae D, Gregson R, Winlove M, Brix A, Singl B, Belpoggi F, Ward JM. 2010. Hepatobiliary lesion nomenclature and diagnostic criteria for lesions in rats and mice (INHAND). *Toxicol Pathol* 38:5S–81S.

Full-Text: http://tpx.sagepub.com/content/38/7_suppl/5S.full

Author:

Robert R. Maronpot, DVM, MS, MPH, DACVP, DABT, FIATP
Senior Pathologist
Experimental Pathology Laboratories, Inc.
Research Triangle Park, NC