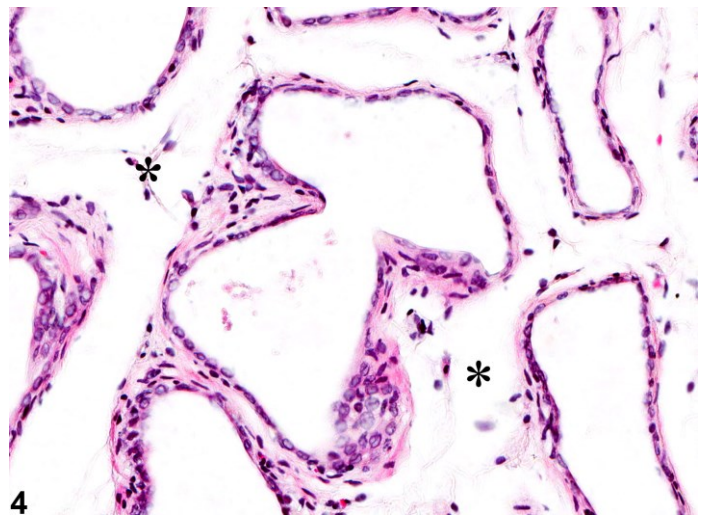
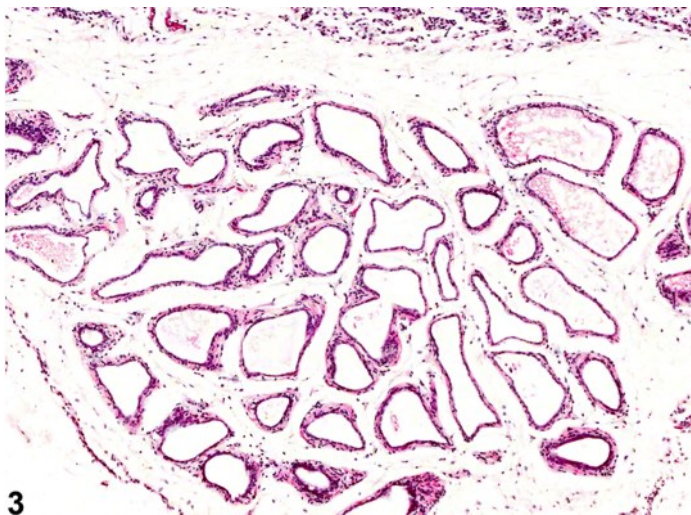
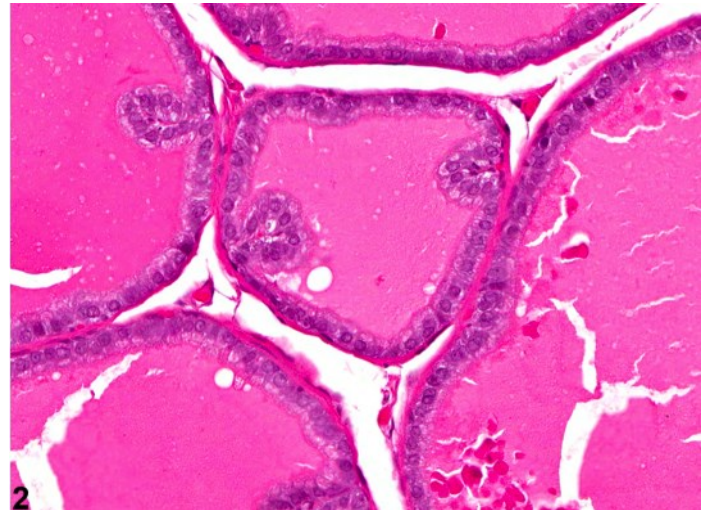
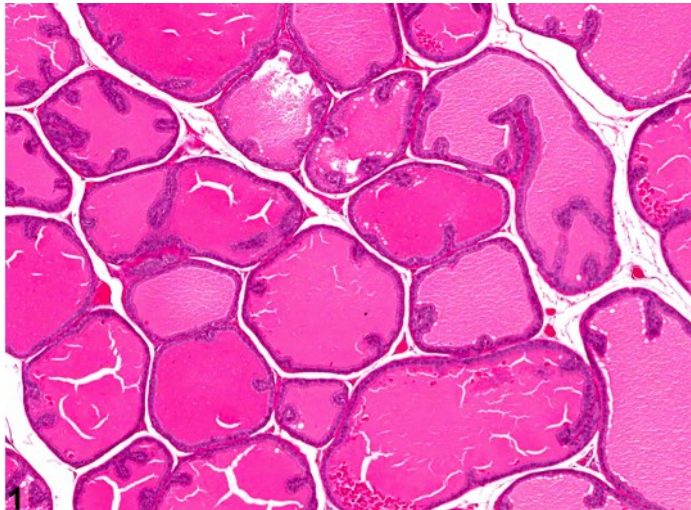
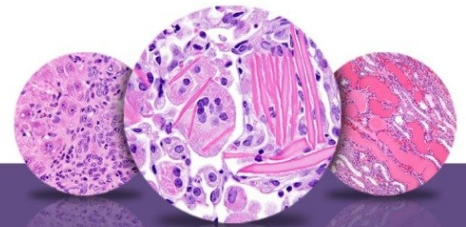


# NTP Nonneoplastic Lesion Atlas

## Prostate, Acinus – Atrophy



**Figure Legend:** **Figure 1** Prostate - Normal. Normal dorsolateral prostate for comparison with Figure 3 in a male F344/N rat from a subchronic study. **Figure 2** Prostate - Normal. Higher magnification of Figure 1. Normal dorsolateral prostate for comparison with Figure 4 in a male F344/N rat from a subchronic study. **Figure 3** Prostate, Acinus - Atrophy. Decreased acinar size and absence of secretion are evident in this prostate in a male F344/N rat from a subchronic study. **Figure 4** Prostate, Acinus - Atrophy. Higher magnification of Figure 3. Acinar epithelium is markedly flattened (atrophic), there is absence of luminal secretion, and asterisks indicate increased stromal prominence in a male F344/N rat from a subchronic study.



## NTP Nonneoplastic Lesion Atlas

### *Prostate, Acinus – Atrophy*

**Comment:** Prostatic atrophy represents glandular shrinkage and is microscopically characterized by reduction in the size of acini, attenuation of lining epithelial cells, scanty secretory material, and increased stromal prominence (asterisks, Figure 4). Figure 1 and Figure 2 represent the dorsolateral lobe of normal prostate for comparison. In general, atrophy involves all lobes of the prostate. Inhibition of gonadal steroid and pituitary hormones results in atrophy of testes and accessory sex organs, including prostate. Inhibitors of 5 $\alpha$ -reductases, enzymes involved in intraprostatic conversion of testosterone to its biologically active form dihydrotestosterone, such as finasteride and epristeride, are known to induce atrophy of prostate. Similarly, antiandrogenic substances such as hydroxyflutamide cause prostatic atrophy.

Estrogens decrease the volume of the glandular epithelium and increase the fibromuscular stroma in both ventral prostate and seminal vesicle. Deficiency of the Egr family of zinc finger transcription factors such as Egr4 and Egr1, as in *Egr4-Egr1* double-mutant mice, leads to atrophy of prostate, testis, epididymis, and seminal vesicle. Spontaneous prostatic atrophy is an age-related lesion.

**Recommendation:** Prostatic atrophy should be diagnosed and graded, and treatment-associated exacerbation should be indicated in the pathology narrative. The affected lobe(s) should be identified if possible and indicated in the tissue identification (e.g., prostate, dorsolateral lobe, acinus - atrophy, severe). When known, bilateral involvement should be indicated and the severity grade determined by the more severely affected lobe.

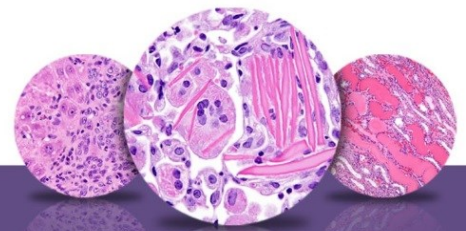
#### **References:**

Boorman GA, Elwell MR, Mitsumori K. 1990. Male accessory sex glands, penis, and scrotum. In: Pathology of the Fischer Rat: Reference and Atlas (Boorman GA, Eustis SL, Elwell MR, Montgomery CA, MacKenzie WF, eds). Academic Press, San Diego, 419-428.

Abstract: <http://www.ncbi.nlm.nih.gov/nlmcatalog/9002563>

Bosland MC. 1992. Lesions in the male accessory glands and penis. In: Pathobiology of the Aging Rat, Vol 1 (Mohr U, Dungworth DL, Capen CC, eds). ILSI Press, Washington, DC, 443-467.

Abstract: <http://catalog.hathitrust.org/Record/008994685>



# NTP Nonneoplastic Lesion Atlas

## *Prostate, Acinus – Atrophy*

### References:

Creasy D, Bube A, de Rijk E, Kandori H, Kuwahara M, Masson R, Nolte T, Reams R, Regan K, Rehm S, Rogerson P, Whitney K. 2012. Proliferative and nonproliferative lesions of the rat and mouse male reproductive system. *Toxicol Pathol* 40:40S-121S.

Abstract: <http://www.ncbi.nlm.nih.gov/pubmed/22949412>

Gao W, Kearbey JD, Nair VA, Chung K, Parlow AF, Miller DD, Dalton JT. 2004. Comparison of the pharmacological effects of a novel selective androgen receptor modulator, the 5 $\alpha$ -reductase inhibitor finasteride, and the antiandrogen hydroxyflutamide in intact rats: New approach for benign prostate hyperplasia. *Endocrinology* 145:5420-5428.

Full Text: <http://www.ncbi.nlm.nih.gov/pmc/articles/PMC2098692/>

Gayton F, Bellido C, Aguilar R, Lucena MC. 1986. Morphometric analysis of the rat ventral prostate and seminal vesicles during prepubertal development: Effects of neonatal treatment with estrogen. *Biol Reprod* 35:219-225.

Abstract: <http://www.ncbi.nlm.nih.gov/pubmed/3741952>

Gordon LR, Majka JA, Boorman GA. 1996. Spontaneous nonneoplastic and neoplastic lesions and experimentally induced neoplasms of the testes and accessory sex glands. In: *Pathobiology of the Aging Mouse, Vol 1* (Mohr U, Dungworth DL, Capen CC, Carlton WW, Sundberg JP, Ward JM, eds). ILSI Press, Washington, DC, 421-441.

Abstract: <http://catalog.hathitrust.org/Record/008994685>

Greaves P. 2007. Male genital tract. In: *Histopathology of Preclinical Toxicity Studies: Interpretation and Relevance in Drug Safety Evaluation*. 3rd ed. Academic Press, San Diego, 661-716.

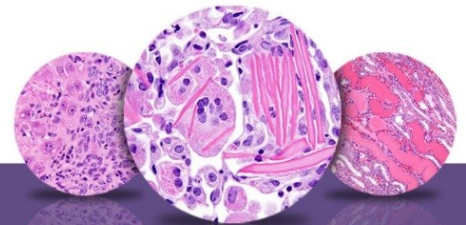
Abstract: <http://www.sciencedirect.com/science/book/9780444527714>

Quin LH, Wang XL, Tu ZH. 2001. Atrophy and apoptosis in ventral prostate of rats induced by 5 alpha-reductase inhibitor epristeride. *Acta Pharmacol Sin* 22:399-404.

Abstract: <http://www.ncbi.nlm.nih.gov/pubmed/11743885>

Rittmaster RS, Manning AP, Wright AS, Thomas LN, Whitefield S, Norman RW, Lazier CB, Rowden G. 1995. Evidence for atrophy and apoptosis in the ventral prostate of rats given the 5alpha-reductase inhibitor finasteride. *Endocrinology* 136:741-748.

Abstract: <http://www.ncbi.nlm.nih.gov/pubmed/7835306>



# NTP Nonneoplastic Lesion Atlas

## *Prostate, Acinus – Atrophy*

### **Authors:**

Dianne M. Creasy, PhD, Dip RCPATH, FRCPath  
Dianne Creasy Consulting LLC  
Pipersville, PA

Robert R. Maronpot, DVM, MS, MPH, DACVP, DABT, FIATP  
Senior Pathologist  
Experimental Pathology Laboratories, Inc.  
Research Triangle Park, NC

Dipak K. Giri, DVM, PhD, DACVP  
Toxicologic Pathologist  
Integrated Laboratory Systems, Inc.  
Research Triangle Park, NC