

NTP Nonneoplastic Lesion Atlas

Testis, Seminiferous tubule – Retention, Spermatid

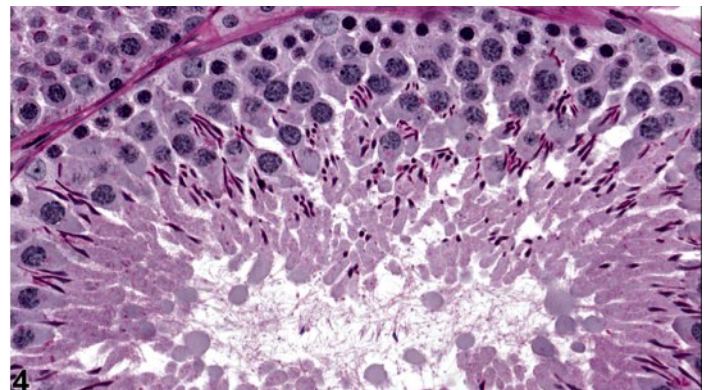
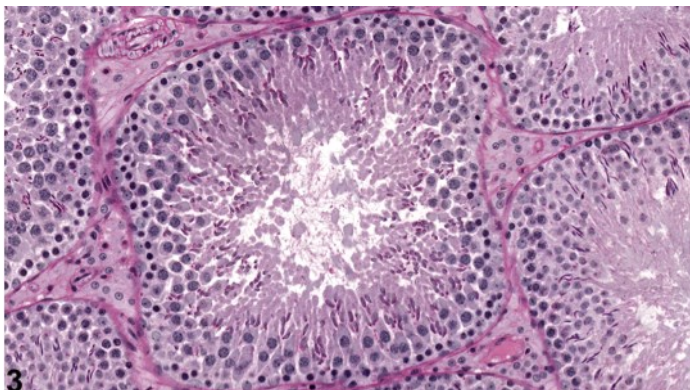
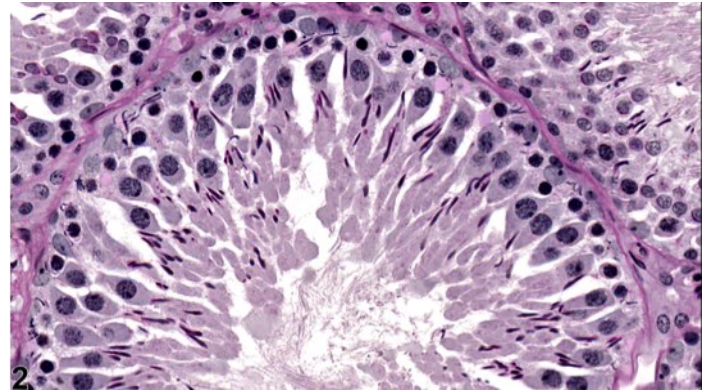
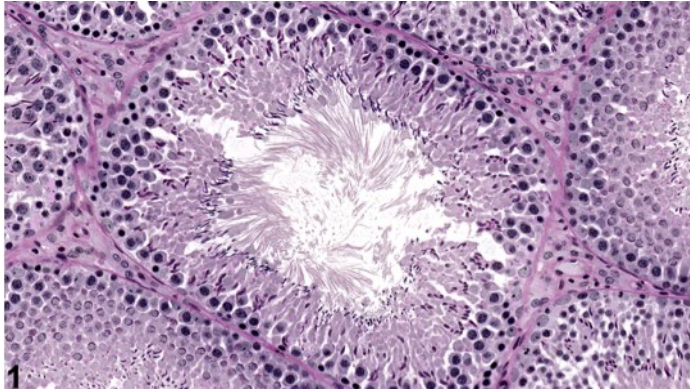
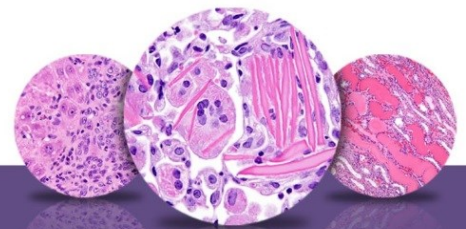


Figure Legend: **Figure 1** Testis, Seminiferous tubule - Retention, Spermatid in a male Sprague-Dawley rat. Retention of elongated spermatids is present in a stage XI seminiferous tubule. (Photograph courtesy of Dr. D. Creasy.) **Figure 2** Testis, Seminiferous tubule - Retention, Spermatid in a male Sprague-Dawley rat. Retention of elongated spermatids in the basal region of a stage XII seminiferous tubule. (Photograph courtesy of Dr. D. Creasy.) **Figure 3** Testis - Normal in a male Sprague-Dawley rat. Control stage XI tubule for comparison with Figure 1. (Photograph courtesy of Dr. D. Creasy.) **Figure 4** Testis - Normal in a male Sprague-Dawley rat. Control stage XII tubule for comparison with Figure 2. (Photograph courtesy of Dr. D. Creasy.)

Comment: Spermiation (the release of fully mature spermatids into the tubular lumen) normally occurs during stage VIII of the spermatogenic cycle in rats and mice. Numerous toxicants have been shown to disrupt spermiation, resulting in the continued presence of the mature spermatids (step 19 spermatids in the rat, step 17 in the mouse) at the luminal surface of stage IX-XI tubules (Figure 1 and Figure 2). The retained spermatids are then pulled down into the basal Sertoli cell cytoplasm, where they are



NTP Nonneoplastic Lesion Atlas

Testis, Seminiferous tubule – Retention, Spermatid

phagocytized. Spermatid retention has been described following exposure to a number of chemicals, including boric acid, 2,5-hexanedione, and dibromoacetic acid. Spermiation is testosterone dependant, so spermatid retention also occurs with decreased intratesticular levels of testosterone. Although subtle, this finding is important to recognize and record since it usually results in reduced epididymal sperm count, sperm abnormalities, and potential effects on fertility. A few retained spermatids can often be seen at the lumen of stage IX tubules or phagocytized at the base of stage XII tubules, but they are generally very few in number and restricted to one or two tubules.

Recommendation: Spermatid retention should be diagnosed and graded and should be discussed in the pathology narrative if the incidence and/or severity appears to be related to chemical administration. Bilateral involvement should be diagnosed when present.

References:

Bryant BH, Yamasak I H, Sandrof MA, Boekelheide K. 2008. Spermatid head retention as a marker of 2,5-hexanedione-induced testicular toxicity in the rat. *Toxicol Pathol* 36:552-559.

Abstract: <http://www.ncbi.nlm.nih.gov/pubmed/18467684>

Creasy DM. 2001. Pathogenesis of male reproductive toxicity. *Toxicol Pathol* 29:64-76.

Full-Text: <http://tpx.sagepub.com/content/29/1/64.full.pdf>

Creasy D, Bube A, de Rijk E, Kandori H, Kuwahara M, Masson R, Nolte T, Reams R, Regan K, Rehm S, Rogerson P, Whitney K. 2012. Proliferative and nonproliferative lesions of the rat and mouse male reproductive system. *Toxicol Pathol* 40:40S-121S.

Abstract: <http://www.ncbi.nlm.nih.gov/pubmed/22949412>

Ku WW, Chapin RE, Wine RN, Gladen BC. 1993. Testicular toxicity of boric acid BA: Relationship of dose to lesion development and recovery in the F344 rat. *Reprod Toxicol* 7:305-319.

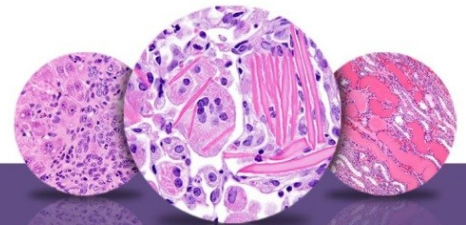
Abstract: <http://www.ncbi.nlm.nih.gov/pubmed/8400621>

Linder RE, Klinefelter GR, Strader LF, Suarez JD, Roberts NL, Dyer CJ. 1994. Spermatotoxicity of dibromoacetic acid in rats after 14 daily exposures. *Reprod Toxicol* 8:251-259.

Abstract: <http://www.ncbi.nlm.nih.gov/pubmed/8075514>

Linder RE, Klinefelter GR, Strader LF, Veermachaneni DNR, Roberts NL, Suarez JD. 1997. Histopathologic changes in testes of rats exposed to dibromoacetic acid. *Reprod Toxicol* 11:47-56.

Abstract: <http://www.ncbi.nlm.nih.gov/pubmed/9138633>



NTP Nonneoplastic Lesion Atlas

Testis, Seminiferous tubule – Retention, Spermatid

Authors:

Dianne M. Creasy, PhD, Dip RCPATH, FRCPath
Dianne Creasy Consulting LLC
Pipersville, PA

Robert R. Maronpot, DVM, MS, MPH, DACVP, DABT, FIATP
Senior Pathologist
Experimental Pathology Laboratories, Inc.
Research Triangle Park, NC

Dipak K. Giri, DVM, PhD, DACVP
Toxicologic Pathologist
Integrated Laboratory Systems, Inc.
Research Triangle Park, NC