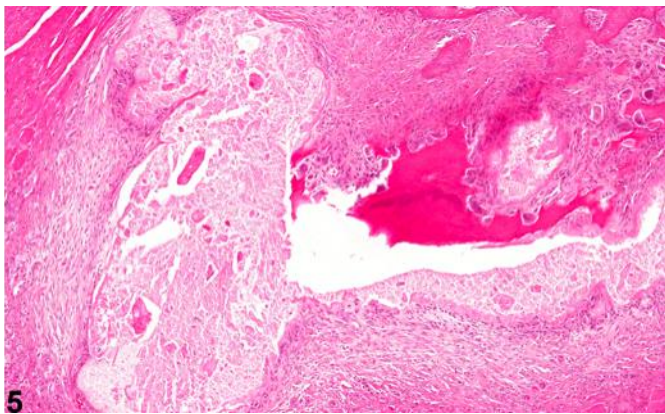
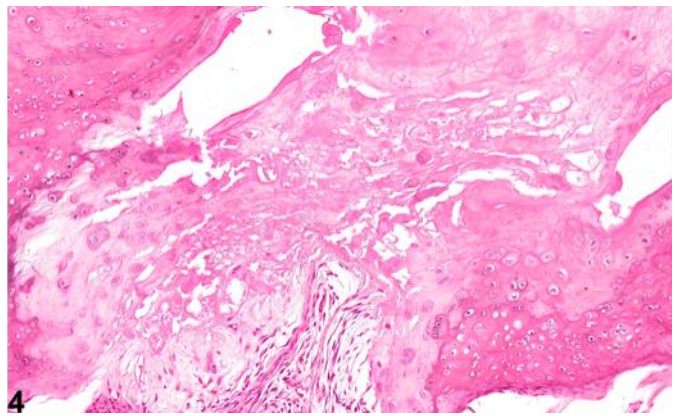
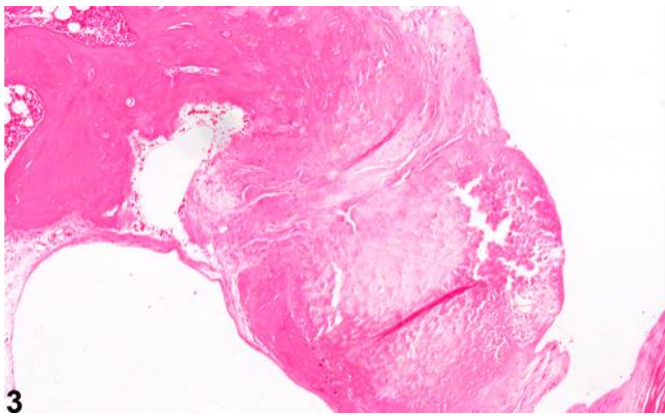
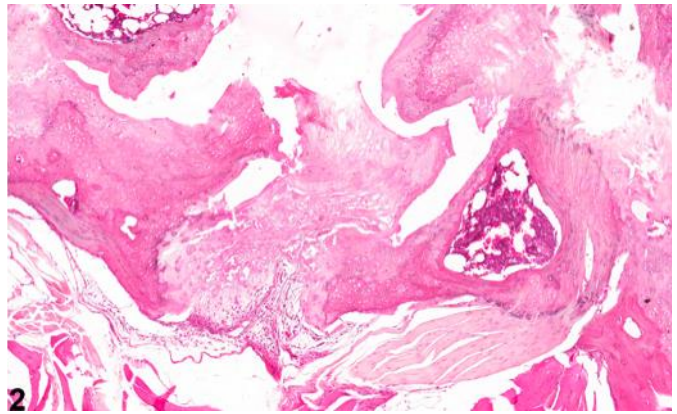
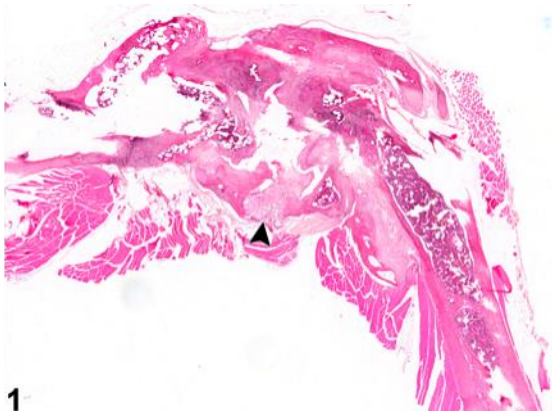
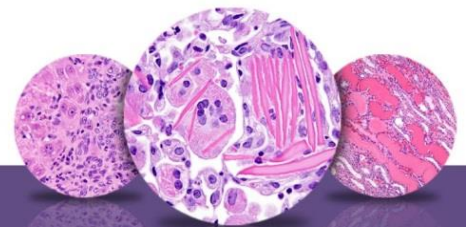


NTP Nonneoplastic Lesion Atlas

Bone – Necrosis





NTP Nonneoplastic Lesion Atlas

Bone – Necrosis

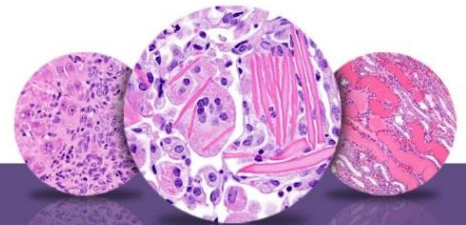
Figure Legend: **Figure 1** Bone, Femur - Necrosis in a male B6C3F1/N mouse from a chronic study. This section of a femur demonstrates focal necrosis (arrowhead) associated with marked joint degeneration. **Figure 2** Bone, Femur - Necrosis in a male B6C3F1/N mouse from a chronic study (higher magnification of Figure 1). This section of femur illustrates focal necrosis associated with marked joint degeneration. **Figure 3** Bone, Femur - Necrosis in a male F344/N rat from a chronic study. Focal necrosis is associated with marked joint degeneration in a section of femur. **Figure 4** Bone, Femur - Necrosis in a male B6C3F1/N mouse from a chronic study. In this section of femur, focal necrosis is associated with marked joint degeneration. **Figure 5** Bone, Vertebra - Necrosis in a male F344/N rat from a chronic study. This section of a vertebra demonstrates marked necrosis characterized by loss of bony architecture, fragmentation, and debris associated with significant fibroplasia and bony remodeling.

Comment: Necrosis of bone (Figure 1, Figure 2, Figure 3, Figure 4, and Figure 5) can be characterized by disruption of normal architecture and fragmentation of bony trabeculae in the medullary cavity, loss of osteoblasts from bone surfaces, or loss of osteocytes from lacunae. There is often marrow necrosis and hemorrhage. Focal necrosis may be isolated in sequestra or replaced by fibrous connective tissue. Necrosis may result from a variety of etiologies, including vascular compromise, inflammation, trauma, or neoplasia. Idiopathic necrosis of bone occasionally occurs in mice, particularly at the epiphysis or metaphysis of the distal femur and proximal tibia; vascular compromise has been suspected in some of these cases.

Recommendation: Necrosis of the bone should be diagnosed and given a severity grade. If the cause of the necrosis can be discerned, it should be discussed in the narrative. When necrosis occurs as a secondary component of another process, it should not be diagnosed but should be described in the narrative. Lesions that are secondary to necrosis, such as inflammation or hemorrhage, should not be diagnosed separately unless warranted by severity but should be noted in the pathology narrative.

References:

Leininger JR, Riley MGI. 1990. Bones, joints, and synovia. In: Pathology of the Fischer Rat: Reference and Atlas (Boorman G, Eustis SL, Elwell MR, Montgomery CA, MacKenzie WF, eds). Academic Press, San Diego, 209-226.



NTP Nonneoplastic Lesion Atlas

Bone – Necrosis

References:

Long PH, Leininger JR. 1999. Bones, joints, and synovia. In: Pathology of the Mouse (Maronpot R, Boorman G, Gaul BW, eds). Cache River Press, St Louis, 645-678.

Yamasaki K. 1993. Morphologic studies on the bone and cartilage of laboratory animals. *Exp Anim* 42:11-21.

Authors:

Mark J. Hoenerhoff, DVM, PhD, DACVP
Associate Professor
In Vivo Animal Core, Unit for Laboratory Animal Medicine
University of Michigan Medical School
Ann Arbor, MI

Amy Brix, DVM, PhD, DACVP
Senior Pathologist
Experimental Pathology Laboratories, Inc.
Research Triangle Park, NC