

NTP Nonneoplastic Lesion Atlas

Eye, Optic Nerve – Degeneration

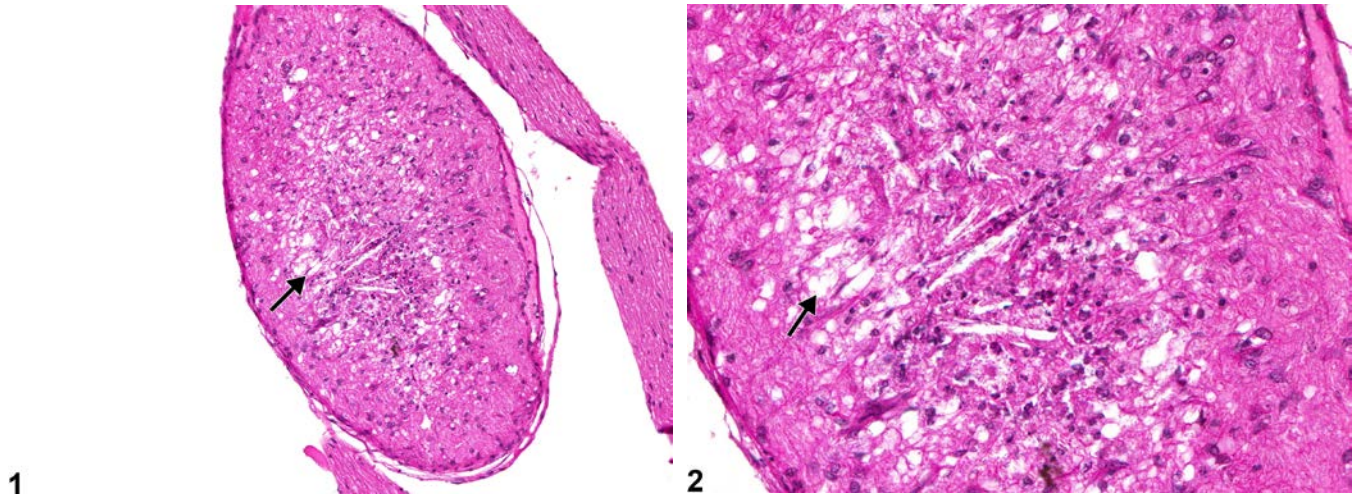
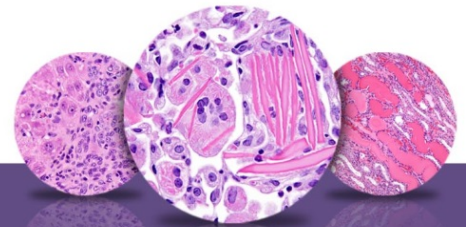


Figure Legend: **Figure 1** Eye, Optic nerve - Degeneration in a female B6C3F1 mouse from a chronic study. Optic nerve degeneration (arrow) is characterized by scattered clear vacuoles. **Figure 2** Eye, Optic nerve - Degeneration in a female B6C3F1 mouse from a chronic study (higher magnification of Figure 1). There are scattered clear vacuoles (arrow) in the optic nerve.

Comment: Optic nerve degeneration can result from various causes, including increased intraocular pressure, compromised vascular supply, and physical trauma (e.g., from retro-orbital bleeding procedures). Since the optic nerve is composed of the axons of retinal ganglion cells, primary lesions in the retina (especially those affecting the ganglion cell and nerve fiber layers) frequently result in concurrent optic nerve pathology, including degeneration. Since the optic nerve is an extracranial white matter tract of the brain, optic nerve degeneration can also be a “descending” change secondary to lesions in the brain. Although the extent can vary with rodent strain, optic nerve axonal degeneration and loss can also be an age-related incidental change in rats and mice. Optic nerve degeneration of uncertain etiology has also been reported as a spontaneous change in adult rats.

Optic nerve degeneration can be characterized by scattered clear vacuoles (as in Figure 1 and Figure 2), which often contain swollen, pale eosinophilic fragmented axons and/or myelin debris. In more chronic cases, there can be decreased numbers of axons, decreased diameter of the remaining axons, and pial septa thickening. The loss of axons may lead to decreased overall diameter of the nerve. Variable glial cell proliferation and/or macrophage infiltration may occur concurrently.



NTP Nonneoplastic Lesion Atlas

Eye, Optic Nerve – Degeneration

Recommendation: Optic nerve degeneration should be diagnosed and assigned a severity grade. The presence of optic nerve degeneration should prompt careful examination of the retina (especially the ganglion cell and nerve fiber layers) for concurrent pathology. Associated lesions (e.g., inflammation) should be diagnosed separately.

References:

Cepurna WO, Kayton RJ, Johnson EC, Morrison JC. 2005. Age related optic nerve axonal loss in adult brown Norway rats. *Exp Eye Res* 80:877-884.

Abstract: <http://www.ncbi.nlm.nih.gov/pubmed/15939045>

John SW, Smith RS, Savinova OV, Hawes NL, Chang B, Turnbull D, Davisson M, Roderick TH, Heckenlively JR. 1998. Essential iris atrophy, pigment dispersion, and glaucoma in DBA/2J mice. *Invest Ophthalmol Vis Sci* 39:951-962.

Abstract: <http://www.iovs.org/content/39/6/951.short>

Kiernan JA. 1985. Axonal and vascular changes following injury to the rat's optic nerve. *J Anat* 141:139-154.

Full-text: <http://www.ncbi.nlm.nih.gov/pmc/articles/PMC1166396/pdf/janat00192-0143.pdf>

Kitaoka Y, Kitaoka Y, Kwong JMK, Ross-Cisneros FN, Wang J, Tsai RK, Sadun AA, Lam TT. 2006. TNF- α -induced optic nerve degeneration and nuclear factor- κ B. *Invest Ophthalmol Vis Sci* 47:1448-1457.

Full-text: <http://www.iovs.org/content/47/4/1448.full>

Lee EW, Render JA, Garner CD, Brady AN, Li LC. 1990. Unilateral degeneration of retina and optic nerve in Fischer-344 rats. *Vet Pathol* 27:439-444.

Abstract: <http://vet.sagepub.com/content/27/6/439.short>

Levkovitch-Verbin H. 2004. Animal models of optic nerve diseases. *Eye* 18:1066-1074.

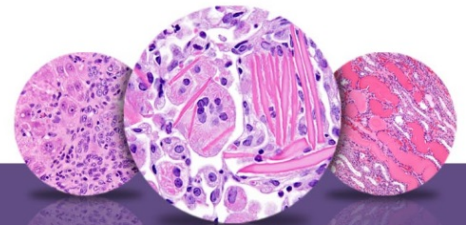
Full-text: <http://www.nature.com/eye/journal/v18/n11/full/6701576a.html>

Mabuchi, F, Aihara M, Mackey MR, Lindsey JD, Weireb RN. 2003. Optic nerve damage in experimental mouse ocular hypertension. *Invest Ophthalmol Vis Sci* 44:4321-4330.

Full-text: <http://www.iovs.org/content/44/10/4321.full>

Maeda K, Sawada A, Matsuhara M, Nakai Y, Hara A, Yamamoto T. 2004. A novel neuroprotectant against retinal ganglion cell damage in a glaucoma model and an optic nerve crush model in the rat. *Invest Ophthalmol Vis Res* 45:851-855.

Full-text: <http://www.iovs.org/content/45/3/851.full>



NTP Nonneoplastic Lesion Atlas

Eye, Optic Nerve – Degeneration

References:

National Toxicology Program. 2011. NTP TR-567. Toxicology and Carcinogenesis Studies of Ginseng (CAS No. 50647-08-0) in F344/N Rats and B6C3F1 Mice (Gavage Studies). NTP, Research Triangle Park, NC.

Abstract: <http://ntp.niehs.nih.gov/go/43815>

Ramos M, Reilly CM, Bolon B. 2011. Toxicological pathology of the retina and optic nerve. In: Fundamental Neuropathology for Pathologists and Toxicologists (Bolon B, Butt MT, eds). Wiley, Hoboken, NJ, 385-412.

Abstract: <http://onlinelibrary.wiley.com/doi/10.1002/9780470939956.ch24/summary>

Schlamp CL, Li Y, Dietz JA, Janssen KT, Nickells RW. 2006. Progressive ganglion cell loss and optic nerve degeneration in DBA/2J mice is variable and asymmetric. BMC Neurosci 7:66-80.

Full-text: <http://www.ncbi.nlm.nih.gov/pmc/articles/PMC1621073/>

Smith RS, John SWM, Sundberg JP. 2002. Optic nerve and orbit. In: Systematic Evaluation of the Mouse Eye: Anatomy, Pathology, and Biomethods (Smith RS, John SWM, Nishina PM, Sundberg JP, eds). CRC Press, Boca Raton, FL, 227-247.

Author:

Margarita M. Gruebbel, DVM, PhD, DACVP
Senior Pathologist
Experimental Pathology Laboratories, Inc.
Research Triangle Park, NC