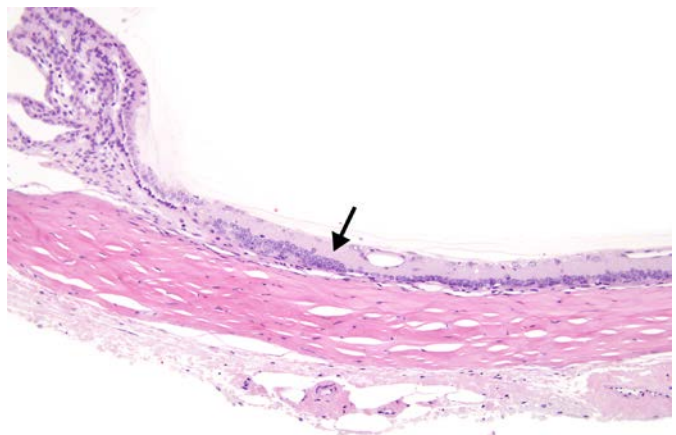
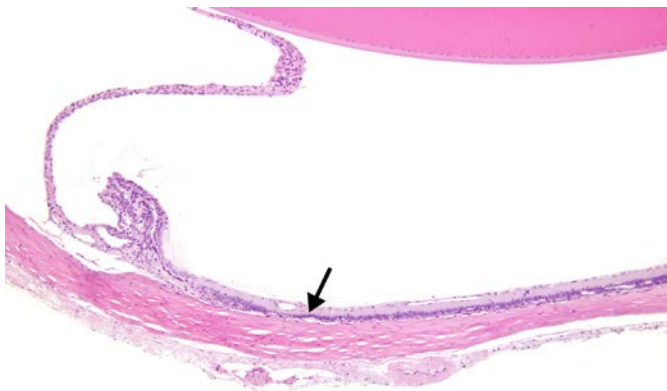
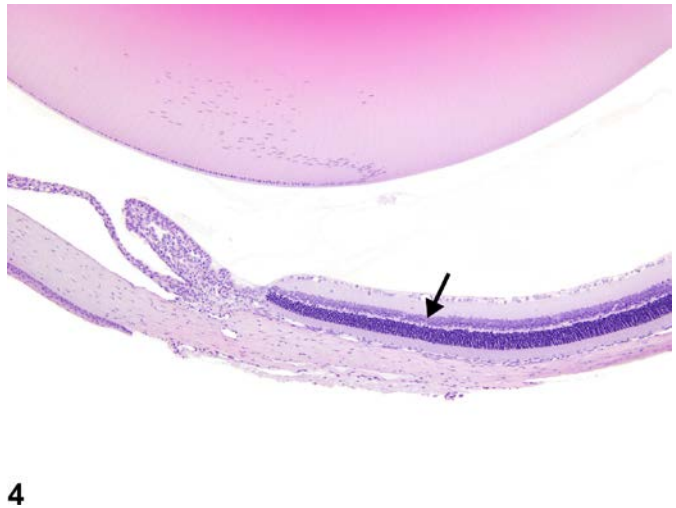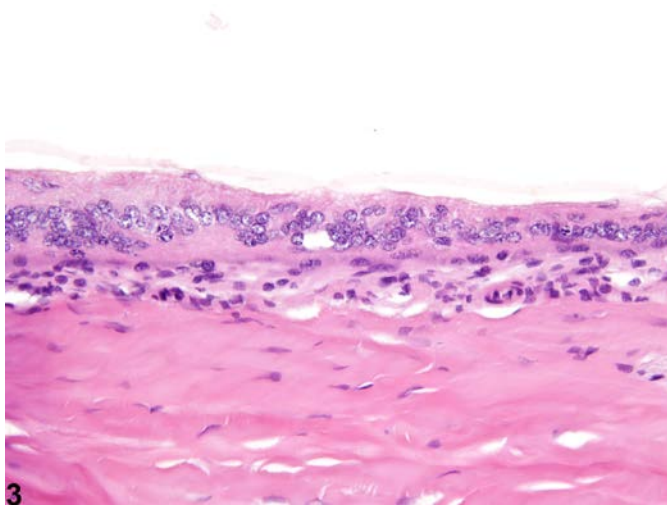
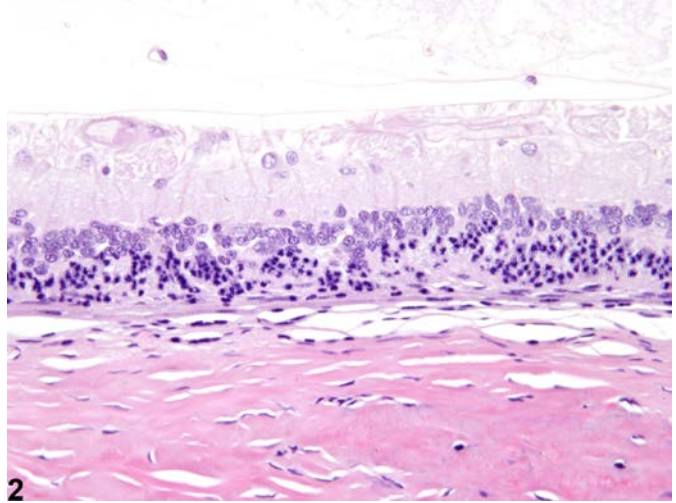
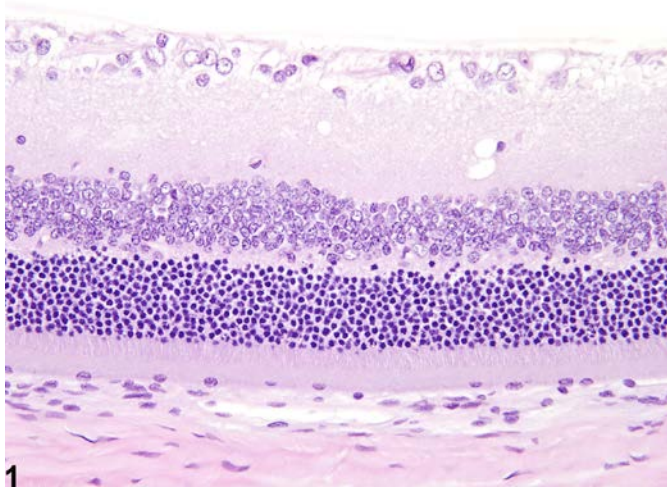




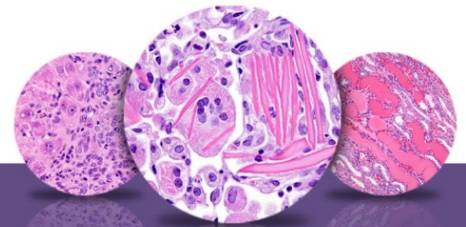
NTP Nonneoplastic Lesion Atlas

Eye, Retina – Degeneration



5

6



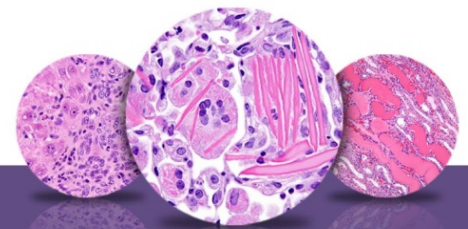NTP Nonneoplastic Lesion Atlas

Eye, Retina – Degeneration

Figure Legend: **Figure 1** Eye, Retina - Normal in a male F344/N rat from a chronic study. Normal retina for comparison to Figures 2 and 3. **Figure 2** Eye, Retina - Degeneration in a male F344/N rat from a chronic study. Mild retinal degeneration, featuring loss of rod and cone photoreceptor processes, single-cell necrosis of outer nuclear layer photoreceptor cells, hypocellularity and disorganization of the inner and outer nuclear layers, and narrowing or absence of the plexiform layers. **Figure 3** Eye, Retina - Degeneration in a male F344/N rat from a chronic study. Marked retinal degeneration, featuring overall thinning, architectural disruption, loss of almost all cellular elements, and complete absence of the rod and cone photoreceptors and the plexiform layers. **Figure 4** Eye, Retina - Normal in a female F344/N rat from a chronic study. Normal peripheral retina (arrow) for comparison to Figures 5 and 6. **Figure 5** Eye, Retina - Degeneration in a female F344/N rat from a chronic study. There is marked thinning of the peripheral retina (arrow). **Figure 6** Eye, Retina - Degeneration in a female F344/N rat from a chronic study (higher magnification of Figure 5). The marked thinning of the peripheral retina (arrow) is due to hypocellularity or absence of retinal layers.

Comment: Retinal degeneration in rats and mice can occur as an aging change or secondary to various insults, such as physical trauma, retinal detachment, inflammation, infectious agents (e.g., viruses), vascular derangements (e.g., infarction), increased intraocular pressure, and nutritional deficiencies. Numerous heritable retinal degenerations have also been documented in various strains of laboratory mice and rats. So-called light-induced retinal degeneration can occur when rats and mice (especially albino strains) are exposed to overly intense ambient light. Retinal degeneration can also be a direct toxic effect of systemically or topically administered chemical agents. Spontaneously occurring retinal degeneration of uncertain etiology has also been reported in laboratory rats and mice. In many types of retinal degeneration, the most commonly affected retinal neurons are the rod and cone photoreceptors and/or the ganglion cells. Depending on the cause, degenerative changes may be localized (or more extensive) in particular retinal topographic regions (i.e., superior vs. inferior, central vs. peripheral).

Mild retinal degeneration (Figure 2, compare to Figure 1) typically consists of loss of the rod and cone photoreceptor processes, apoptosis of outer nuclear layer photoreceptor cells, hypocellularity and disorganization of the inner and outer nuclear layers, and narrowing or absence of the plexiform layers. More pronounced retinal degeneration (Figure 3, compare to Figure 1) is typically characterized by



NTP Nonneoplastic Lesion Atlas

Eye, Retina – Degeneration

overall thinning, architectural disruption, and loss of cellular elements, as well as complete absence of the rod and cone photoreceptors and the plexiform layers. Degenerate retinas may also exhibit other morphologic features, such as diffuse or nodular proliferation of retinal glial cells (e.g., Müller cells and astrocytes), fixed fold and rosette-like formations, and intraretinal cavitations or cysts (“microcystoid” formation and retinoschisis), as well as concurrent proliferation and/or intraretinal migration of the adjacent retinal pigment epithelium.

Rats and mice can also exhibit an incidental aging change known as peripheral retinal degeneration (Figure 5 and Figure 6, compare to Figure 4), which is characterized by marked thinning of the peripheral retina due to hypocellularity or absence of retinal layers. Although not illustrated, cystic cavitations (“microcystoid” change) are also common features of this peripheral age-related degeneration.

Recommendation: Retinal degeneration should be diagnosed and graded whenever present. The location (peripheral or central) and extent of the lesion within the retina, as well as the retinal layers affected, should be described in the pathology narrative. The pathologist’s opinion as to whether it is the peripheral, age related, background form of the lesion (or an exacerbation thereof) or a primary treatment-related lesion should be included in the pathology narrative. The various morphologic features of retinal degeneration (hypocellularity of specific layers, rod and cone photoreceptor process loss, etc.) should not be diagnosed separately but should be described in the narrative. The presence of retinal degeneration should prompt careful examination of the optic nerve for concurrent lesions.

References:

Breider MA, Pilcher GD, Graziano MJ, Gough AW. 1998. Retinal degeneration in rats induced by CI-1010, a 2-nitroimidazole radiosensitizer. *Toxicol Pathol* 26:234-239.

Full-text: <http://tpx.sagepub.com/content/26/2/234.full.pdf+html>

Del Cerro M, Grover D, Monjan A, Pfau C, Dematte J. 1984. Congenital retinitis in the rat following maternal exposure to lymphocytic choriomeningitis virus. *Exp Eye Res* 38:313-324.

Abstract: <http://www.ncbi.nlm.nih.gov/pubmed/6723808>

De Vera Mudry MC, Kronenberg S, Komatsu S-I, Aguirre GD. 2013. Blinded by the light: Retinal phototoxicity in the context of safety studies. *Toxicol Pathol* 41: 813-825.

Abstract: <http://www.ncbi.nlm.nih.gov/pubmed/23271306>



NTP Nonneoplastic Lesion Atlas

Eye, Retina – Degeneration

References:

DiLoreto DA Jr, Del Cerro C, Cox C, Del Cerro M. 1998. Changes in visually guided behavior of Royal College of Surgeons rats as a function of age: A histologic, morphometric, and functional study. *Invest Ophthalmol Vis Sci* 39:1058-1063.

Abstract: <http://www.ncbi.nlm.nih.gov/pubmed/9579488>

Frame SR, Carlton WW. 1991. Toxic retinopathy, rat, mouse, and hamster. In: *International Life Sciences Institute Monographs on Pathology of Laboratory Animals, Vol 10, Eye and Ear* (Jones TC, Mohr U, Hunt RD, eds). Springer, Berlin, 116-124.

Frame SR, Slone TW. 1966. Nonneoplastic and neoplastic changes in the eye. In: *Pathobiology of the Aging Mouse, Vol 2* (Mohr U, Dungworth DL, Capen CC, Carlton WW, Sundberg JP, Ward JM, eds). ILSI Press, Washington, DC, 97-103.

Geiss V, Yoshitomi K. 1991. Eyes. In: *Pathology of the Mouse: Reference and Atlas* (Maronpot RR, Boorman GA, Gaul BW, eds). Cache River Press, Vienna, IL, 471-489.

Abstract: <http://www.cacheriverpress.com/books/pathmouse.htm>

Greaves P. 2007. Nervous system and special sense organs. In: *Histopathology of Preclinical Toxicity Studies: Interpretation and Relevance in Drug Safety Evaluation, 3rd ed.* Academic Press, San Diego, CA, 861-933.

Abstract: <http://www.sciencedirect.com/science/book/9780444527714>

Illanes O, Anderson S, Niesman M, Zwick L, Jessen BA. 2006. Retinal and peripheral nerve toxicity induced by the administration of a pan-cyclin dependent kinase (cdk) inhibitor in mice. *Toxicol Pathol* 34:243-248.

Full-text: <http://tpx.sagepub.com/content/34/3/243.full>

Lai Y-L, Jacoby RL, Jonas AM. 1978. Age-related and light-associated retinal changes in Fischer rats. *Invest Ophthalmol Vis Sci* 17:634-638.

Abstract: <http://www.iovs.org/content/17/7/634.short>

Lee EW, Render JA, Garner CD, Brady AN, Li LC. 1990. Unilateral degeneration of retina and optic nerve in Fischer-344 rats. *Vet Pathol* 27:439-444.

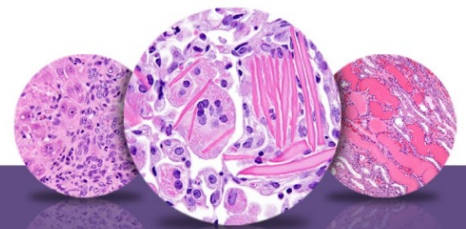
Abstract: <http://vet.sagepub.com/content/27/6/439.short>

Mecklenburg L, Schraermeyer U. 2007. An overview on the toxic morphological changes in the retinal pigment epithelium after systemic compound administration. *Toxicol Pathol* 35:252-267.

Full-text: <http://tpx.sagepub.com/content/35/2/252.full>

Montalbán-Soler L, Alarcón-Martínez L, Jiménez-López M, Salias-Navarro M, Galindo-Romero C, Bezerrade Sá F, García-Ayoso D, Avilés-Trigueros M, Vidal-Sanz M, Agudo-Barrioso M, Villegas-Pérez M. 2012. Retinal compensatory changes after the light damage in albino mice. *Mol Vis* 18:675-693.

Full-text: <http://www.ncbi.nlm.nih.gov/pmc/articles/PMC3325904/>



NTP Nonneoplastic Lesion Atlas

Eye, Retina – Degeneration

References:

National Toxicology Program. 2012. NTP TR-572. Toxicology and Carcinogenesis Studies of Methyl *trans*-Styryl Ketone (CAS No. 1896-62-4) in F344/N Rats and B6C3F1 Mice (Feed and Dermal Studies). NTP, Research Triangle Park, NC.

Abstract: <http://ntp.niehs.nih.gov/go/36154>

Nyska A, Maronpot RR, Ghanayem BI. 1999. Ocular thrombosis and retinal degeneration induced in female F344 rats by 2-butoxyethanol. *Hum Exp Toxicol* 18:577-582.

Abstract: <http://het.sagepub.com/content/18/9/577.abstract>

Ramos M, Reilly CM, Bolon B. 2011. Toxicological pathology of the retina and optic nerve. In: *Fundamental Neuropathology for Pathologists and Toxicologists* (Bolon B, Butt MT, eds). Wiley, Hoboken, NJ, 385-412.

Abstract: <http://onlinelibrary.wiley.com/doi/10.1002/9780470939956.ch24/summary>

Rao GN. 1991. Light intensity-associated eye lesions of Fischer 344 rats in long-term studies. *Toxicol Pathol* 19:148-155.

Full-text: <http://tpx.sagepub.com/content/19/2/148.full.pdf>

Seoane A, Espejo M, Pallàs M, Rodriguez-Farre E, Ambrosio S, Llorens J. 1999. Degeneration and gliosis in rat retina and central nervous system following 3,3'-iminodipropionitrile exposure. *Brain Res* 833:258-271.

Full-text: <http://toxsci.oxfordjournals.org/content/88/2/456.full.pdf>

Serfilippi LM, Stackhouse Pallman DR, Gruebbel MM, Kern TJ, Spainhour CB. 2004. Assessment of retinal degeneration in outbred albino mice. *Comp Med* 54:69-76.

Abstract: <http://www.ncbi.nlm.nih.gov/pubmed/15027621>

Smith RS, Hawes NL, Chang B, Nishina PM. 2002. Retina. In: *Systematic Evaluation of the Mouse Eye: Anatomy, Pathology, and Biomethods* (Smith RS, John SWM, Nishina PM, Sundberg JP, eds). CRC Press, Boca Raton, FL, 195-225.

Sun H, Wang Y, Pang I-H, Shen J, Tang X, Li Y, Liu C, Li B. 2011. Protective effect of a JNK inhibitor against retinal ganglion cell loss induced by acute moderate ocular hypertension. *Mol Vis* 17:864-875.

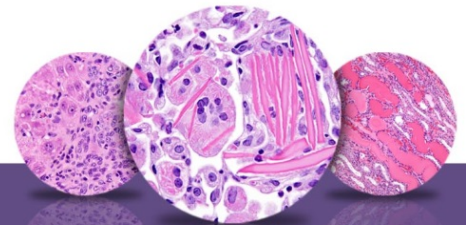
Full-text: <http://www.ncbi.nlm.nih.gov/pmc/articles/PMC3081797/>

Tanito M, Kaidzu S, Ohira A, Anderson RE. 2008. Topography of retinal damage in light-exposed albino rats. *Exp Eye Res* 87:292-295.

Abstract: <http://www.ncbi.nlm.nih.gov/pubmed/18586030>

Taradach C, Greaves P, Rubin LF. 1984. Spontaneous eye lesions in laboratory animals: Incidence in relation to age. *Crit Rev Toxicol* 12:121-147.

Abstract: <http://www.ncbi.nlm.nih.gov/pubmed/6368130>



NTP Nonneoplastic Lesion Atlas

Eye, Retina – Degeneration

References:

Wasowicz M, Morice C, Ferrari P, Callebert J, Versaux-Botteri C. 2002. Long-term effects of light damage on the retina of albino and pigmented rats. *Invest Ophthalmol Vis Sci* 43:813-820.

Full-text: <http://www.iovs.org/content/43/3/813.full>

Weisse I. 1995. Changes in the aging rat retina. *Ophthalmic Res* 27(Suppl 1):154-163.

Abstract: <http://www.karger.com/Article/Abstract/267862>

Weisse I. 1996. Aging and ocular changes. In: *Pathobiology of the Aging Mouse, Vol 2* (Mohr U, Dungworth DL, Capen CC, Carlton WW, Sundberg JP, Ward JM, eds). ILSI Press, Washington, DC, 65-86.

Yoshitomi K, Boorman GA. 1990. Eye and associated glands. In: *Pathology of the Fischer Rat: Reference and Atlas* (Boorman GA, Eustis SL, Elwell MR, Montgomery CA, MacKenzie WF, eds). Academic Press, San Diego, CA, 239-260.

Abstract: <http://www.ncbi.nlm.nih.gov/nlmcatalog/9002563>

Yoshizawa K, Kuro-Kuwata M, Sasaki T, Lai C Y-C, Kanematsu S, Miki H, Kimura-Kawanaka A, Uehara N, Yuri T, Tsubara A. 2011. Retinal degeneration induced in adult mice by a single intraperitoneal injection of N-ethyl-N-nitrosurea. *Toxicol Pathol* 39:606-613.

Full-text: <http://tpx.sagepub.com/content/39/4/606.full>

Author:

Margarita M. Gruebbel, DVM, PhD, DACVP
Senior Pathologist
Experimental Pathology Laboratories, Inc.
Research Triangle Park, NC