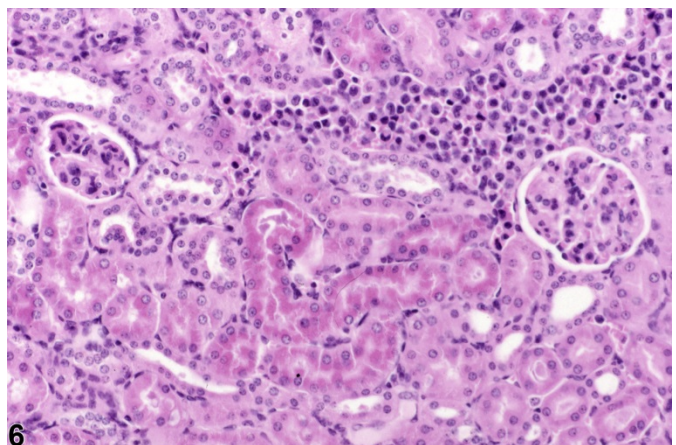
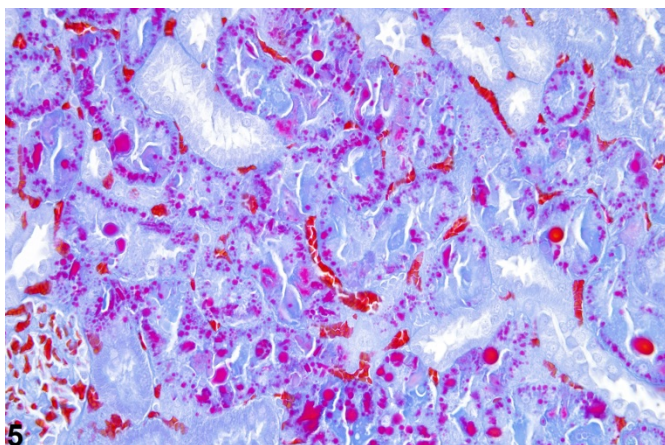
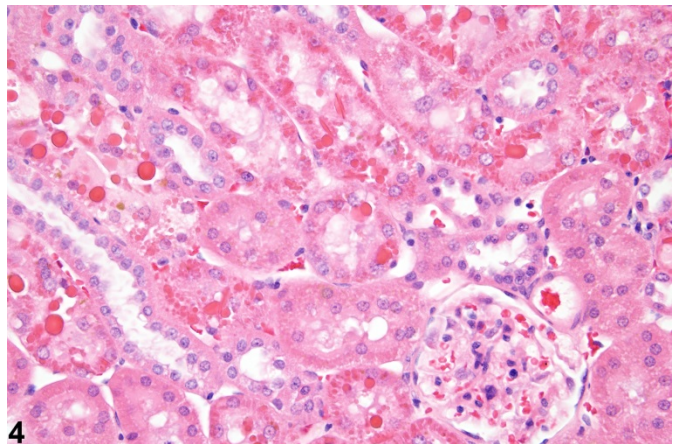
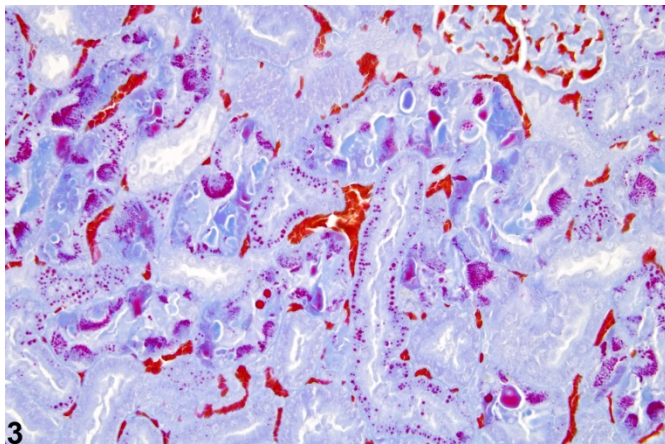
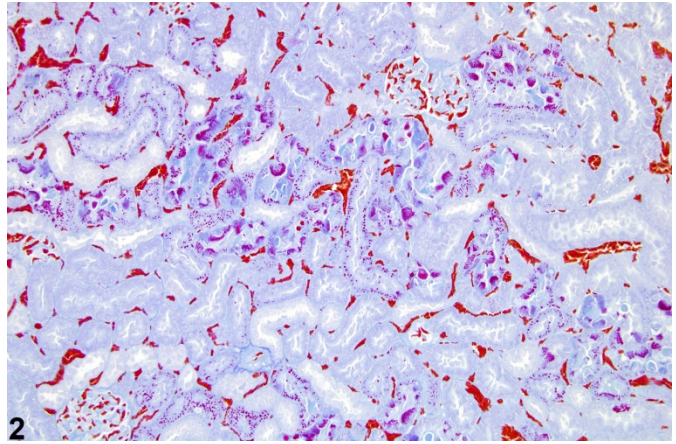
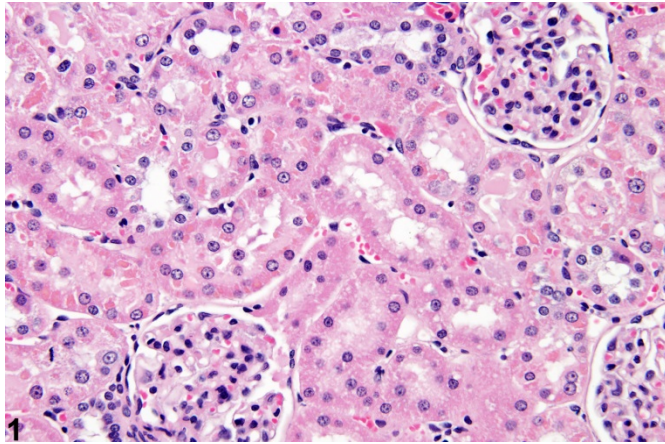
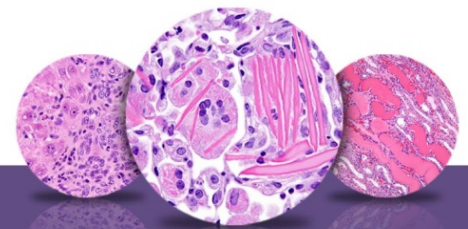



NTP Nonneoplastic Lesion Atlas

Kidney, Renal Tubule – Accumulation, Hyaline Droplet



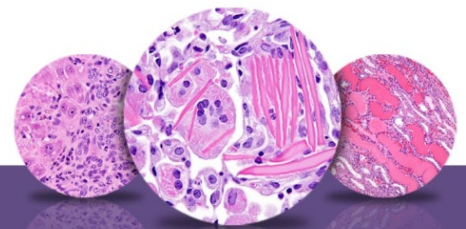

NTP Nonneoplastic Lesion Atlas

Kidney, Renal Tubule – Accumulation, Hyaline Droplet

Figure Legend: **Figure 1** Kidney, Renal tubule - Hyaline droplets in a male F344/N rat from a subchronic study. Normal-appearing small hyaline droplets are present in renal tubule epithelial cells. **Figure 2** Kidney, Renal tubule - Hyaline droplets in a male rat from a subchronic study. The cytoplasmic staining pattern of normal hyaline droplets is presented (Mallory-Heidenhain stain). **Figure 3** Kidney, Renal tubule - Hyaline droplets in a male F344/N rat from a subchronic study (higher magnification of Figure 2). Several droplet-congested, normal, renal tubule epithelial cells are shown (Mallory-Heidenhain stain). **Figure 4** Kidney, Renal tubule - Accumulation, Hyaline droplet in a male F344/N rat from a subchronic study. Increased number and size of hyaline droplets associated with chemically induced increase in alpha 2u-globulin. **Figure 5** Kidney, Renal tubule - Accumulation, Hyaline droplets in a male F344/N rat from a subchronic study. The appearance of enlarged and crystalline-shaped droplets is associated with chemically induced increase in alpha 2u-globulin (Mallory-Heidenhain stain). **Figure 6** Kidney, Renal tubule - Accumulation, Hyaline droplets in a B6C3F1 mouse in a subchronic study. Hyaline droplets are associated with histiocytic sarcoma.

Comment: Hyaline droplets are eosinophilic homogeneous cytoplasmic droplets that are normally present in the P2 segment of proximal tubule epithelia of young, mature male rats. The droplets represent alpha 2u-globulin sequestered in secondary lysosomes (Figure 1), and selective staining with Mallory-Heidenhain enhances their visibility and cytoplasmic distribution (Figure 2 and Figure 3). “Hyaline droplet accumulation” may be used as a diagnostic term to describe other morphologically similar eosinophilic droplets in male and female rodents. Normally, renal tubule epithelial cells of female rats and male and female mice do not have hyaline droplets. Alpha 2u-globulin nephropathy comprises a male-rat-specific syndrome that results in a morphologically variable spectrum of lesions that generally includes the presence of hyaline droplets, degeneration/necrosis and regeneration of tubule epithelial cells, and the presence of granular casts in the outer medulla in subchronic studies. In chronic studies, exacerbation of chronic progressive nephropathy and linear papillary mineralization are generally observed. Male NBR rats do not develop alpha 2u-globulin nephropathy and are used as negative controls in toxicology studies of chemicals suspected to induce this syndrome. In alpha 2u-globulin nephropathy, hyaline droplets increase in number, and their morphology may change from spherical to crystalloid polyangular shape (Figure 4). In addition, Mallory-Heidenhain staining shows that as the number of droplets increases and their morphology changes, the normal cytoplasmic



NTP Nonneoplastic Lesion Atlas

Kidney, Renal Tubule – Accumulation, Hyaline Droplet

distribution of the hyaline droplets becomes altered (Figure 5). Hyaline droplets are usually not present in chronic studies. Pathologists must be aware that the presence of hyaline droplets may not always indicate the presence of alpha 2u-globulin nephropathy since other conditions such as tumor-bearing animals may have hyaline droplets. This is particularly true with histiocytic sarcoma in mice and rats.

Recommendation: Since the presence of hyaline droplets is a normal occurrence in younger male rats, the diagnosis of hyaline droplet accumulation in male rats in subchronic studies should be reserved for those cases in which there is an increase in the number of hyaline droplets relative to controls. In female rats, and male and female mice, hyaline droplet accumulation should be diagnosed whenever hyaline droplets are present. Hyaline droplet accumulation should be graded whenever it is diagnosed. Other changes seen concurrently and in association with hyaline droplet accumulation (e.g., granular cast formation, degeneration/necrosis of epithelial cells) should be diagnosed separately. The suspected pathogenesis (e.g., increased alpha 2U-globulin, association with neoplasia) should be discussed in the pathology narrative.

References:

Decker JH, Dochterman LW, Niquette AI, Brej M. 2012. Association of renal tubular hyaline droplets with lymphoma in CD-1 mice. *Toxicol Pathol* 40:651-655.

Abstract: <http://www.ncbi.nlm.nih.gov/pubmed/22395792>

De Rijk EPCT, Ravesloot WTM, Wijnands Y, van Esch E. 2003. A fast histochemical staining method to identify hyaline droplets in the rat kidney. *Toxicol Pathol* 31:462-464.

Full-text: <http://tpx.sagepub.com/content/31/4/462.full.pdf>

Greaves P. 2012. *Histopathology of Preclinical Toxicity Studies*, 4th ed. Elsevier, Amsterdam, 560.

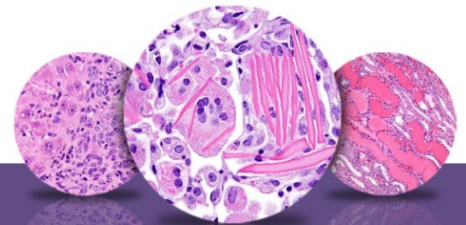
Abstract: <http://www.sciencedirect.com/science/book/9780444538567>

Hard GC. 2008. Some aids to histological recognition of hyaline droplet nephropathy in ninety-day toxicity studies. *Toxicol Pathol* 36:1014-1017.

Full-text: <http://tpx.sagepub.com/content/36/7/1014.full>

Hard GC, Snowden RT. 1991. Hyaline droplet accumulation in rodent kidney proximal tubules: An association with histiocytic sarcoma. *Toxicol Pathol* 19:88-97.

Abstract: <http://www.ncbi.nlm.nih.gov/pubmed/1722903>



NTP Nonneoplastic Lesion Atlas

Kidney, Renal Tubule – Accumulation, Hyaline Droplet

References:

Lehman-McKeeman LD, Caudil D. 1992. Biochemical basis for mouse resistance to hyaline droplet nephropathy: Lack of relevance of the alpha 2u-globulin protein superfamily in this male rat-specific syndrome. *Toxicol Appl Pharmacol* 112:214-221.

Abstract: <http://www.ncbi.nlm.nih.gov/pubmed/1371614>

Luz A, Murray AB. 1991. Hyaline droplet accumulation in kidney proximal tubules of mice with histiocytic sarcoma. *Toxicol Pathol* 19:670-671.

Short BG, Burnett VL, Cox MG, Bus JS, Swenberg JA. 1987. Site-specific renal cytotoxicity and cell proliferation in male rats exposed to petroleum hydrocarbons. *Lab Invest* 57:564-577.

Abstract: <http://www.ncbi.nlm.nih.gov/pubmed/3682766>

Swenberg JM, Short B, Strasser J, Charbonneau M. 1989. The comparative pathobiology of α 2u-globulin nephropathy. *Toxicol Appl Pharmacol* 97:35-46.

Abstract: <http://www.sciencedirect.com/science/article/pii/0041008X89900537>

Uwagawa S, Saito K, Nakayama A, Umihira M, Okuno Y. 1990. Comparison of hyaline droplets in rats with chronic progressive nephropathy and chemical-induced α 2u-globulin nephropathy. *J Toxicol Pathol* 5:195-203.

Yamate J, Iwaki M, Nakatsuji S, Kuwamura M, Kotani T, Sakuma S. 1998. Lysozyme-containing renal tubular hyaline droplets in F344 rats bearing a rat fibrosarcoma-derived transplantable tumor. *Toxicol Pathol* 26:699-703.

Abstract: <http://www.ncbi.nlm.nih.gov/pubmed/9789960>

Authors:

John Curtis Seely, DVM, DACVP
Senior Pathologist
Experimental Pathology Laboratories, Inc.
Research Triangle Park, NC

Amy Brix, DVM, PhD, DACVP
Senior Pathologist
Experimental Pathology Laboratories, Inc.
Research Triangle Park, NC