

NATIONAL TOXICOLOGY PROGRAM
Technical Report Series
No. 277



TOXICOLOGY AND CARCINOGENESIS

STUDIES OF

TREMOLITE

(CAS NO. 14567-73-8)

IN F344/N RATS

(FEED STUDIES)

U.S. DEPARTMENT OF HEALTH AND HUMAN SERVICES
Public Health Service
National Institutes of Health

FOREWORD

The National Toxicology Program (NTP), established in 1978, develops and evaluates scientific information about potentially toxic and hazardous chemicals. This knowledge can be used for protecting the health of the American people and for the primary prevention of disease. By bringing together the relevant programs, staff, and resources from the U.S. Public Health Service, DHHS, the National Toxicology Program has centralized and strengthened activities relating to toxicology research, testing and test development/validation efforts, and the dissemination of toxicological information to the public and scientific communities and to the research and regulatory agencies.

The NTP is made up of four charter DHHS agencies: the National Cancer Institute (NCI), National Institutes of Health; the National Institute of Environmental Health Sciences (NIEHS), National Institutes of Health; the National Center for Toxicological Research (NCTR), Food and Drug Administration; and the National Institute for Occupational Safety and Health (NIOSH), Centers for Disease Control. In July 1981, the Carcinogenesis Bioassay Testing Program, NCI, was transferred to the NIEHS.

This study was conducted under contract to the National Institute of Environmental Health Sciences, National Toxicology Program. The studies described in this Technical Report have been conducted in compliance with NTP chemical health and safety requirements and must meet or exceed all applicable Federal, state, and local health and safety regulations. Animal care and use were in accordance with the U.S. Public Health Service Policy on Humane Care and Use of Animals. All NTP toxicology and carcinogenesis studies are subjected to a data audit before being presented for peer review.

These NTP Technical Reports are available for sale from the National Technical Information Service, U.S. Department of Commerce, 5285 Port Royal Road, Springfield, VA 22161 (703-487-4650). Single copies of this Technical Report are available without charge (and while supplies last) from the NTP Public Information Office, National Toxicology Program, P.O. Box 12233, Research Triangle Park, NC 27709.

Special Note: This Technical Report was peer reviewed in public session and approved by the NTP Board of Scientific Counselors' Technical Reports Review Subcommittee on September 22, 1982 [see page 7]. Thereafter, the NTP adopted the policy that the experimental data and laboratory records from all NTP toxicology and carcinogenesis studies not yet printed and distributed would be audited. The audit report was reviewed by NTP staff, who determined that none of the discrepancies influenced the final interpretation of the results of these studies. The audit report is on file at the NIEHS/NTP Quality Assurance Office and is available for review.

Because printing and distribution of this Technical Report have been delayed, the format differs from that of Technical Reports peer reviewed more recently. The categories of evidence of carcinogenicity adopted by the NTP in June 1983 were not used to evaluate these data. This final Technical Report supersedes all previous drafts of this report that have been distributed.

NTP TECHNICAL REPORT
ON THE
TOXICOLOGY AND CARCINOGENESIS
STUDIES OF TREMOLITE
(CAS NO. 14567-73-8)
IN F344/N RATS
(FEED STUDIES)

Ernest E. McConnell, D.V.M., Chemical Manager

NATIONAL TOXICOLOGY PROGRAM
P.O. Box 12233
Research Triangle Park, NC 27709

March 1990

NTP TR 277

NIH Publication No. 90-2531

U.S. DEPARTMENT OF HEALTH AND HUMAN SERVICES
Public Health Service
National Institutes of Health

CONTENTS


	PAGE
ABSTRACT	3
CONTRIBUTORS	4
PEER REVIEW PANEL	5
SUMMARY OF PEER REVIEW COMMENTS	6
I. INTRODUCTION	7
II. MATERIALS AND METHODS	11
III. RESULTS	21
IV. DISCUSSION AND CONCLUSIONS	35
V. REFERENCES	39

APPENDIXES

APPENDIX A SUMMARY OF LESIONS IN MALE RATS IN THE LIFETIME FEED STUDY OF TREMOLITE	43
APPENDIX B SUMMARY OF LESIONS IN FEMALE RATS IN THE LIFETIME FEED STUDY OF TREMOLITE	109
APPENDIX C PATHOGEN BURDEN SURVEY	159
APPENDIX D ANALYSIS OF BEDDING SAMPLES IN THE LIFETIME FEED STUDIES OF TREMOLITE	169
APPENDIX E WATER ANALYSIS IN THE LIFETIME FEED STUDIES OF TREMOLITE	171
APPENDIX F AIR ANALYSIS IN THE LIFETIME FEED STUDIES OF TREMOLITE	173
APPENDIX G SUMMARY OF CLINICAL SIGNS OBSERVED PRIOR TO MORIBUND KILL IN THE LIFETIME FEED STUDIES OF TREMOLITE	177
APPENDIX H FEED AND COMPOUND CONSUMPTION BY RATS IN THE LIFETIME FEED STUDIES OF TREMOLITE	181

TREMOLITE

CAS No. 14567-73-8



ABSTRACT

A carcinogenesis bioassay of blocky (nonfibrous) tremolite was conducted with male and female F344/N rats. Tremolite was administered at a concentration of 1% in pelleted diet for the entire lifetime of the rats, starting with the dams of the study animals. The studies were started in 1978 and ended in 1981. Group sizes were 118 male and female controls and 250 male and female tremolite-exposed rats.

Litter size was not affected by the administration of tremolite to the dams. The offspring from mothers exposed to tremolite were the same size at birth as the controls but were slightly smaller at weaning and remained so throughout their life. Survival was similar in the exposed and control groups. No toxicity or increase in incidence of neoplasia was observed in the tremolite-exposed animals compared with the concurrent controls.

Conclusions: Under the conditions of these feed studies, nonfibrous tremolite was not overtly toxic or carcinogenic for male or female F344/N rats, following lifetime ingestion of a diet containing 1% tremolite.

A summary of the Peer Review comments and the public discussion on this Toxicity Report appears on page 6.

CONTRIBUTORS

The NTP Technical Report on the Toxicology and Carcinogenesis Studies of Tremolite is based on the lifetime studies that began in February 1978 and ended in January/February 1981 at Hazleton Laboratories America, Inc. (Vienna, VA).

National Toxicology Program (Evaluated Experiment, Interpreted Results, and Reported Findings)

E.E. McConnell, D.V.M., Chemical Manager

Gary A. Boorman, D.V.M., Ph.D.
Rajendra S. Chhabra, Ph.D.
Joseph K. Haseman, Ph.D.

James Huff, Ph.D.
John A. Moore, Ph.D.
Raymond W. Tennant, Ph.D.

NTP Pathology Working Group (Evaluated Slides and Prepared Pathology Report on 1/15/82)

Gary A. Boorman, D.V.M., Ph.D. (NTP)
Scot Eustis, D.V.M., Ph.D. (NTP)
B.N. Gupta, D.V.M., Ph.D. (NTP)
Ernest E. McConnell, D.V.M. (NTP)

Robert Sauer, D.V.M., Ph.D. (Clement Associates)
Miriam Anver, D.V.M., Ph.D. (Clement Associates)

Principal Contributors at Hazleton Laboratories America, Inc. (Conducted Studies and Evaluated Tissues)

Henry A. Rutter, Jr., Ph.D.
B. Ulland, D.V.M.

Frederick Snyder

Principal Contributors at Experimental Pathology Laboratories, Inc. (Provided Pathology Quality Assurance)

Jerry Hardisty, D.V.M.

William Iverson, D.V.M.

Principal Contributors at Carltech Associates, Inc. (Contractor for Technical Report Preparation)

William D. Theriault, Ph.D.
Abigail C. Jacobs, Ph.D.

John Warner, M.S.
Naomi Levy, B.A.

PEER REVIEW PANEL

The members of the Peer Review Panel who evaluated the draft Technical Report on tremolite on September 22, 1982, are listed below. Panel members serve as independent scientists, not as representatives of any institution, company, or governmental agency. In this capacity, Panel members have five major responsibilities: (a) to ascertain that all relevant literature data have been adequately cited and interpreted, (b) to determine if the design and conditions of the NTP studies were appropriate, (c) to ensure that the Technical Report presents the experimental results and conclusions fully and clearly, (d) to judge the significance of the experimental results by scientific criteria, and (e) to assess the evaluation of the evidence of carcinogenicity and other observed toxic responses.

National Toxicology Program Board of Scientific Counselors Technical Reports Review Subcommittee

Margaret Hitchcock, Ph.D. (Chair)
Pharmacology Toxicology
John B. Pierce Foundation Laboratory
New Haven, CT

Curtis Harper, Ph.D. (Principal Reviewer)
Associate Professor of Pharmacology
University of North Carolina
Chapel Hill, NC

Alice Whittemore, Ph.D.
Biostatistics
Stanford University School of Medicine
Palo Alto, CA

Ad Hoc Subcommittee Panel of Experts

Norman Breslow, Ph.D.*
Biostatistics
University of Washington
Seattle, WA

Robert A. Scala, Ph.D. (Principal Reviewer)
Exxon Corporation
East Millstone, NJ

Robert M. Elashoff, Ph.D.
Biostatistics
University of California at Los Angeles
Jonsson Comprehensive Cancer Center
Los Angeles, CA

Bernard Schwetz, Ph.D., D.V.M.
Toxicology Research Laboratory
Dow Chemical U.S.A.
Midland, MI

Joseph Highland, Ph.D.*
Toxicology, Environmental Defense Fund
Washington, DC

James Swenberg, Ph.D., D.V.M.
Chief of Pathology
Chemical Industry Institute of Toxicology
Research Triangle Park, NC

J. Michael Holland, Ph.D., D.V.M.
Department of Biology
Oak Ridge National Laboratory
Oak Ridge, TN

Stan D. Vesselinovitch, D.V.Sc. (Principal Reviewer)
Departments of Radiology and Pathology, University of Chicago
Chicago, IL

Frank Mirer, Ph.D.
International Union, United Auto Workers
Detroit, MI

Mary Vore, Ph.D.
Pharmacology, University of Kentucky
College of Medicine
Lexington, KY

*Unable to attend meeting

**SUMMARY OF PEER REVIEW COMMENTS
ON THE TOXICOLOGY AND CARCINOGENESIS STUDIES OF
TREMOLITE**

On September 22, 1982, the draft Technical Report on the toxicology and carcinogenesis studies of tremolite received peer review by the National Toxicology Program Board of Scientific Counselors' Technical Reports Review Subcommittee and associated Panel of Experts. The review meeting was held in the Conference Center, Building 101, South Campus, National Institute of Environmental Health Sciences, Research Triangle Park, NC.

Dr. E.E. McConnell, NIEHS, introduced the studies by reviewing the experimental design, results, and proposed conclusions (not overtly toxic or carcinogenic for male or female rats, following lifetime ingestion of a diet containing 1% tremolite).

Dr. Vesselinovitch, a principal reviewer, agreed with the conclusions for male and female rats. As a second principal reviewer, Dr. Harper said that the Abstract should include the observation that the offspring of mothers exposed to tremolite were of normal size at birth but were smaller than control animals at weaning and remained smaller throughout their life.

As a third principal reviewer, Dr. Scala stressed the need to discuss whether a maximum tolerated dose had been achieved and noted that possible toxic effects may be seen in early weight gain differences between control and exposed neonatal animals which may never equalize. Dr. Scala asked why the study was conducted in the first place, especially if the major carcinogenic potential of this class of minerals resides in their fibrous nature; he questioned what could be gained from testing a non-fibrous material.

Dr. McConnell responded that this study was the first attempt to determine whether tremolite given orally had any potential for causing toxicity. Dr. Moore, NTP, noted that this form of crystalline tremolite was used widely and was found in food and pharmaceutical products. He added that the tremolite used has a fibrous contaminant that could be produced from the crushing process or could occur naturally. The fiber count for this contaminant will be indicated in the Report. Dr. R. Shapiro, NIEHS, said that the tremolite used was chosen to duplicate the commercial material to which humans had been exposed in the past.

Dr. Harper moved that the Report on the lifetime carcinogenesis studies of tremolite be accepted with the modifications discussed. Dr. Elashoff seconded the motion, and the Technical Report was approved unanimously by the Peer Review Panel.

I. INTRODUCTION

Definition

Exposure


Mutagenicity

Background and Testing Rationale

I. INTRODUCTION

TREMOLITE

CAS No. 14567-73-8



Definition

The term "asbestos" has a commercial/industrial derivation limited to naturally occurring fibrous minerals of the serpentine or amphibole series. Chrysotile is the only type of asbestos in the serpentine series, whereas the amphibole series is represented by crocidolite, amosite, actinolite, tremolite, and anthophyllite. The essential characteristic of asbestos minerals is their fibrous nature. Tremolite may also occur in a crystalline (nonfibrous) form in nature, but this nonfibrous form may assume fibrous characteristics during processing.

Excellent reviews of public health effects associated with past heavy asbestos exposure, primarily occupational exposure via the inhalation route, are those by Craighead and Mossman (1982), Peto and Schneiderman (1981), Selikoff (1980), the U.S. Environmental Protection Agency (EPA) (USEPA, 1980), Selikoff and Hammond (1979), and the International Agency for Research on Cancer (IARC, 1977). These studies clearly established an association between occupational inhalation exposure to chrysotile, amosite, crocidolite, and anthophyllite asbestos and an increased risk of lung cancer as well as mesothelioma. The latter form of cancer is perhaps unique in its association with these minerals.

Exposure

Large portions of the population ingest asbestos through consumption of food and water. Analyses of water samples from 365 cities found 45% to have detectable levels of various types of asbestos (Millette, 1979). Forty-one cities had asbestos concentrations in water which exceeded 10 million fibers per liter. Asbestos or other minerals of similar morphology may gain access to water supplies as a result of mining (Lake Superior), the presence of natural serpentine or amphibole deposits in watersheds (Seattle, WA, and

San Francisco, CA), or under certain conditions, through the use of asbestos-cement pipe for municipal water supplies (USEPA, 1980). For the latter, erosion of the pipe with release of fibers is associated with the "aggressiveness" of the water, a term representing a mathematical expression of pH, alkalinity, and calcium content. The EPA estimated that 68.5% of U.S. water systems utilize water that has the potential to erode asbestos-cement pipe.

A number of studies have provided evidence that ingestion of asbestos in either food or water can result in the migration of asbestos fibers through the gastrointestinal mucosa and to distant organ sites in humans (Carter and Taylor, 1980), rats (Cunningham et al., 1977; Sebastien et al., 1980), and baboons (Storeygard and Brown, 1977; Patel-Mandlik, 1980). Electron microscopic studies confirmed the presence of amphibole mineral fibers in the urine of individuals who ingested water containing these fibers (Cook and Olson, 1979).

Harrington et al. (1978) failed to detect an association between the use of asbestos-cement pipe for municipal water supplies in Connecticut and the incidence of gastrointestinal cancer. In a study of cancer incidence in the San Francisco Bay area, Kanarek et al. (1980) reported a statistically significant trend for the increased incidence of several cancer types, including stomach, gallbladder, esophageal, and peritoneal cancer, when census tracts were analyzed on a gradient of low to high asbestos content in municipal water. Cooper et al. (1979) confirmed the association between asbestos concentrations in the San Francisco Bay area drinking water and cancer of the digestive tract.

Studies in animals have shown that inhalation of asbestos produces lung carcinomas and mesotheliomas in the pleural cavity (Wagner et al., 1974). A review of these studies is provided by Levine (1981). Intrapleural, intratracheal, or

intraperitoneal injection of asbestos also induces neoplasia in several species of laboratory animals (Stanton et al., 1981).

Mutagenicity

Asbestos (chrysotile, amosite, and crocidolite) has been shown to be cytogenic in vitro to human embryonic intestine, mouse epithelial-like colon-derived cells, and rat liver epithelial cells (Reiss et al., 1979). However, chrysotile asbestos was far more cytotoxic than were the amphibole fibers, and the effects were more pronounced in the intestine-derived cells than in those from the liver. Asbestos was also cytotoxic to Syrian hamster peritoneal macrophages (Bey and Harrington, 1971). Using the HGPRT locus/resistance to 6-thioguanine assay system, Reiss et al. (1979) showed that these three forms of asbestos were not mutagenic. In addition, no mutagenic activity was demonstrated when chrysotile, amosite, or crocidolite asbestos was used in *Escherichia coli* or *Salmonella typhimurium* systems (Chamberlain and Tarmy, 1977).

Background and Testing Rationale

In November 1973, the National Institute of Environmental Health Sciences and the EPA co-sponsored a symposium on the possible biologic effects of ingested asbestos (EHP, 1974). The participants at this conference concluded that a paucity of definitive data existed concerning the effects of ingested asbestos and that specific research was needed.

A subcommittee of the U.S. Department of Health, Education, and Welfare (now the U.S. Department of Health and Human Services) Committee to Coordinate Toxicology and Related Programs was established to review existing

data and to prepare a draft research protocol that would be responsive to the potential public health implications of ingested asbestos. This protocol was distributed widely for comment within and outside the government, and a public meeting of the Subcommittee was held on February 11, 1975. On the basis of comments received, a revised protocol was developed which called for the use of long-term animal toxicology studies to evaluate the ingestion of several minerals for carcinogenic effects. As a result, the National Toxicology Program has investigated the carcinogenic potential of ingested chrysotile asbestos in hamsters (NTP, 1990a) and rats (NTP, 1985a), amosite asbestos in hamsters (NTP, 1985b) and rats (NTP, 1990b), crocidolite asbestos in rats (NTP, 1988), and tremolite in rats (this Report). All of the studies were to encompass the lifetime of the animal, including exposure of the dams from which the study animals were derived.

Crystalline tremolite was chosen for these studies because this form of asbestos was a common contaminant of the talc used in foods and pharmaceuticals 20 years ago. The grinding of tremolite in preparation for its intended use may result in the production of fibers that have the morphology of asbestos minerals. Stanton et al. (1981) speculated that the asbestos mineral hazard may be related directly to fiber size in contrast to chemical composition. Therefore, the study of crystalline tremolite was deemed appropriate because of past widespread exposure and because small amounts assume fiber characteristics when ground during the processing of talc.

This Technical Report represents the results of those studies undertaken to determine the effects of crystalline tremolite in the diet fed to

II. MATERIALS AND METHODS

Study Material

Study Diets

Source and Specifications of Study Animals

Animal Maintenance

Safety Precautions

Clinical Examinations and Pathology

Statistical Methods

II. MATERIALS AND METHODS

Study Material

The tremolite sample used in these studies was obtained from a single lense from the Gouverneur Talc Company (Gouverneur, NY). This 1,200-lb lense was taken from the 500-ft level, American vein, No. 4 footwall stope, lower portion of the footwall bedding. The lense was crushed in a Denver Jaw Crusher and then to -14 mesh in a roll crusher. This material was then wheeler milled at 204° C and bagged in 50-lb Kraft bags. The final particle size was nominally -325 mesh.

To develop homogeneity of the sample, approximately 960 lb of tremolite was blended in a 10-ft³ V-type blender. After final blending, the samples were weighed to 25 ± 0.5 lb and placed in 38 sealed fiberboard drums. These drums were shipped to a special warehouse at Research Triangle Park, NC. Each drum received a color marking unique to the mineral type. Homogeneity of the samples was verified by fluorescent X-ray spectroscopy from samples collected from six randomly selected drums. No significant differences were detected.

The homogeneity of the samples and the physical and chemical properties of the materials were extensively characterized by the Bureau of Mines (1980) and by the Fine Particles

Laboratories, Illinois Institute of Technology Research Institute (IITRI, Special Report). [Copies of these reports are available on request from the National Toxicology Program (Public Information Office, National Toxicology Program, P.O. Box 12233, Research Triangle Park, NC 27709).]

Selected chemical and physical properties of tremolite are presented in Tables 1 and 2 (Bureau of Mines, 1980). In an analysis of mineralogic composition, tremolite ($\text{Ca}_2\text{Mg}_5\text{Si}_8\text{O}_{22}(\text{OH})_2 \cdot \text{Ca}_2\text{Mg}_4\text{FeSi}_8\text{O}_{22}(\text{OH})_2$) was detected at a volume percent abundance of 72 and serpentine at 25; minor amounts of talc, calcite, phlogopite, and anthophyllite were found.

Study Diets

The feed used was NIH 31 Rat and Mouse Ration. Tremolite was incorporated into the study diet at a concentration of 1% by weight. Pilot studies determined that homogeneous mixing of tremolite and feed would occur in a blender loaded by alternate layering of feed and tremolite. Each batch of blended feed was analyzed for tremolite concentration, pesticide contamination, and nutrient content. Results of analyses for tremolite in feed are given in Table 3. Further details are given in Table 4.

TABLE 1. FIBER CHARACTERISTICS AND CHEMICAL INSTRUMENTAL ANALYSIS OF TREMOLITE

Fiber characteristics			
Surface area (m ² /g)		5.2 ± 0.5	
Density (g/cm ³)		2.91 ± 0.01	
Chemical instrumental analysis (expressed as weight percent)			
Al ₂ O ₃	1.57	Li ₂ O	0.02
CaO	11.26	SnO	0.01
Fe ₂ O ₃	0.27	SrO	0.03
MgO	26.71	Bi ₂ O ₃	0.01
K ₂ O	0.18	CO ₂	0.78
SiO ₂	54.00	H ₂ O ⁻	0.24
Na ₂ O	0.80	H ₂ O ⁺	3.73
TiO ₂	0.03	Benzene-extracted organics	0.003
MnO	0.05		

TABLE 2. PARTICLE SIZE DISTRIBUTION OF TREMOLITE, SERPENTINE TALC, AND OTHER MINERALS BY PARTICLE NUMBER (a)

	Length Interval (μm)										
	0-0.99	1-1.99	2-2.99	3-3.99	4-4.99	5-5.99	6-6.99	7-7.99	8-8.99	9-9.99	>10
Tremolite mean width (μm)	0.48	0.88	0.97	1.51	2.05	2.19	2.79	3.29	2.96	3.13	5.22
Tremolite particles per interval	59	291	194	106	53	40	31	19	9	13	58
Percent of total tremolite particles	6.8	33.4	22.3	12.2	6.1	4.6	3.6	2.2	1.0	1.4	6.4
Cumulative percent tremolite	6.8	40.2	62.5	74.7	80.8	85.4	89.0	91.2	92.2	93.6	100
Tremolite particles per interval	34	197	128	83	38	27	23	15	9	12	49
Volume percent tremolite (b)	5.5	32.0	20.8	13.5	6.2	4.4	3.7	2.4	1.5	2.0	8.0
Cumulative volume percent tremolite	5.5	37.5	58.3	71.8	78.0	82.4	86.1	88.5	9.0	92.0	100
Serpentine talc particles per interval	9	72	53	19	11	9	8	4	0	1	7
Number of other particles	16	22	10	4	2	4	0	0	0	0	2
Tremolite particles per length interval, percent, by aspect ratio (b)											
1:1-2.9:1	100	92	75	67	76	67	65	66	67	30	35
3:1-4.9:1	0	8	22	29	18	30	30	20	22	35	37
5:1-9.9:1	0	0	3	4	6	3	5	7	11	35	18
10:1-19.9:1	0	0	0	0	0	0	0	7	0	0	4
20:1-49.9:1	0	0	0	0	0	0	0	0	0	0	4
50:1-99.9:1	0	0	0	0	0	0	0	0	0	0	0
100:1-199:1	0	0	0	0	0	0	0	0	0	0	2

(a) From Bureau of Mines (1980). By electron microscopy; total particles = 871; total tremolite = 615; total serpentine talc = 193; total others = 63.

(b) Data for aspect ratio were obtained from a second set of measurements.

TABLE 3. RESULTS OF ANALYSIS OF FORMULATED DIETS IN THE LIFETIME FEED STUDIES OF TREMOLITE

Date Mixed	Determined Concentration in Feed for Target Concentration of 10,000 ppm (1%) (a)
11/21/77	8,700 ± 1,000
12/07/77	10,800 ± 1,500
02/01/78	9,100 ± 3,500
03/22/78	10,400 ± 6,300
05/22/78	8,300 ± 1,500
07/11/78	7,700 ± 1,400
09/14/78	10,000 ± 1,000
10/30/78	7,500 ± 2,600
12/15/78	10,300 ± 800
02/15/79	11,600 ± 200
04/02/79	11,100 ± 600
05/19/79	10,700 ± 200
06/26/79	9,600 ± 400
08/28/79	8,400 ± 1,100
10/16/79	10,300 ± 500
12/03/79	9,700 ± 1,000
01/10/80	9,200 ± 700
02/27/80	10,700 ± 800
04/18/80	9,500 ± 1,400
05/19/80	9,700 ± 1,100
07/18/80	10,300 ± 1,200
08/26/80	10,000 ± 900
10/13/80	10,300 ± 1,700
	Mean = 9,700 ± 2,100

(a) Average of five samples

TABLE 4. EXPERIMENTAL DESIGN AND MATERIALS AND METHODS IN THE LIFETIME FEED STUDIES OF TREMOLITE

EXPERIMENTAL DESIGN	
Size of Study Groups	F ₀ --control: male, 25; female, 50; exposed: male, 70; female, 140; F ₁ --control: 118; tremolite: 250 rats of each sex
Doses	0% or 1% (10,000 ppm) tremolite in feed
Date of First Dose	F ₀ --obtained 11/1/77, bred starting 1/25/78; F ₁ --date of weaning
Duration of Dosing	Lifetime until only 10% of the group remained
Type and Frequency of Observation	Observed 2 × d; examined clinically 1 × wk; weighed 1 × wk
Necropsy and Histologic Examinations	Necropsy performed on all animals. Tissues examined histologically: adrenal glands; bone marrow (sternum); brain; bronchial, celiac, cervical, iliac, ilioocolonic, mandibular, mesenteric, pancreatic, and renal lymph nodes; cecum; colon (carpet rolled); duodenum; esophagus; heart; ileum; jejunum; kidneys; larynx; liver; lungs and bronchi; mammary gland; pancreas; parathyroids; pituitary gland; prostate/testes or ovaries/uterus; salivary glands; small intestine; spleen; stomach; thigh muscle; thyroid gland; tissue masses; trachea; and urinary bladder. Epididymis, eyes, nasal cavity with turbinates, seminal vesicles, and spinal cord were examined microscopically if gross lesions were observed
ANIMALS AND ANIMAL MAINTENANCE	
Strain and Species	F344/N rats
Animal Source	Charles River Breeding Laboratories (Wilmington, MA)
Study Laboratory	Hazleton Laboratories of America
Age When Placed on Study	F ₀ --15-16 wk prior to delivery of F ₁
Age When Killed	Lifetime study; final 10% of F ₁ killed at: male, 146 wk; female, 148 wk
Method of Animal Distribution	According to tables of computer-generated random numbers
Feed	NIH 31 Rat and Mouse Ration (Zeigler Bros., Inc., Gardners, PA); available ad libitum
Bedding	Sani Chips® (J.P. Murphy, Rochelle Park, NJ, and Shurfire, Baltimore, MD)
Water	Tap water ad libitum
Cages	Polycarbonate (Hazleton Systems, Aberdeen, MD); stored on Enviro-racks®
Cage Filters	Remay nonwoven polyester sheets (Nationwide Papers, Washington, DC)
Animals per Cage	F ₀ --1 for males, 2 for females during breeding; 2 for males, 1 for females after breeding; F ₁ --3
Other Chemicals on Study in the Same Room	None
Animal Room Environment	Temp--23° ± 2° C; hum--50% ± 10%; fluorescent light 12 h/d; 10-15 room air changes/h
CHEMISTRY	
Supplier	Gouverneur Talc Company (Gouverneur, NY)

TABLE 4. EXPERIMENTAL DESIGN AND MATERIALS AND METHODS IN THE LIFETIME FEED STUDIES OF TREMOLITE (Continued)

FORMULATED DIETS

Preparation

Tremolite and feed mixed in a 55-ft³ Patterson-Kelly® V-blender with intensifier bar; oval, 3/8-in × 3/4-in pellets prepared with Sprout-Waldron pellet mill. Pelleted feed packaged in 25-lb aliquots in standard paper feed bags that were color coded to minimize the occurrence of feeding errors at the study laboratory

Source and Specifications of Study Animals

Parental Generation (F₀): Weanling F344/N (cesarean-derived) rats, which were barrier sustained and specific pathogen free, were purchased from Charles River Breeding Laboratories. These animals constituted the F₀ generation and were received November 1, 1977 (Figure 1).

On arrival, animals were taken directly to the quarantine area and acclimated to laboratory conditions. Twenty-four hours after arrival, eight rats of each sex were selected and killed, and pathogen burden was determined for each animal. Pathogens examined for included ectoparasites (mites, fleas, and lice), intestinal parasites (fecal flotation), and bacteria (*Mycoplasma* sp., *Salmonella* sp., *Diplococcus pneumoniae*, *Corynebacterium kutscheri*, and *Streptobacillus moniliformis*). Serologic tests were conducted for viruses (Appendix C, Tables C1-C3).

After approximately 2 months in quarantine (the regular 3- to 4-week quarantine period was extended because of a shortage of cages), male and female rats (15-16 weeks old) were separated into two groups (control and exposed) according to tables of random numbers and were placed on the appropriate designated diets.

After exposure to the designated diets for at least 7 days, the rats (16-17 weeks old) were placed in breeding cages (one male to two females). During the breeding period, the rats continued to be fed the same diets. Twenty days later (on the average), females were separated and housed individually in polycarbonate cages. Males were removed from the breeding cages and rehoused two per cage.

After the pups were born and placed on the lifetime feeding phase of the studies, ten rats (four males and six females) were selected from the F₀ generation for additional pathogen burden determinations (Tables C4-C6) to assure that the animals remained in acceptable health according to the infectious disease criteria.

Filial Generation (F₁): The F₀ females were allowed to deliver their F₁ litters naturally, and these were culled to groups of no more than eight pups (four per sex if possible) per litter.

At birth, the litters from the F₀ dams within the control and exposed groups were assigned randomly to the corresponding lifetime feeding phase groups (control and exposed) such that birth dates were equally distributed. Twenty-one days after birth, the pups were weaned, given a temporary number, and then assigned, according to a table of random numbers, to groups for the lifetime feed studies. Litters in which only one sex was present were excluded from those animals to be selected. At this time, 16 rats (8 rats per sex) were selected for pathogen burden determinations (Tables C7-C9). The extra weanlings were discarded.

Animal Maintenance

The control and tremolite-exposed rats were placed in separate rooms with monitored temperature and humidity and a controlled light cycle. Attempts were made to maintain the temperature at 74° ± 4° F and humidity at 50% ± 10%. Racks and filters were changed approximately once every 2 weeks. The rats were housed three per cage. Cages and bedding were replaced twice per week. Bedding samples were collected periodically for analysis (Appendix D). Control and formulated diets and tap water via

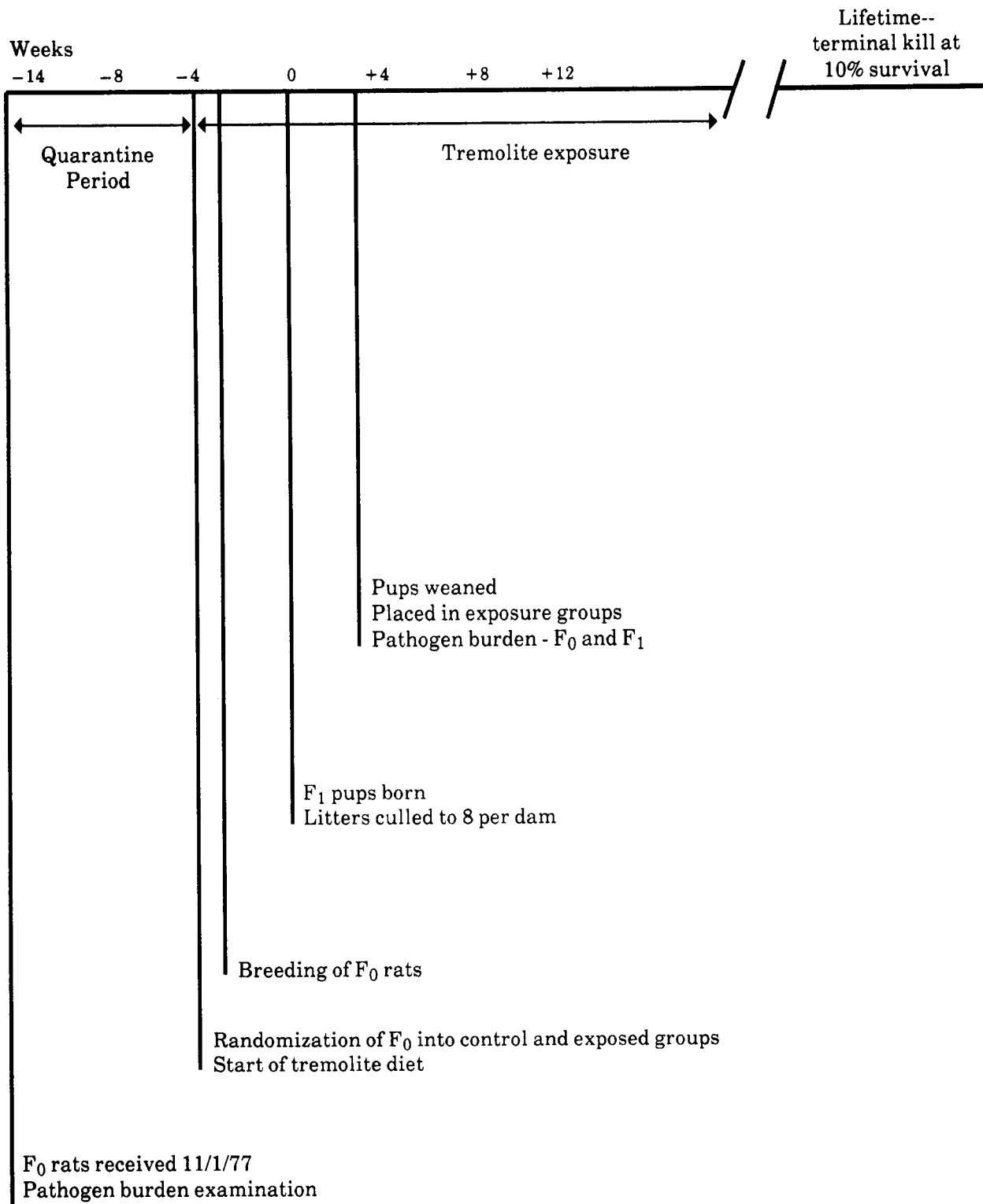


FIGURE 1. SCHEDULE OF MAJOR EVENTS IN RATS IN THE LIFETIME FEED STUDIES OF TREMOLITE

II. MATERIALS AND METHODS

automatic waterers were available ad libitum. Two water samples were collected and submitted for analysis of asbestos content (Appendix E). Stainless steel feed containers were changed once every 2 weeks. Sources and description of the materials used for animal maintenance are presented in Table 4.

Safety Precautions

The incoming air to the animal rooms was filtered to remove particulate matter. Ten to 15 changes of room air per hour were provided. Before initiation of the studies, air samples were collected and analyzed for baseline tremolite determinations. Additional samples were collected approximately every 6 months for analysis to assure personnel safety (Appendix F).

Other measures used for personnel protection included the wearing of fully protective disposable suits, gloves, boots, and bouffant caps and the use of a dust/mist respirator mask approved by the Occupational Safety and Health Administration. Personnel leaving the animal rooms were required to dispose of their protective clothing and to take showers. In addition, physical examinations, including pulmonary function tests and chest radiographs, were conducted at the initiation of the studies, once per year thereafter, and at the end of the studies.

Clinical Examinations and Pathology

Rats were observed two times per day. Body weights by cage were recorded once per week for the duration of the studies. Mean body weights were calculated for each group. Moribund animals were killed, as were animals that survived to the end of the studies. A necropsy was performed on all animals, including those found dead unless they were excessively autolyzed or cannibalized. Thus, the number of animals from which particular organs or tissues were examined microscopically varies and is not necessarily equal to the number of animals that were placed on study in each group. Animals were killed when exhibiting any one of these conditions:

1. Palpable masses within the abdominal cavity (excluding retained testes)
2. Masses protruding from the rectum

3. Rectal discharge of bright red fluid (an indication of the presence of a bleeding colonic or rectal neoplasm)
4. Large ulcerated masses in the area of the ears or on the side of the face (Zymbal gland tumors)
5. Large subcutaneous masses that were ulcerated or infected
6. Masses that interfered with breathing and eating or that severely hampered locomotion
7. Huge tissue masses
8. Central nervous system signs accompanied by weight loss (head tilt, circling, incoordination, ataxia, paralysis)
9. Severe weight loss or emaciation
10. Coma or extreme weakness

When the remaining animals of the tremolite-exposed group of either sex reached 10% of those starting the study, that group and the corresponding control group for that sex were killed. Animals were killed by exsanguination under sodium pentobarbital anesthesia (Nembutal®, Abbott Laboratories, Inc., North Chicago, IL, or Diabutal®, Diamond Laboratories, Inc., Des Moines, IA). Final body weights were recorded, and necropsies included blood smears taken from animals killed in extremis or those killed at the end of the studies and touch preparations made from any enlarged spleen or lymphoid organ.

The gastrointestinal tract, chosen as one of the target organs before these studies began, was handled in a slightly different manner than in standard long-term rodent carcinogenesis studies. Before being placed in fixative, the entire esophagus was opened and pinned with the exterior surface adjacent to cardboard. The stomach and cecum were prepared similarly. Two-centimeter lengths of duodenum and ileum and two portions of jejunum were placed unopened in fixative. The remaining small intestine was opened, washed gently with saline, and carefully examined by transillumination on a radiograph viewing box. Suspected lesions were processed separately and identified individually as to location. Likewise, the entire colon with anus was opened, examined, and pinned to cardboard (serosal surface down) before fixation. The size and location of masses were recorded. Masses

II. MATERIALS AND METHODS

greater than 1 mm in diameter were removed as separate specimens for processing. After fixation and before embedding, the colon was "carpet-rolled" starting at the posterior end, with the mucosal surface inward.

Examinations for grossly visible lesions were performed on major tissues or organs. Tissues were preserved in 10% neutral buffered formalin, embedded in paraffin, sectioned, and stained with hematoxylin and eosin. Tissues examined microscopically are listed in Table 4.

When the pathology examination was completed, the slides, individual animal data records, and summary tables were sent to an independent quality assurance laboratory. Individual animal records and tables were compared for accuracy, slides and tissue counts were verified, and histotechnique was evaluated. All tumor diagnoses, all target tissues, and all tissues from a randomly selected 10% of the animals were evaluated by a quality assurance pathologist. Slides of all target tissues and those about which the original and quality assurance pathologists disagreed were submitted to the Chairperson of the Pathology Working Group (PWG) for evaluation. Representative coded slides selected by the Chairperson were reviewed by PWG pathologists, who reached a consensus and compared their findings with the original and quality assurance diagnoses. When diagnostic differences were found, the PWG sent the appropriate slides and comments to the original pathologist for review. This procedure has been described, in part, by Maronpot and Boorman (1982) and Boorman et al. (1985). The final diagnoses represent a consensus of contractor pathologists and the NTP Pathology Working Group.

Statistical Methods

Data Recording: Data on this experiment were recorded in the Carcinogenesis Bioassay Data System (Linhart et al., 1974). The data elements include descriptive information on the chemicals, animals, experimental design, survival, body weight, and individual pathology results, as recommended by the International Union Against Cancer (Berenblum, 1969).

Survival Analyses: The probability of survival was estimated by the product-limit procedure of Kaplan and Meier (1958) and is presented in the form of graphs. Animals were censored from the survival analyses at the time they were found to be missing or dead from other than natural causes; animals dying from natural causes were not censored. Statistical analyses for a possible dose-related effect on survival used the method of Cox (1972) for testing two groups for equality. All reported P values for the survival analysis are two-sided.

Calculation of Incidence: The incidence of neoplastic or nonneoplastic lesions has been given as the ratio of the number of animals bearing such lesions at a specific anatomic site to the number of animals in which that site was examined. In most instances, the denominators include only those animals for which the site was examined histologically. However, when macroscopic examination was required to detect lesions (e.g., skin or mammary tumors) prior to histologic sampling, or when lesions could have appeared at multiple sites (e.g., lymphomas), the denominators consist of the number of animals on which a necropsy was performed.

Analysis of Tumor Incidence: Three statistical methods are used to analyze tumor incidence data: life table tests, incidental tumor analysis, and Fisher exact analysis. Tests of significance include pairwise comparisons of exposed groups with controls. For studies in which administration of the study compound has little effect on survival, the results of the three alternative analyses will generally be similar. When differing results are obtained by the three methods, the final interpretation of the data will depend on the extent to which the tumor under consideration is regarded as being the cause of death. Continuity-corrected tests are used in the analysis of tumor incidence, and reported P values are one-sided.

*Life Table Analyses--*The first method of analysis assumed that all tumors of a given type observed in animals dying before the end of the study were "fatal"; i.e., they either directly or indirectly caused the death of the animal. According to this approach, the proportions of

II. MATERIALS AND METHODS

tumor-bearing animals in the dosed and control groups were compared at each point in time at which an animal died with a tumor of interest. The denominators of these proportions were the total number of animals at risk in each group. These results, including the data from animals killed at the end of the study, were then combined by the method of Mantel and Haenszel (1959) to obtain an overall P value. This method of adjusting for intercurrent mortality is the life table method of Cox (1972). The underlying variable considered by this analysis is time to death due to tumor. If the tumor is rapidly lethal, then time to death due to tumor closely approximates time to tumor onset. In this case, the life table test also provides a comparison of the time-specific tumor incidences.

Incidental Tumor Analyses--The second method of analysis assumed that all tumors of a given type observed in animals that died before the end of the study were "incidental"; i.e., they were merely observed at necropsy in animals dying of an unrelated cause. According to this approach, the proportions of tumor-bearing animals in dosed and control groups were compared in each of five time intervals: weeks 0-60, weeks 61-86,

weeks 87-112, weeks 113-126, and beyond week 126. The denominators of these proportions were the number of animals actually examined for tumors during the time interval. The individual time interval comparisons were then combined by the previously described method to obtain a single overall result. (See Haseman, 1984, for the computational details of both methods.)

Fisher Exact Analysis--In addition to survival-adjusted methods, the results of the Fisher exact test for pairwise comparisons are given in the appendix containing the analyses of tumor incidence. This test is based on the overall proportion of tumor-bearing animals and does not adjust for survival differences.

Historical Control Data: Although the concurrent control group is always the first and most appropriate control group used for evaluation, there are certain instances in which historical control data can be helpful in the overall assessment of tumor incidence. Consequently, control tumor incidences from the NTP historical control data base (Haseman et al., 1984, 1985) are included for those tumors appearing to show compound-related effects.

III. RESULTS

Establishment of Study Groups

Pathogen Burden

Clinical Signs

Body Weights and Feed Consumption

Survival

Pathology and Statistical Analyses of Results

III. RESULTS

Establishment of Study Groups

The studies were designed to evaluate the effects of ingested tremolite during the entire life of the animal, starting from the time the rats were able to eat solid food. For this reason, the mated female rats had been on the study diets for approximately 12 weeks when the first litters were born. To minimize the chance that the mothers would reject or cannibalize their young, the litters were not handled during lactation except for weighing and culling at birth.

Litter size and survival of offspring were unaffected by the presence of tremolite in the diet. The average number of live fetuses born to tremolite-exposed dams was 7.6 vs. 7.8 for the control groups. The average weight at birth of the pups, determined by dividing the weight of each litter by the number of live pups, was 4.7 g for both groups. Fetal weights were determined by dividing the weight of each litter by the number of live pups. The tremolite-exposed offspring were smaller at weaning than were controls (22.8 g vs. 26.3 g).

A summary of groups, number of animals, diets for the parental (F_0) animals, as well as the distribution of and diets for the filial (F_1) animals is presented in Figure 1 and Table 4.

Pathogen Burden

The tissues of the F_0 animals evaluated for pathogen burden revealed evidence of early spontaneous respiratory disease in the lungs of all rats examined (Appendix C). In two of the males, only small foci of mononuclear cells were present adjacent to the bronchioles. In the remaining rats, minimal-to-moderate peribronchial lymphoid hyperplasia was present, and perivascular lymphoid hyperplasia occurred in two of these rats. In the repeated pathogen burden examination of the F_0 animals, evidence of respiratory disease was noted in all animals. This disease was characterized by minimal-to-moderate peribronchial lymphoid hyperplasia in all rats with an accompanying bronchial exudate in three males. These lesions were slightly more pronounced than those observed at an earlier kill.

In the lungs of all F_1 rats examined, evidence of early spontaneous respiratory disease was present, characterized by minimal-to-slight peribronchial lymphoid hyperplasia.

No serologic evidence of Sendai virus was present in either F_0 or F_1 animals (Appendix C).

Clinical Signs

A summary of clinical signs from weeks 83 to 112 is presented in Appendix G. This time period was chosen for illustration because few signs were noted before week 83 and age-related signs complicated the observations after week 112.

The incidence of clinical signs occurred at essentially similar frequencies in the tremolite-exposed and control rats throughout the studies. These include: soft feces; urine stains; pale, thin, and/or hunched appearance; depression; localized alopecia or sores on head or body; rough hair coats; abnormal eyes (pale, cloudy, bloody crust, red, lacrimating, squinting, enlarged, sores, swollen, red discharge, protruding, small, and/or necrotic); head tilt; salivation; localized swellings; stains on fur; bloated appearance; necrotic or abscessed tail; discharge from anus or vagina; protruding penis or vagina; small or enlarged testis; wheezing; wasting feed or decreased feed consumption; and labored respiration and/or abnormal central nervous system responses (circling, hyperactivity, loss of equilibrium, tremors, isolated occurrences of paralysis and/or ataxia).

As the study proceeded, the incidence of clinical signs increased in all groups. At intervals during which a large number of moribund animals were killed in any one particular group, the clinical signs most frequently observed were supportive of the conditions for moribund kills as outlined in the Materials and Methods section.

Body Weights and Feed Consumption

Mean body weights of rats in the lifetime feed studies, body weights relative to controls, and survival are presented in Table 5; mean body weights are also shown in Figure 2.

TABLE 5. MEAN BODY WEIGHTS AND SURVIVAL OF RATS IN THE LIFETIME FEED STUDIES OF TREMOLITE

Weeks on Study (from birth)	Control		1% Tremolite		
	Av. Wt. (grams)	No. of Survivors	Av. Wt. (grams)	Wt. (percent of controls)	No. of Survivors
MALE					
7	165	118	110	67	250
17	350	118	252	72	246
27	348	118	307	88	246
37	395	118	341	86	246
47	390	117	357	92	245
57	429	117	386	90	243
67	463	116	416	90	243
77	469	114	426	91	242
87	466	112	432	93	230
97	461	106	427	93	222
107	444	94	418	94	202
117	420	73	396	94	157
127	398	52	368	92	115
137	367	25	348	95	70
FEMALE					
7	126	118	105	83	250
17	182	118	166	91	250
27	199	117	185	93	250
37	220	117	199	90	247
47	224	117	214	96	247
57	251	116	233	93	246
67	281	116	265	94	245
77	303	115	277	91	243
87	323	110	298	92	236
97	323	106	295	91	219
107	330	94	303	92	197
117	320	78	293	92	153
127	316	53	286	91	116
137	299	35	264	88	59
147	283	14	255	90	22

Mean body weights were tabulated at 7 weeks after birth and every 10 weeks thereafter. The data revealed a 13% depressed mean body weight gain at weaning in exposed rats of each sex compared with the controls. The depression in body weight in the tremolite-exposed rats was most apparent at 7 weeks of age (33% for males and 17% for females); body weights then paralleled that of the controls for the remainder of the studies, remaining lower at all time points.

A summary of average weekly feed and compound consumption per rat and ratios for dosed

vs. control groups is given in Appendix H. In the tremolite-exposed male and female rats, the average weekly feed consumption was 96% that in the controls. Comparisons of the mean total feed consumption by control and exposed groups from the initiation of the studies through termination were generally similar, with no apparent trends. There was no apparent correlation between the decreased body weight gains in the exposed groups and the feed consumption values. The estimated amount of tremolite consumed per animal was 446 mg/kg per day for males and 528 mg/kg per day for females.

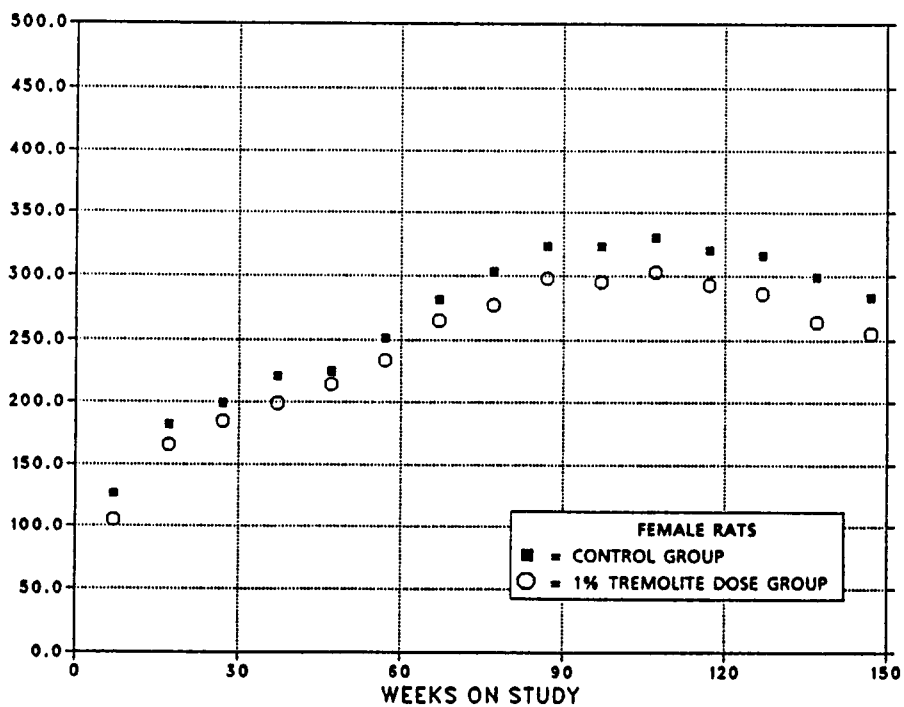
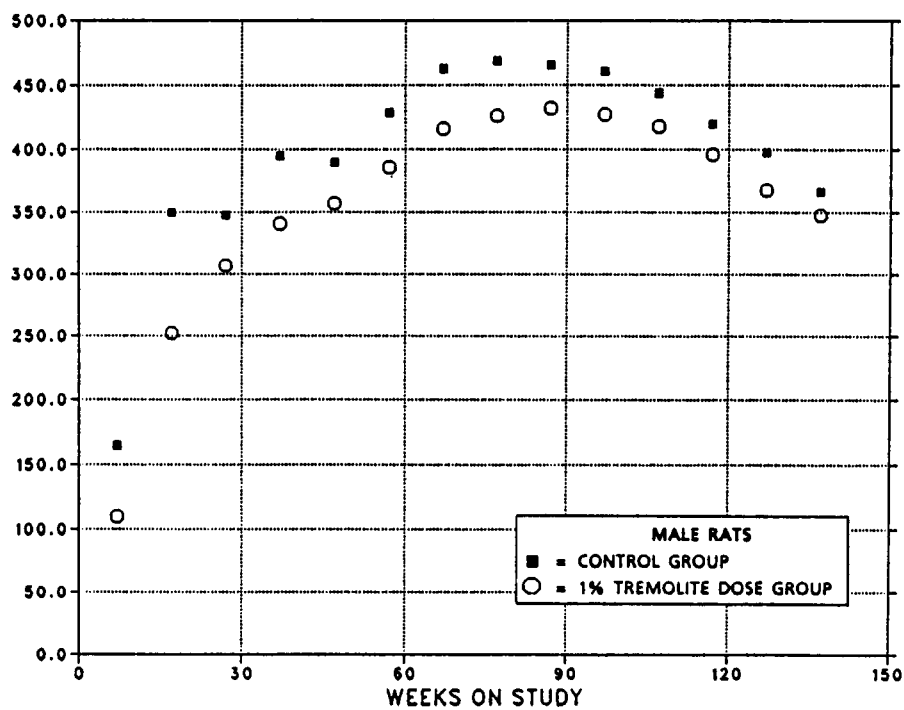


FIGURE 2. GROWTH CURVES FOR RATS FED DIETS CONTAINING 1% TREMOLITE IN LIFETIME STUDIES

Survival

Estimates of the probabilities of survival for male and female rats fed diets containing tremolite and for the controls are shown in the Kaplan and Meier curves in Figure 3. No significant differences in survival between the exposed and control groups were observed. Survival of males and females was approximately equal until week 112, after which a greater proportion of the females survived (Table 6).

Pathology and Statistical Analyses of Results

This section describes the statistically significant or biologically noteworthy changes in the incidences of rats with neoplastic or nonneoplastic

lesions, including monocytic (mononuclear cell) leukemia, endocrine tumors, testicular interstitial cell tumors, skin neoplasms, and mammary gland neoplasms. Only positive histopathologic findings based on hematoxylin- and eosin-stained sections are tabulated in the text. A few tissues were missing from occasional animals. Also, no diagnoses are given for several tissues in one exposed female rat because of autolysis.

Summaries of the incidences of neoplasms and nonneoplastic lesions, individual animal tumor diagnoses, statistical analyses of primary tumors that occurred with an incidence of at least 2% in at least one animal group, and historical control incidences for the neoplasms mentioned in this section are presented in Appendixes A and B for male and female rats, respectively.

TABLE 6. SURVIVAL OF RATS IN THE LIFETIME FEED STUDIES OF TREMOLITE AT VARIOUS TIME POINTS AFTER WEEK 90

Group	Week	Male		Female	
		Number Alive/ Total Number	Percent Survival	Number Alive/ Total Number	Percent Survival
Control	90	112/118	95	110/118	93
	112	77/118	65	85/118	72
	130	42/118	36	48/118	41
	146	5/118	4	17/118	14
	148	--	--	13/118	11
Exposed	90	228/250	91	231/250	92
	112	177/250	71	174/250	70
	130	95/250	38	88/250	35
	146	35/250	14	28/250	11
	148	--	--	22/250	9

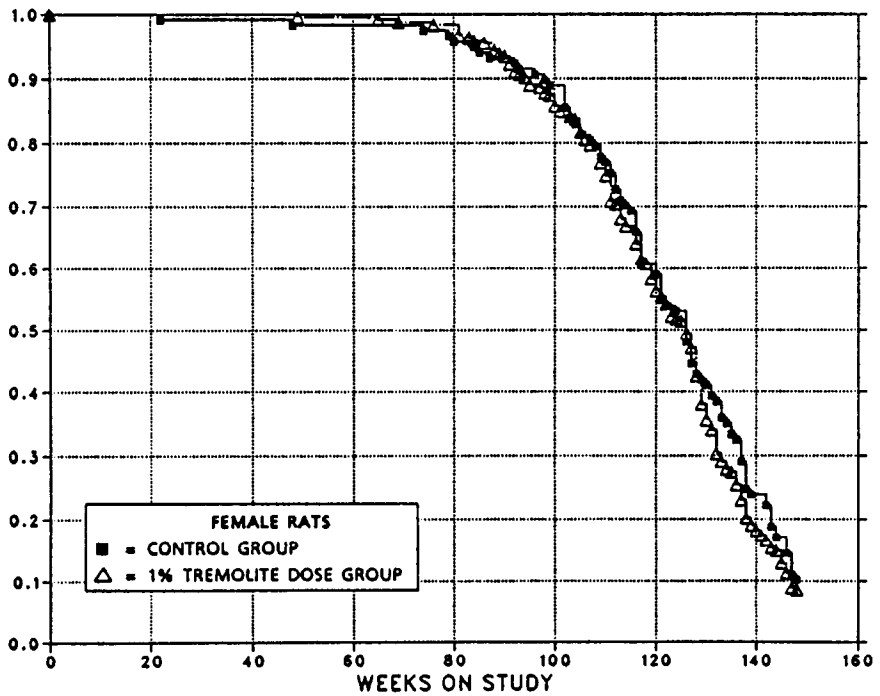
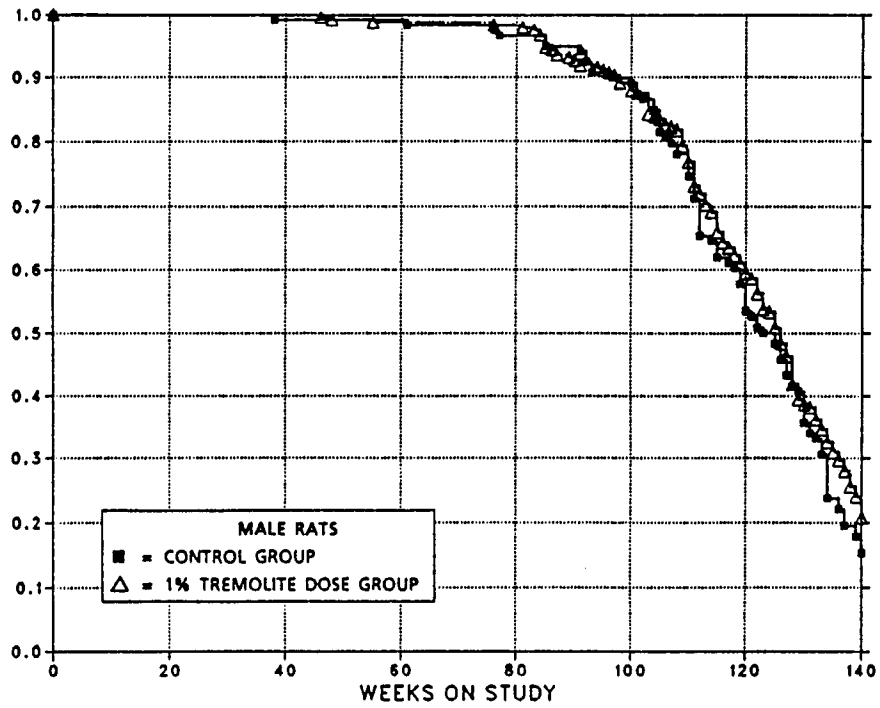


FIGURE 3. KAPLAN-MEIER SURVIVAL CURVES FOR RATS FED DIETS CONTAINING 1% TREMOLITE IN LIFETIME STUDIES

Neoplasms

Table 7 summarizes the incidence of neoplasia in exposed and control male and female rats. No obvious differences were found in the total incidence of tumors or in the total incidence of benign or malignant tumors. Also, the average number of tumors per animal does not appear to be related to exposure.

Stomach Neoplasms: Squamous cell papillomas occurred in the forestomach (nonglandular) and appeared as exophytic growths of thickened epithelium resting on a proliferative connective tissue stalk. Squamous cell carcinomas also occurred in the forestomach and were composed of proliferating small basophilic squamous cells that were growing down into the lamina propria and occasionally formed keratin pearls.

Intestinal Tract Neoplasms: The primary epithelial neoplasms in the tremolite studies were divided by the original pathologist into three major types, based on morphology and biologic behavior: adenomatous polyps, adenocarcinomas arising in an adenomatous polyp, and carcinomas.

*Adenomatous polyps--*The adenomatous polyps were exophytic lesions of the mucosa supported on a pedicle of fibrous tissue and/or elevated submucosa which appeared to extend up into the growth. The epithelial cells were usually deeply basophilic and hypertrophic and formed glands of varying sizes. Surface necrosis of these

lesions was common and often accompanied by an inflammatory response. Invasion of the pedicle was not observed. These polyps often occurred as multiple neoplasms in the large intestine.

*Adenocarcinomas arising in adenomatous polyps--*These neoplasms were exophytic lesions of the mucosa composed of proliferating deeply basophilic hypertrophic epithelial cells similar to those described above. In addition, they often showed disorganization, loss of relationship to the basement membrane, and abnormal mitoses. Local invasion of the pedicle was a consistent finding; however, metastases were rarely observed.

*Carcinomas--*This classification includes signet ring cell carcinomas, adenocarcinomas, mucinous cystadenocarcinomas, and carcinomas. Biologically, all are similar and are usually characterized by transmural growth that penetrates the muscular tunics and serosa and spread throughout the coelomic cavity, inducing a severe desmoplastic response. Metastasis to regional lymph nodes was common; metastasis to the lung and mediastinum occurred to a lesser extent. Grossly, in advanced cases, the loops of intestines were fused into an inseparable mass of tumor and desmoplastic tissue. Classification was based on the most prominent feature at the primary site. Signet ring carcinomas are composed of masses of clear oval cells with eccentric nuclei. Mucinous cystadenocarcinomas are characterized by the formation of multiple large

TABLE 7. INCIDENCE OF PRIMARY NEOPLASMS IN RATS IN THE LIFETIME FEED STUDIES OF TREMOLITE

	Male		Female	
	Control	1% Tremolite	Control	1% Tremolite
No. of animals examined	118	250	118	250
Total animals with primary tumors	117 (99%)	241 (96%)	115 (97%)	243 (97%)
Total primary tumors	(a) 423 (3.6)	(a) 844 (3.5)	(a) 342 (3.0)	(a) 633 (2.6)
Total animals with benign tumors	115 (97%)	238 (95%)	100 (85%)	201 (80%)
Total benign tumors	(a) 266 (2.3)	(a) 526 (2.2)	(a) 192 (1.9)	(a) 356 (1.8)
Total animals with malignant tumors	96 (81%)	199 (80%)	96 (81%)	188 (75%)
Total malignant tumors	(a) 147 (1.5)	(a) 309 (1.6)	(a) 145 (1.5)	(a) 264 (1.4)

(a) Average number of tumors per tumor-bearing animal is in parentheses.

III. RESULTS

ectatic glands or spaces that were filled with mucus and cellular debris. Adenocarcinomas consist of clusters of cells and/or glands in pools of mucus or sequestered in desmoplastic tissue. The carcinomas are anaplastic neoplasms lacking acinar formations. In some cases, there is an overlap of cell types in the same tumor, suggesting that the above morphologic types probably have the same histogenesis.

A few mesenchymal neoplasms of fibrous connective tissue or smooth muscle origin also were observed in the gastrointestinal tract. The incidences of these and of epithelial neoplasms are shown in Table 8. No statistically significant differences ($P < 0.05$) between the control and exposed groups were observed. The apparent increased trend in mesenchymal neoplasms (4 vs. 0) in male rats was discounted because these lesions were composed of one connective tissue neoplasm, two smooth muscle neoplasms, and one sarcoma of unknown origin. Evaluation of the

incidence of the three categories of epithelial intestinal neoplasia by site and week of occurrence within the alimentary tract does not indicate any significant ($P < 0.05$) compound-related effect (Tables 9 and 10), although a positive trend is suggested in the small and large intestine of male rats. This becomes more apparent when the neoplasms are divided into benign and malignant categories.

In addition, the incidences of nonneoplastic lesions of the gastrointestinal tract, such as enteritis, ulceration, and inflammation, were generally similar in the control and tremolite-exposed rats (Table 11).

Miscellaneous Neoplasms: Occasionally, somewhat greater or lower incidences of commonly occurring neoplasms were observed in exposed groups, but these changes were not regarded as being chemically related (Table 12).

TABLE 8. INCIDENCE OF GASTROINTESTINAL TRACT NEOPLASMS IN RATS IN THE LIFETIME FEED STUDIES OF TREMOLITE

	Male		Female	
	Control	1% Tremolite	Control	1% Tremolite
No. of animals examined	118	250	118	250
Total animals with neoplasms	4 (3.4%)	13 (5.2%)	5 (4.2%)	3 (1.2%)
Total animals with epithelial neoplasms	4 (3.4%)	9 (3.6%)	1 (0.8%)	1 (0.4%)
Total animals with mesenchymal neoplasms	0 (0%)	4 (1.6%)	4 (3.4%)	2 (0.8%)

TABLE 9. NUMBERS OF RATS WITH PRIMARY ALIMENTARY TRACT EPITHELIAL NEOPLASMS IN THE LIFETIME FEED STUDIES OF TREMOLITE

Site/Neoplasm	Male		Female	
	Control	1% Tremolite	Control	1% Tremolite
Number of animals examined	118	250	118	250
Total alimentary	7 (6%)	11 (4%)	2 (2%)	6 (2%)
Oral/pharynx				
Papilloma	1 (1%)	0 (0%)	0 (0%)	1 (0.4%)
Carcinoma	2 (2%)	2 (1%)	1 (1%)	4 (2%)
Esophagus				
No lesions	0 (0%)	0 (0%)	0 (0%)	0 (0%)
Total gastrointestinal	4 (3%)	9 (3%)	1 (1%)	1 (0.4%)
Total stomach	3 (3%)	2 (1%)	0 (0%)	0 (0%)
Nonglandular				
Papilloma	2 (2%)	1 (0.4%)	0 (0%)	0 (0%)
Carcinoma	1 (1%)	1 (0.4%)	0 (0%)	0 (0%)
Glandular				
Polyp	0 (0%)	0 (0%)	0 (0%)	0 (0%)
Carcinoma	0 (0%)	0 (0%)	0 (0%)	0 (0%)
Total small intestine	0 (0%)	3 (1%)	1 (1%)	0 (0%)
Polyp	0 (0%)	1 (0.4%)	1 (1%)	0 (0%)
Polyp/carcinoma	0 (0%)	0 (0%)	0 (0%)	0 (0%)
Carcinoma	0 (0%)	2 (1%)	0 (0%)	0 (0%)
Total large intestine	1 (1%)	4 (2%)	0 (0%)	1 (0.4%)
Cecum				
Polyp	0 (0%)	1 (0.4%)	0 (0%)	0 (0%)
Polyp/carcinoma	0 (0%)	0 (0%)	0 (0%)	0 (0%)
Carcinoma	0 (0%)	0 (0%)	0 (0%)	0 (0%)
Colon				
Polyp	1 (1%)	1 (0.4%)	0 (0%)	0 (0%)
Polyp/carcinoma	0 (0%)	0 (0%)	0 (0%)	1 (0.4%)
Carcinoma	0 (0%)	2 (1%)	0 (0%)	0 (0%)

TABLE 10. WEEK OF OCCURRENCE OF GASTROINTESTINAL TRACT EPITHELIAL NEOPLASMS IN RATS IN THE LIFETIME FEED STUDIES OF TREMOLITE

Site/Neoplasm	Male		Female	
	Control	1% Tremolite	Control	1% Tremolite
Stomach (forestomach)				
Squamous cell papilloma	125, 143	109	--	--
Squamous cell carcinoma	145	146	--	--
Duodenum				
Mucinous cystadenocarcinoma	--	130	--	--
Ileum				
Adenomatous polyp	--	138	--	--
Jejunum				
Adenomatous polyp	--	--	121	--
Mucinous cystadenocarcinoma	--	119	--	--
Cecum				
Adenomatous polyp	--	138	--	--
Colon (ascending)				
Adenomatous polyp	--	128	--	--
Mucinous cystadenocarcinoma	--	86	--	--
Colon (descending)				
Adenocarcinoma arising in adenomatous polyp	--	--	--	111
Colon (transverse)				
Adenomatous polyp	126	--	--	--
Mucinous cystadenocarcinoma	--	110	--	--

TABLE 11. INCIDENCE OF NONNEOPLASTIC LESIONS IN THE ALIMENTARY TRACT IN RATS IN THE LIFETIME FEED STUDIES OF TREMOLITE

	Male		Female	
	Control	1% Tremolite	Control	1% Tremolite
Number of animals examined	118	250	118	250
Palate/tongue				
Inflammation	0 (0%)	0 (0%)	0 (0%)	4 (2%)
Necrosis	0 (0%)	0 (0%)	0 (0%)	1 (0.4%)
Hyperkeratosis	0 (0%)	1 (0.4%)	0 (0%)	2 (1%)
Acanthosis	1 (1%)	3 (1%)	1 (1%)	1 (0.4%)
Esophagus				
Inflammation	1 (1%)	0 (0%)	0 (0%)	1 (0.4%)
Necrosis	2 (2%)	1 (0.4%)	0 (0%)	0 (0%)
Hyperkeratosis	9 (8%)	18 (7%)	3 (3%)	4 (2%)
Acanthosis	1 (1%)	0 (0%)	0 (0%)	1 (0.4%)
Nonglandular stomach				
Mineralization	10 (8%)	4 (2%)	4 (3%)	2 (1%)
Inflammation, chronic	19 (16%)	39 (16%)	25 (21%)	38 (15%)
Ulceration	10 (8%)	17 (7%)	9 (8%)	11 (4%)
Necrosis	19 (16%)	46 (18%)	17 (14%)	31 (12%)
Hyperplasia	2 (2%)	1 (0.4%)	0 (0%)	2 (1%)
Hyperkeratosis	17 (14%)	34 (14%)	15 (13%)	29 (12%)
Acanthosis	26 (22%)	54 (22%)	23 (19%)	45 (18%)
Glandular stomach				
Hyperplasia	7 (6%)	1 (0.4%)	3 (3%)	0 (0%)
Small intestine				
Inflammation	0 (0%)	2 (1%)	0 (0%)	1 (0.4%)
Necrosis	2 (2%)	1 (0.4%)	1 (1%)	3 (1%)
Ulceration	0 (0%)	1 (0.4%)	0 (0%)	0 (0%)
Colon				
Parasitism	5 (4%)	32 (13%)	5 (4%)	2 (1%)
Inflammation	0 (0%)	5 (2%)	3 (3%)	0 (0%)
Necrosis	0 (0%)	3 (1%)	1 (1%)	1 (0.4%)
Hyperplasia	0 (0%)	1 (0.4%)	0 (0%)	1 (0.4%)
Cecum				
Parasitism	0 (0%)	2 (1%)	2 (2%)	1 (0.4%)
Inflammation	1 (1%)	2 (1%)	4 (4%)	1 (0.4%)
Necrosis	1 (1%)	4 (2%)	1 (1%)	3 (1%)
Hyperplasia	0 (0%)	0 (0%)	0 (0%)	1 (0.4%)
Rectum				
Necrosis	0 (0%)	1 (0.4%)	0 (0%)	0 (0%)
Anus				
No lesions				

TABLE 12. INCIDENCE OF PRIMARY NEOPLASMS IN RATS IN THE LIFETIME FEED STUDIES OF TREMOLITE (a)

Site/Lesion	Male		Female	
	Control	1% Tremolite	Control	1% Tremolite
Skin	118	250	118	250
Squamous cell papilloma	3 (3%)	9 (4%)	1 (1%)	7 (3%)
Squamous cell carcinoma	2 (2%)	4 (2%)	0 (0%)	1 (0.4%)
Basal cell carcinoma	4 (3%)	8 (3%)	0 (0%)	0 (0%)
Keratoacanthoma	6 (5%)	13 (5%)	0 (0%)	2 (1%)
Integumentary system	118	250	118	250
Fibroma	14 (12%)	36 (14%)	6 (5%)	10 (4%)
Fibrosarcoma	3 (3%)	12 (5%)	2 (2%)	5 (2%)
Neurofibroma	2 (2%)	6 (2%)	3 (3%)	2 (1%)
Lung	118	250	118	250
Alveolar/bronchiolar carcinoma	2 (2%)	2 (1%)	3 (3%)	2 (1%)
Hematopoietic system	118	250	118	250
Leukemia	43 (36%)	102 (41%)	56 (47%)	101 (40%)
Lymphoma	5 (4%)	(b) 1 (0.4%)	2 (2%)	1 (0.4%)
Circulatory system	118	250	118	250
Hemangiosarcoma	2 (2%)	8 (3%)	1 (1%)	1 (0.4%)
Liver	118	250	118	250
Neoplastic nodule	10 (8%)	(b) 8 (3%)	2 (2%)	10 (4%)
Hepatocellular carcinoma	6 (5%)	(c) 6 (2%)	0 (0%)	0 (0%)
Pancreas	118	250	118	250
Acinar cell adenoma	10 (8%)	22 (9%)	0 (0%)	3 (1%)
Mixed tumor, benign	3 (3%)	3 (1%)	0 (0%)	0 (0%)
Kidney	118	250	118	250
All tumors	2 (2%)	8 (3%)	0 (0%)	5 (2%)
Pituitary gland	118	247	117	248
Adenoma	20 (17%)	37 (15%)	51 (44%)	93 (38%)
Carcinoma	2 (2%)	4 (2%)	5 (4%)	11 (4%)
Adrenal gland	118	250	118	250
Cortical adenoma	1 (1%)	2 (1%)	9 (8%)	13 (5%)
Pheochromocytoma, benign	38 (32%)	(c) 62 (25%)	22 (19%)	32 (13%)
Pheochromocytoma, malignant	3 (3%)	7 (3%)	1 (1%)	4 (2%)
Thyroid gland	117	247	118	250
Follicular cell adenoma	5 (4%)	12 (5%)	3 (3%)	7 (3%)
Follicular cell carcinoma	6 (5%)	13 (5%)	5 (4%)	15 (6%)
C-Cell adenoma	11 (9%)	22 (9%)	7 (6%)	8 (3%)
C-Cell carcinoma	16 (14%)	48 (19%)	18 (15%)	41 (16%)
Parathyroid	109	236	113	238
Adenoma	2 (2%)	4 (2%)	1 (1%)	0 (0%)
Pancreatic islets	118	250	118	250
Islet cell adenoma	5 (4%)	12 (5%)	5 (4%)	8 (3%)
Islet cell carcinoma	7 (6%)	11 (4%)	3 (3%)	6 (2%)
Mammary gland	118	250	118	250
All tumors	20 (17%)	37 (15%)	70 (59%)	140 (56%)
Adenoma	1 (1%)	1 (0.4%)	2 (2%)	4 (2%)
Adenocarcinoma	2 (2%)	3 (1%)	24 (20%)	(b) 21 (8%)
Fibroadenoma	17 (14%)	(c) 32 (13%)	62 (53%)	127 (51%)

TABLE 12. INCIDENCE OF PRIMARY NEOPLASMS IN RATS IN THE LIFETIME FEED STUDIES OF TREMOLITE (Continued)

Site/Lesion	Male		Female	
	Control	1% Tremolite	Control	1% Tremolite
Preputial/clitoral gland Squamous cell carcinoma	118 6 (5%)	250 14 (6%)	118 6 (5%)	250 15 (6%)
Testis Interstitial cell tumor	118 114 (97%)	250 (c) 237 (95%)		
Uterus Endometrial stromal polyp			118 15 (13%)	249 28 (11%)
Ovary Granulosa cell tumor			118 3 (3%)	249 3 (1%)
Brain Astrocytoma	118 7 (6%)	250 (c) 6 (2%)	118 1 (1%)	250 2 (1%)
Zymbal gland Squamous cell carcinoma	118 3 (3%)	250 9 (4%)	118 3 (3%)	250 6 (2%)
All sites Malignant mesothelioma	118 10 (8%)	250 (b) 8 (3%)	118 0 (0%)	250 0 (0%)

(a) Incidence of all neoplasms (other than those in the alimentary tract) that occurred at an incidence of 2% or more in at least one group

(b) $P < 0.05$ (decrease) relative to controls

(c) $P < 0.05$ (decrease) relative to controls (life table test only)

Nonneoplastic Findings

A plethora of incidental lesions of aging was found in all groups. Statistical analyses showed no obvious correlation between the incidence of

specific lesion types and compound exposure. Histopathologic findings are summarized in Appendixes A and B. Nonneoplastic lesions that were observed in more than 5% of the rats in any of the study groups are shown in Table 13.

TABLE 13. NONNEOPLASTIC LESIONS OBSERVED IN MORE THAN 5% OF RATS IN THE LIFETIME FEED STUDIES OF TREMOLITE

Lung: chronic inflammation, hemorrhage, alveolar hyperplasia
Spleen: fibrosis, hemosiderosis, extramedullary hematopoiesis
Lymph nodes (various): lymphoid or reticulum cell hyperplasia, lymphangiectasis, pigmentation, hemorrhage
Heart: thrombosis, chronic inflammation
Liver: degeneration, necrosis, fatty metamorphosis, toxic hepatitis, granulomas, pigmentation, focal cellular change
Bile duct (extrahepatic): chronic inflammation, mucosal hyperplasia
Pancreas (exocrine): atrophy, hyperplasia
Kidney: chronic progressive nephropathy, cysts, pigmentation
Pituitary gland: cysts, angiectasis, hyperplasia
Adrenal gland (cortex): fatty metamorphosis, hyperplasia
Adrenal gland (medulla): hyperplasia
Thyroid gland: follicular cysts, C-cell hyperplasia
Parathyroid: hyperplasia
Testis: seminiferous degeneration, interstitial cell hyperplasia
Prostate: abscess, chronic inflammation, glandular hyperplasia
Seminal vesicles: cysts
Preputial gland: inflammation
Ovary: follicular cysts
Uterus: hydrometra, endometrial cysts
Mammary gland: cystic ducts, galactocele, inflammation
Mesentery: fat necrosis
Eye: cataract, hemorrhage, inflammation, retinal degeneration, rupture of the lens, posterior synechia
Zymbal gland: cystic ducts
Bone: osteopetrosis
Bone marrow: hyperplasia, hypoplasia

IV. DISCUSSION AND CONCLUSIONS

IV. DISCUSSION AND CONCLUSIONS

Tremolite was administered at a concentration of 1% in the diet to male and female F344/N rats for their lifetime; the dams were exposed before and during gestation. Although the natural form of tremolite used in these studies is considered crystalline or nonfibrous, a small amount assumes a fibrous character during the crushing and milling processes. The milling process used in the preparation of the tremolite for these studies was identical to that used commercially.

The clinicopathologic results showed that the ingestion of tremolite did not adversely affect the fertility of the mothers or the litter size of the F₁ animals. However, the average weight of the offspring at weaning from mothers exposed to tremolite during gestation and lactation was about 13% less than that of the offspring of non-exposed mothers. This effect was not due to in utero exposure to tremolite, since birth weights of the tremolite-exposed pups were similar to those of concurrent controls. Body weight gain differences became more apparent by 8 weeks of age, after which body weights of the tremolite-exposed rats paralleled those of the control rats, even though the exposed rats remained smaller throughout their life. The decreased body weight gain was not related to a decrease in food consumption, and therefore the reason for this effect is not known. The decrease in weight gain was not considered a toxic effect because lifespan was not altered and no compound-related lesions were observed.

No clinical signs were observed which could be attributed to the ingestion of tremolite. Also, the ingestion of 1% tremolite in the diet for the lifespan of the rats did not affect survival. In fact, survival of both male and female rats exposed to tremolite was almost identical to that of the control groups. The survival of the rats (control and exposed) in the current studies compares favorably with that in other long-term studies in the NTP program (Haseman, 1983). At 112 weeks of age (average age of rats at the end of a typical 2-year study), the percentages of rats alive in the current studies were as follows: male control, 65%; exposed male, 71%; control female, 72%; exposed female, 70%. In reviewing 25 NTP feed studies, Haseman (1983) found an average 66% of control males and 73% of control females alive at 112 weeks of age.

The survival of males was similar to that of females at 112 weeks of age. However, in most 2-year studies involving rats, females usually live longer than males. This was the case for the tremolite study, since after 146 weeks, better survival was observed in control females than in males. Based on these observations, it is clear that the maximum tolerated concentration was not exceeded. Possibly, the rats in these studies could have tolerated exposure at a higher concentration, although a dietary concentration of 1% for the entire life of the animal is considered substantial.

Ingestion of tremolite over the lifetime of these rats did not cause a significant ($P < 0.05$) increase in the number of neoplasms per animal or any increase in neoplasms at any particular anatomic site compared with the concurrent controls. Since the gastrointestinal tract was considered a target organ based on epidemiologic studies on asbestos exposure in humans (Cooper et al., 1979) and because tremolite was administered in the diet, the gastrointestinal tract in control and exposed rats was examined in particular detail. Overall, the incidence was low, and no significant ($P < 0.05$) differences were observed between the exposed and control groups for any anatomic site within the gastrointestinal tract. When the incidence of neoplasms of the glandular epithelium of the large and small intestines of male rats was examined, 7/250 (3%) tremolite-exposed animals had such neoplasms compared with 1/118 (1%) controls. If only malignant neoplasms of this tissue are evaluated, the incidence is 0/118 male controls and 4/250 male tremolite-exposed rats. Based on these data, it might appear that tremolite is a potential intestinal carcinogen for rats. However, the incidence (2%) of epithelial intestinal neoplasms in the control male F344/N rats in the amosite asbestos study (a corollary study to the current one) (NTP, 1990b) was similar to that in the tremolite-exposed males.

The historical incidence of intestinal neoplasia in control male F344 rats in feed studies is 0.9% (13/1,477). The reasons the historical incidence is lower than in this study are: the tremolite study was a lifetime study, rather than the standard 2-year exposure study; and the gastrointestinal tract from rats in the tremolite study

IV. DISCUSSION AND CONCLUSIONS

was examined much more carefully (i.e., transillumination and "carpet-rolling").

The morphologic appearance of the gastrointestinal neoplasms in the tremolite-exposed rats was similar to that observed in the control rats. In addition, the morphology was similar to that in neoplasms that occur in control rats (Pozharisski, 1973) or that are observed as the result of exposure to known intestinal carcinogens (Pozharisski, 1975).

In summary, these studies do not provide evidence for the carcinogenicity of tremolite after lifetime ingestion. A large variety of nonneoplastic lesions, primarily age related, was observed in all groups. There was no obvious correlation between exposure and specific lesions. Therefore, tremolite at a concentration of 1% in the diet did not appear to be toxic.

No other studies on the effects of long-term ingestion of tremolite are available. However, Stanton et al. (1981) showed that the intrapleural inoculation of two types of fibrous tremolite caused a high incidence of pleural sarcoma in Osborne-Mendel rats. In contrast, intrapleural studies of tremolite talc failed to show a carcinogenic response in hamsters (Smith, 1974). In similar studies, Wagner et al. (1982) found fibrous tremolite, but not the nonfibrous form, to be carcinogenic. They also considered the carcinogenic response to be correlated to the mineral's ability to induce *in vitro* cytotoxicity, enzyme release in mouse peritoneal macrophages, and giant cell formation in A549 cell cultures. The tremolite used in the NTP studies is a nonfibrous type and more closely resembles that used by Smith (1974) and Wagner et al. (1982).

Studies involving the long-term ingestion of asbestos are also few. Donham et al. (1980) reported equivocal results in F344 rats that were fed a diet containing 10% chrysotile for their lifetime. Although no significant ($P < 0.05$) increase in the number of tumors in exposed animals was observed, the authors believed that there was a trend towards increased colon lesions in general, evidence of penetration of asbestos into the colonic mucosa, and possible cytotoxicity to colonic tissues; they also suggested a

relationship to peritoneal mesothelioma. Another equivocal study was reported by Gibel et al. (1976), who described an increase in malignant tumors in the lung, kidney, liver, and reticuloendothelial system, but no increase in intestinal neoplasia, in Wistar rats fed asbestos filter material (20 mg per day) for 8-14 months. Cunningham et al. (1977) reported one 24-month study and one 30-month study in male Wistar rats fed diets containing 1% chrysotile asbestos for 24 or 30 months. These authors concluded that trace amounts of ingested asbestos can penetrate the walls of the gastrointestinal tract but that evidence of carcinogenicity was inconclusive. No evidence of carcinogenicity was found by Gross et al. (1974), who fed rats diets containing 5% chrysotile asbestos for 21 months.

An oral asbestos study in hamsters was reported by Smith et al. (1980). Groups of 30 male and 30 female hamsters were exposed via drinking water for their lifetime to amosite asbestos, mine tailings, beach rock, or Lake Superior drinking water. No adverse effects on body weight or survival were observed in any of the groups. One peritoneal mesothelioma, one pulmonary carcinoma, and two squamous cell carcinomas of the nonglandular stomach were found in hamsters exposed to amosite, but the incidence was not statistically significant ($P < 0.05$). A subsequent study in rats using similar materials also failed to elicit a carcinogenic response (Hilding et al., 1981). In companion studies to this investigation, Syrian golden hamsters were exposed to either amosite asbestos (NTP, 1985b) or to short-range (fiber length) or intermediate-range chrysotile asbestos (NTP, 1990a) at a concentration of 1% in the diet for their natural lifespan. In both studies, no adverse effects were observed for body weight gain or survival and no asbestos-related neoplasms were diagnosed.

Except for the studies of Donham et al. (1980), Smith et al. (1980), and the NTP (1985b, 1990a), the other studies were conducted with relatively small numbers of animals. Also, some were conducted for an insufficient period of time to adequately test the carcinogenic potential of ingested asbestos.

IV. DISCUSSION AND CONCLUSIONS

The laboratory records and data for the NTP Technical Report on tremolite were examined for accuracy, consistency, and completeness. The audit revealed no major problems with the conduct of the studies or with collection and documentation of the experimental data. The audit report was reviewed by NTP staff, who determined that none of the discrepancies influenced the final interpretation of the results of these

studies. The audit report is on file at the NIEHS/NTP Quality Assurance Office and is available for review.

Under the conditions of these feed studies, non-fibrous tremolite was not overtly toxic or carcinogenic for male or female F344/N rats, following lifetime ingestion of a diet containing 1% tremolite.

V. REFERENCES

V. REFERENCES

1. Berenblum, I., Ed. (1969) Carcinogenicity Testing: A Report of the Panel on Carcinogenicity of the Cancer Research Commission of UICC, Vol. 2. Geneva: International Union Against Cancer.
2. Bey, E.; Harrington, J.S. (1971) Cytotoxic effects of some mineral dusts on Syrian hamster peritoneal macrophages. *J. Exp. Med.* 133:1149-1169.
3. Boorman, G.A.; Montgomery, C.A., Jr.; Eustis, S.L.; Wolfe, M.J.; McConnell, E.E.; Hardisty, J.F. (1985) Quality assurance in pathology for rodent carcinogenicity studies. Milman, H.; Weisburger, E., Eds.: *Handbook of Carcinogen Testing*. Park Ridge, NJ: Noyes Publications, pp. 345-357.
4. Bureau of Mines (1980) Report No. 8452. U.S. Department of the Interior, Supt. of Documents, No. RI 28.23.
5. Carter, R.E.; Taylor, W.G. (1980) Identification of a particular amphibole asbestos fiber in tissues of persons exposed to a high oral intake of the mineral. *Environ. Res.* 21:85-93.
6. Chamberlain, M.; Tarmy, E.M. (1977) Asbestos and glass fibers in bacterial mutation tests. *Mutat. Res.* 43:159-164.
7. Cook, P.M.; Olson, G.F. (1979) Ingested mineral fibers: Elimination in human urine. *Science* 204:195-198.
8. Cooper, R.C.; Murchio, J.C.; Paffenbarger, R.S. (1979) Asbestos in Domestic Water Supplies for Five California Counties. Part II. EHS Pub. No. 79-1. Division of Environmental Health Sciences, School of Public Health, University of California, Berkeley.
9. Cox, D.R. (1972) Regression models and life tables. *J. R. Stat. Soc.* B34:187-220.
10. Craighead, J.E.; Mossman, B.T. (1982) The pathogenesis of asbestos-associated disease. *N. Engl. J. Med.* 306:1446-1455.
11. Cunningham, H.M.; Moodie, C.A.; Lawrence, G.A.; Pontefract, R.D. (1977) Chronic effects of ingested asbestos in rats. *Arch. Environ. Contam. Toxicol.* 6:507-513.
12. Donham, K.J.; Berg, J.W.; Will, L.A.; Leininger, J.R. (1980) The effects of long-term ingestion of asbestos on the colon of F344 rats. *Cancer* 45:1073-1084.
13. *Environmental Health Perspectives (EHP)* (1974) Proceedings of the Joint NIEHS-EPA Conference on Biological Effects of Ingested Asbestos. 9:113-462.
14. Gart, J.J.; Chu, K.C.; Tarone, R.E. (1979) Statistical issues in interpretation of chronic bioassay tests for carcinogenicity. *J. Natl. Cancer Inst.* 62:957-974.
15. Gibel, W.; Lohs, K.H.; Horn, K.H.; Wildner, G.P.; Hoffman, F. (1976) Investigation into a carcinogenic effect of asbestos filter materials following oral intake in experimental animals. *Arch. Geschwulstforsch.* 46:437-442.
16. Gross, P.; Harley, R.A.; Swinberne, L.M.; Davis, J.M.G.; Green, W.B. (1974) Ingested mineral fibers, do they penetrate tissue or cause cancer? *Arch. Environ. Health* 29:341-347.
17. Harrington, J.M.; Craun, G.F.; Meigs, J.W.; Landrigen, P.J.; Flannery, J.T. (1978) An investigation of the use of asbestos-cement pipe for public water supply and the incidence of gastrointestinal cancer in Connecticut, 1935-1973. *Am. J. Epidemiol.* 107:96-103.
18. Haseman, J.K. (1983) Patterns of tumor incidence in two-year cancer bioassay feeding studies in Fischer 344 rats. *Fundam. Appl. Toxicol.* 3:1-9.
19. Haseman, J.K. (1984) Statistical issues in the design, analysis and interpretation of animal carcinogenicity studies. *Environ. Health Perspect.* 58:385-392.
20. Haseman, J.K.; Huff, J.; Boorman, G.A. (1984) Use of historical control data in carcinogenicity studies in rodents. *Toxicol. Pathol.* 12:126-135.
21. Haseman, J.K.; Huff, J.; Rao, G.N.; Arnold, J.; Boorman, G.A.; McConnell, E.E. (1985) Neoplasms observed in untreated and corn oil gavage control groups of F344/N rats and (C57BL/6N × C3H/HeN)F₁ (B6C3F₁) mice. *J. Natl. Cancer Inst.* 75:975-984.

V. REFERENCES

22. Hilding, A.C.; Hilding, D.A.; Larsen, D.M.; Aufderheide, A.C. (1981) Biological effects of ingested amosite asbestos, taconite tailings, diatomaceous earth and Lake Superior water in rats. *Arch. Environ. Health* 36:298-303.
23. Illinois Institute of Technology Research Institute (IITRI) Special Report and Addendum on Project L6085. Contract No. N01-ES-5-3157. Chicago: Fine Particle Laboratories, IITRI.
24. International Agency for Research on Cancer (IARC) (1977) Asbestos. IARC Monographs on the Evaluation of the Carcinogenic Risk of Chemicals to Man, Vol. 14. Lyon, France: IARC, pp. 1-106.
25. Kanarek, M.S.; Conforti, P.M.; Jackson, L.A.; Cooper, R.C.; Murchio, J.C. (1980) Asbestos in drinking water and cancer incidence in the San Francisco Bay area. *Am. J. Epidemiol.* 112: 54-72.
26. Kaplan, E.L.; Meier, P. (1958) Nonparametric estimation from incomplete observations. *J. Am. Stat. Assoc.* 53:457-481.
27. Levine, R.J. (1981) Asbestos: An Information Source. DHEW Pub. No. NIH 78-1681. 105 p.
28. Linhart, M.S.; Cooper, J.; Martin, R.L.; Page, N.; Peters, J. (1974) Carcinogenesis Bioassay Data System. *Comput. Biomed. Res.* 7:230-248.
29. Mantel, N.; Haenszel, W. (1959) Statistical aspects of the analysis of data from retrospective studies of disease. *J. Natl. Cancer Inst.* 22:719-748.
30. Maronpot, R.R.; Boorman, G.A. (1982) Interpretation of rodent hepatocellular proliferative alterations and hepatocellular tumors in chemical safety assessment. *Toxicol. Pathol.* 10:71-80.
31. Millette, J.R. (1979) Exposure to Asbestos from Drinking Water in the United States. EPA Contract No. 600/1-79-150. U.S. Environmental Protection Agency.
32. National Toxicology Program (NTP) (1985a) Toxicology and Carcinogenesis Studies of Chrysotile Asbestos in F344/N Rats. NTP TR 295. U.S. Department of Health and Human Services, Public Health Service, National Institutes of Health, Research Triangle Park, NC. 390 p.
33. National Toxicology Program (NTP) (1985b) Lifetime Carcinogenesis Studies of Amosite Asbestos in Syrian Golden Hamsters. NTP TR 249. U.S. Department of Health and Human Services, Public Health Service, National Institutes of Health, Bethesda, MD. 81 p.
34. National Toxicology Program (NTP) (1988) Lifetime Carcinogenesis Studies of Crocidolite Asbestos in F344/N Rats. NTP TR 280. U.S. Department of Health and Human Services, Public Health Service, National Institutes of Health, Research Triangle Park, NC. 178 p.
35. National Toxicology Program (NTP) (1990a) Lifetime Carcinogenesis Studies of Chrysotile Asbestos in Syrian Golden Hamsters. NTP TR 246. U.S. Department of Health and Human Services, Public Health Service, National Institutes of Health, Research Triangle Park, NC (in preparation).
36. National Toxicology Program (NTP) (1990b) Lifetime Carcinogenesis Studies of Amosite Asbestos in F344/N Rats. NTP TR 279. U.S. Department of Health and Human Services, Public Health Service, National Institutes of Health, Research Triangle Park, NC (in preparation).
37. Patel-Mandlik, K.J. (1980) Distribution of Orally Administered Chrysotile Asbestos in Newborn Baboon Study. EPA 600/1-80-022. U.S. Environmental Protection Agency, Washington, DC.
38. Peto, R.; Schneiderman, M., Eds. (1981) Quantification of Occupational Cancer. Banbury Report No. 9. Cold Spring Harbor, New York.
39. Pozharisski, K.M. (1973) Tumors of the intestine. Jubusov, V.S., Ed.: *Pathology of Tumors in Laboratory Animals*. IARC Scientific Publication No. 5. Lyon, France: World Health Organization.

V. REFERENCES

40. Pozhariski, K.M. (1975) Morphology and morphogenesis of experimental epithelial tumors of the intestine. *J. Natl. Cancer Inst.* 54:1115-1135.
41. Reiss, B.; Weisburger, J.H.; Williams, G.M. (1979) Asbestos and Gastrointestinal Cancer: Cell Culture Studies. EPA-600/1-79-023. U.S. Environmental Protection Agency, Washington, DC.
42. Sebastien, P.; Masse, R.; Bignon, J. (1980) Recovery of ingested asbestos fibers from the gastrointestinal lymph in rats. *Environ. Res.* 22:201-216.
43. Selikoff, I.J. (1980) Asbestos-associated disease. Last, J., Ed.: *Maxcy-Rosehau's Public Health and Preventive Medicine*, 11th ed. Appleton-Century-Croft, pp. 568-589.
44. Selikoff, I.J.; Hammond, E.C., Eds. (1979) Health hazards of asbestos exposure. *Ann. N.Y. Acad. Sci.* B30:1-814.
45. Smith, W.E. (1974) Biological Effects of Tremolite Talc on Hamsters. Information Circular IC 8639. Bureau of Mines, pp. 43-48.
46. Smith, W.E.; Hubert, D.D.; Sobel, H.J.; Peters, E.T.; Doerfler, T.E. (1980) Health in experimental animals drinking water with and without amosite and other mineral particles. *J. Environ. Pathol. Toxicol.* 3:277-300.
47. Stanton, M.F.; Layard, M.; Tegarlis, A.; Miller, E.; May, M.; Morgan, E.; Smith, A. (1981) Relation of particle dimension to the carcinogenicity in amphibole asbestoses and other fibrous minerals. *J. Natl. Cancer Inst.* 67:965-975.
48. Storeygard, A.R.; Brown, A.L. (1977) Penetration of the small intestinal mucosa by asbestos fibers. *Mayo Clin. Proc.* 52:809-812.
51. U.S. Environmental Protection Agency (USEPA) (1980) Ambient Water Quality Criteria for Asbestos. EPA 440/5-80-022. Washington, DC: USEPA, Office of Water Regulations and Standards.
52. Wagner, J.C.; Berry, G.; Skidmore, J.W.; Timbrell, V. (1974) Effects of the inhalation of asbestos in rats. *Br. J. Cancer* 29:252-269.
53. Wagner, J.C.; Chamberlain, M.; Brown, R.C.; Berry, G.; Pooley, F.D.; Davies, R.; Griffiths, D.M. (1982) Biological effects of tremolite. *Br. J. Cancer* 45:352-360.

APPENDIX A

SUMMARY OF LESIONS IN MALE RATS IN THE LIFETIME FEED STUDY OF TREMOLITE

	PAGE	
TABLE A1	SUMMARY OF THE INCIDENCE OF NEOPLASMS IN MALE RATS IN THE LIFETIME FEED STUDY OF TREMOLITE	45
TABLE A2	INDIVIDUAL ANIMAL TUMOR PATHOLOGY OF MALE RATS IN THE LIFETIME FEED STUDY OF TREMOLITE	50
TABLE A3	ANALYSIS OF PRIMARY TUMORS IN MALE RATS IN THE LIFETIME FEED STUDY OF TREMOLITE	90
TABLE A4a	INCIDENCE OF EPITHELIAL TUMORS OF THE LARGE INTESTINE IN MALE F344/N RATS RECEIVING NO TREATMENT IN LIFETIME STUDIES	98
TABLE A4b	INCIDENCE OF EPITHELIAL TUMORS OF THE SMALL INTESTINE IN MALE F344/N RATS RECEIVING NO TREATMENT IN LIFETIME STUDIES	98
TABLE A5	SUMMARY OF THE INCIDENCE OF NONNEOPLASTIC LESIONS IN MALE RATS IN THE LIFETIME FEED STUDY OF TREMOLITE	99

TABLE A1. SUMMARY OF THE INCIDENCE OF NEOPLASMS IN MALE RATS IN THE LIFETIME FEED STUDY OF TREMOLITE

	Untreated Control	1% Tremolite
Animals initially in study	118	250
Animals necropsied	118	250
Animals examined histopathologically	118	250
INTEGUMENTARY SYSTEM		
*Multiple organs	(118)	(250)
Fibrous histiocytoma	1 (1%)	
Fibrous histiocytoma, malignant		2 (1%)
*Skin	(118)	(250)
Squamous cell papilloma	3 (3%)	9 (4%)
Squamous cell carcinoma	2 (2%)	4 (2%)
Basal cell tumor	2 (2%)	2 (1%)
Basal cell carcinoma	4 (3%)	8 (3%)
Trichoepithelioma	1 (1%)	1 (0.4%)
Keratoacanthoma	6 (5%)	13 (5%)
Fibrosarcoma		1 (0.4%)
*Subcutaneous tissue	(118)	(250)
Squamous cell carcinoma, invasive	1 (1%)	1 (0.4%)
Sarcoma, NOS	1 (1%)	3 (1%)
Fibroma	14 (12%)	36 (14%)
Fibrosarcoma	3 (3%)	11 (4%)
Myxosarcoma	1 (1%)	1 (0.4%)
Liposarcoma		1 (0.4%)
Neurofibroma	2 (2%)	6 (2%)
Neurofibrosarcoma		1 (0.4%)
RESPIRATORY SYSTEM		
#Trachea	(117)	(250)
Follicular cell carcinoma, invasive	1 (1%)	
#Lung	(118)	(250)
Squamous cell carcinoma	1 (1%)	
Squamous cell carcinoma, metastatic	2 (2%)	1 (0.4%)
Alveolar/bronchiolar adenoma	1 (1%)	
Alveolar/bronchiolar carcinoma	2 (2%)	2 (1%)
Follicular cell carcinoma, metastatic	1 (1%)	
Cortical carcinoma, metastatic		1 (0.4%)
C-cell carcinoma, metastatic	1 (1%)	5 (2%)
Pheochromocytoma, metastatic	2 (2%)	3 (1%)
Sarcoma, NOS, metastatic		1 (0.4%)
Fibrosarcoma, metastatic		1 (0.4%)
Liposarcoma, metastatic		2 (1%)
Mesothelioma, metastatic	1 (1%)	
Osteosarcoma, metastatic	1 (1%)	
HEMATOPOIETIC SYSTEM		
*Multiple organs	(118)	(250)
Malignant lymphoma, lymphocytic type	2 (2%)	
Malignant lymphoma, histiocytic type	1 (1%)	1 (0.4%)
Myelomonocytic leukemia		4 (2%)
Monocytic leukemia	43 (36%)	95 (38%)
Megakaryocytic leukemia		1 (0.4%)
#Spleen	(118)	(250)
Pheochromocytoma, metastatic		1 (0.4%)
Sarcoma, NOS, metastatic		1 (0.4%)
Fibroma		1 (0.4%)
Fibrosarcoma		1 (0.4%)
Malignant lymphoma, histiocytic type	2 (2%)	
#Mandibular lymph node	(118)	(250)
Sarcoma, NOS, invasive		1 (0.4%)

TABLE A1. SUMMARY OF THE INCIDENCE OF NEOPLASMS IN MALE RATS IN THE LIFETIME FEED STUDY OF TREMOLITE (Continued)

	Untreated Control	1% Tremolite
HEMATOPOIETIC SYSTEM (Continued)		
#Cervical lymph node	(118)	(250)
C-cell carcinoma, metastatic		1 (0.4%)
#Mediastinal lymph node	(118)	(250)
C-cell carcinoma, metastatic		1 (0.4%)
Fibrosarcoma, metastatic		1 (0.4%)
Mesothelioma, metastatic	2 (2%)	
#Mesenteric lymph node	(118)	(250)
Sarcoma, NOS, invasive		1 (0.4%)
#Renal lymph node	(118)	(250)
Carcinoma, NOS, metastatic	1 (1%)	
Pheochromocytoma, metastatic		1 (0.4%)
#Liver	(118)	(250)
Monocytic leukemia		2 (1%)
#Thymus	(89)	(196)
Carcinoma, NOS		1 (1%)
Squamous cell carcinoma		1 (1%)
Squamous cell carcinoma, metastatic	1 (1%)	
CIRCULATORY SYSTEM		
*Sacral region	(118)	(250)
Hemangiopericytoma, NOS		1 (0.4%)
*Subcutaneous tissue	(118)	(250)
Hemangiosarcoma		3 (1%)
#Spleen	(118)	(250)
Hemangioma	1 (1%)	
Hemangiosarcoma	1 (1%)	4 (2%)
#Mesenteric lymph node	(118)	(250)
Hemangiosarcoma	1 (1%)	
#Heart	(118)	(250)
Liposarcoma, metastatic		1 (0.4%)
Mesothelioma, invasive	1 (1%)	
*Mesentery	(118)	(250)
Hemangiosarcoma		1 (0.4%)
DIGESTIVE SYSTEM		
*Oral mucous membrane	(118)	(250)
Squamous cell papilloma	1 (1%)	
Squamous cell carcinoma	2 (2%)	1 (0.4%)
#Salivary gland	(116)	(245)
Sarcoma, NOS		3 (1%)
Fibrosarcoma	1 (1%)	2 (1%)
#Liver	(118)	(250)
Bile duct carcinoma		1 (0.4%)
Neoplastic nodule	10 (8%)	8 (3%)
Hepatocellular carcinoma	6 (5%)	6 (2%)
#Pancreas	(118)	(250)
Transitional cell carcinoma, invasive		1 (0.4%)
Acinar cell adenoma	10 (8%)	22 (9%)
Acinar cell carcinoma		1 (0.4%)
Mixed tumor, benign	3 (3%)	3 (1%)
#Pancreatic duct	(118)	(250)
Carcinoma, NOS	1 (1%)	1 (0.4%)
*Pharynx	(118)	(250)
Squamous cell carcinoma		1 (0.4%)
Squamous cell carcinoma, invasive	1 (1%)	
#Stomach	(118)	(250)
Squamous cell papilloma	2 (2%)	1 (0.4%)
Squamous cell carcinoma	1 (1%)	1 (0.4%)
Sarcoma, NOS		1 (0.4%)

TABLE A1. SUMMARY OF THE INCIDENCE OF NEOPLASMS IN MALE RATS IN THE LIFETIME FEED STUDY OF TREMOLITE (Continued)

	Untreated Control	1% Tremolite
DIGESTIVE SYSTEM (Continued)		
#Duodenum	(118)	(250)
Mucinous cystadenocarcinoma		1 (0.4%)
Fibroma		1 (0.4%)
#Jejunum	(118)	(250)
Mucinous cystadenocarcinoma		1 (0.4%)
Sarcoma, NOS, metastatic		1 (0.4%)
Leiomyoma		1 (0.4%)
Leiomyosarcoma		1 (0.4%)
#Ileum	(118)	(250)
Adenomatous polyp, NOS		1 (0.4%)
#Colon	(118)	(250)
Carcinoma, NOS, invasive	1 (1%)	
#Cecum	(118)	(250)
Adenomatous polyp, NOS		1 (0.4%)
#Ascending colon	(118)	(250)
Adenomatous polyp, NOS		1 (0.4%)
Mucinous cystadenocarcinoma		1 (0.4%)
#Transverse colon	(118)	(250)
Adenomatous polyp, NOS	1 (1%)	
Mucinous cystadenocarcinoma		1 (0.4%)
URINARY SYSTEM		
#Kidney	(118)	(250)
Transitional cell carcinoma		1 (0.4%)
Tubular cell adenoma		1 (0.4%)
Tubular cell adenocarcinoma	1 (1%)	5 (2%)
Sarcoma, NOS		1 (0.4%)
Lipoma	1 (1%)	
#Urinary bladder	(118)	(250)
Transitional cell carcinoma	1 (1%)	
ENDOCRINE SYSTEM		
#Pituitary	(118)	(247)
Carcinoma, NOS	2 (2%)	4 (2%)
Adenoma, NOS	20 (17%)	37 (15%)
#Adrenal	(118)	(250)
Cortical adenoma	1 (1%)	2 (1%)
Cortical carcinoma		1 (0.4%)
Pheochromocytoma	38 (32%)	62 (25%)
Pheochromocytoma, malignant	3 (3%)	7 (3%)
Ganglioneuroma		1 (0.4%)
#Thyroid	(117)	(247)
Follicular cell adenoma	5 (4%)	12 (5%)
Follicular cell carcinoma	6 (5%)	13 (5%)
C-cell adenoma	11 (9%)	22 (9%)
C-cell carcinoma	16 (14%)	48 (19%)
#Parathyroid	(109)	(236)
Adenoma, NOS	2 (2%)	4 (2%)
#Pancreatic islets	(118)	(250)
Islet cell adenoma	5 (4%)	12 (5%)
Islet cell carcinoma	7 (6%)	11 (4%)
REPRODUCTIVE SYSTEM		
*Mammary gland	(118)	(250)
Adenoma, NOS	1 (1%)	1 (0.4%)
Adenocarcinoma, NOS	2 (2%)	3 (1%)
Papillary adenocarcinoma		1 (0.4%)
Papillary cystadenocarcinoma, NOS	1 (1%)	
Fibroadenoma	17 (14%)	32 (13%)

TABLE A1. SUMMARY OF THE INCIDENCE OF NEOPLASMS IN MALE RATS IN THE LIFETIME FEED STUDY OF TREMOLITE (Continued)

	Untreated Control	1% Tremolite
REPRODUCTIVE SYSTEM (Continued)		
*Prepuce	(118)	(250)
Keratoacanthoma		1 (0.4%)
*Preputial gland	(118)	(250)
Carcinoma, NOS	1 (1%)	
Squamous cell carcinoma	6 (5%)	14 (6%)
Keratoacanthoma	1 (1%)	
#Prostate	(118)	(249)
Leiomyosarcoma	1 (1%)	
#Testis	(118)	(250)
Carcinoma, NOS, metastatic	1 (1%)	
Interstitial cell tumor	114 (97%)	237 (95%)
*Epididymis	(118)	(250)
Lipoma		1 (0.4%)
Mesothelioma, invasive		1 (0.4%)
*Scrotum	(118)	(250)
Mesothelioma, invasive		1 (0.4%)
NERVOUS SYSTEM		
#Cerebrum	(118)	(250)
Carcinoma, NOS, invasive	1 (1%)	1 (0.4%)
Glioma, NOS	1 (1%)	
Astrocytoma	6 (5%)	6 (2%)
#Cerebellum	(118)	(250)
Carcinoma, NOS, invasive	1 (1%)	1 (0.4%)
Astrocytoma	1 (1%)	
*Spinal cord	(118)	(250)
Astrocytoma		1 (0.4%)
SPECIAL SENSE ORGANS		
*Zymbal gland	(118)	(250)
Carcinoma, NOS	1 (1%)	
Squamous cell carcinoma	3 (3%)	9 (4%)
Keratoacanthoma		1 (0.4%)
MUSCULOSKELETAL SYSTEM		
*Skull	(118)	(250)
Fibrosarcoma, invasive	1 (1%)	
*Maxilla	(118)	(250)
Fibrosarcoma, invasive		1 (0.4%)
*Mandible	(118)	(250)
Squamous cell carcinoma, invasive		1 (0.4%)
*Vertebra	(118)	(250)
Fibroma	1 (1%)	
*Lumbar vertebra	(118)	(250)
Liposarcoma, invasive		1 (0.4%)
Osteosarcoma		1 (0.4%)
*Rib	(118)	(250)
Osteosarcoma	1 (1%)	
*Muscle of neck	(118)	(250)
Fibrosarcoma, invasive	1 (1%)	
BODY CAVITIES		
*Mediastinum	(118)	(250)
Squamous cell carcinoma, metastatic	1 (1%)	
Fibrosarcoma, invasive		1 (0.4%)
Mesothelioma, malignant	1 (1%)	
Mesothelioma, metastatic	1 (1%)	

TABLE A1. SUMMARY OF THE INCIDENCE OF NEOPLASMS IN MALE RATS IN THE LIFETIME FEED STUDY OF TREMOLITE (Continued)

	Untreated Control	1% Tremolite
BODY CAVITIES (Continued)		
*Abdominal cavity	(118)	(250)
Pheochromocytoma, invasive	1 (1%)	
*Peritoneum	(118)	(250)
Fibrosarcoma		1 (0.4%)
Liposarcoma	1 (1%)	1 (0.4%)
*Pericardium	(118)	(250)
Osteosarcoma, metastatic	1 (1%)	
*Mesentery	(118)	(250)
Pheochromocytoma, metastatic		1 (0.4%)
Sarcoma, NOS		1 (0.4%)
Fibrosarcoma	1 (1%)	1 (0.4%)
Lipoma	1 (1%)	
*Tunica vaginalis	(118)	(250)
Mesothelioma, malignant	9 (8%)	8 (3%)
ALL OTHER SYSTEMS		
*Multiple organs	(118)	(250)
Carcinoma, NOS, invasive		1 (0.4%)
Squamous cell carcinoma, invasive	1 (1%)	1 (0.4%)
Transitional cell carcinoma, metastatic		1 (0.4%)
Sarcoma, NOS, invasive		1 (0.4%)
Fibrosarcoma, invasive	1 (1%)	2 (1%)
Mesothelioma, invasive	9 (8%)	5 (2%)
Mesothelioma, metastatic		1 (0.4%)
Cranial cavity		
Osteoma		1
ANIMAL DISPOSITION SUMMARY		
Animals initially in study	18	250
Natural death	23	38
Moribund sacrifice	90	180
Terminal sacrifice	5	28
Accidentally killed, nda		4
TUMOR SUMMARY		
Total animals with primary tumors**	117	241
Total primary tumors	423	844
Total animals with benign tumors	115	238
Total benign tumors	266	526
Total animals with malignant tumors	96	199
Total malignant tumors	147	309
Total animals with secondary tumors##	21	37
Total secondary tumors	37	47
Total animals with tumors-- uncertain benign or malignant	10	9
Total uncertain tumors	10	9

* Number of animals receiving complete necropsy examination; all gross lesions including masses examined microscopically

** Primary tumors: all tumors except secondary tumors

Number of animals examined microscopically at this site

Secondary tumors: metastatic tumors or tumors invasive into an adjacent organ

TABLE A2. INDIVIDUAL ANIMAL TUMOR PATHOLOGY OF MALE RATS IN THE LIFETIME FEED STUDY OF TREMOLITE: CONTROL

ANIMAL NUMBER	7 9 6	7 9 7	7 9 8	7 9 0	8 0 1	8 0 2	8 0 3	8 0 4	8 0 5	8 0 6	8 0 7	8 0 8	8 0 9	8 1 0	8 1 1	8 1 2	8 1 3	8 1 4	8 1 5	8 1 6	8 1 7	8 1 8	8 1 9	8 2 0
WEEKS ON STUDY	1 0 4	1 3 0	1 3 7	1 4 3	1 4 1	1 4 6	1 4 9	1 4 6	1 4 7	1 4 5	1 4 4	1 4 0	1 4 2	1 4 0	0 8 4	1 4 6	1 4 7	1 4 9	1 4 7	1 4 5	1 4 8	1 4 0	1 4 2	1 4 1
INTEGUMENTARY SYSTEM																								
Skin																								
Squamous cell papilloma																								
Squamous cell carcinoma		X																						
Basal cell tumor																								
Basal cell carcinoma										X											X			
Trichoepithelioma																								
Keratoacanthoma																								
Subcutaneous tissue																								
Squamous cell carcinoma, invasive																								
Sarcoma, NOS																								
Fibroma																								
Fibrosarcoma																					X			
Myxosarcoma																						X		
Neurofibroma																								
RESPIRATORY SYSTEM																								
Lungs and bronchi																								
Squamous cell carcinoma																								
Squamous cell carcinoma, metastatic																								
Alveolar/bronchiolar adenoma																								
Alveolar/bronchiolar carcinoma																								
Follicular cell carcinoma, metastatic																								
C-cell carcinoma, metastatic																								
Pheochromocytoma, metastatic																								
Mesothelioma, metastatic																								
Osteosarcoma, metastatic																								
Trachea																								
Follicular cell carcinoma, invasive																								
HEMATOPOIETIC SYSTEM																								
Bone marrow																								
+																								
Spleen																								
Hemangioma																								
Hemangiosarcoma																								
Malignant lymphoma, histiocytic type																								
Lymph nodes																								
Carcinoma, NOS, metastatic																								
Mesothelioma, metastatic																								
Hemangiosarcoma																								
Thymus																								
Squamous cell carcinoma, metastatic																								
CIRCULATORY SYSTEM																								
Heart																								
Mesothelioma, invasive																								
DIGESTIVE SYSTEM																								
Oral cavity																								
Squamous cell papilloma	N	N	N	N	N	N	N	N	N	N	N	N	N	N	N	N	N	N	N	N	N	N	N	N
Squamous cell carcinoma																								
Squamous cell carcinoma, invasive																								
Salivary gland																								
Fibrosarcoma																								
Liver																								
Neoplastic nodule																								
Hepatocellular carcinoma																								
Bile duct																								
Gallbladder & common bile duct	N	N	N	N	N	N	N	N	N	N	N	N	N	N	N	N	N	N	N	N	N	N	N	N
Pancreas																								
Carcinoma, NOS																								
Acinar cell adenoma																								
Mixed tumor, benign																								
Esophagus																								
+																								
Stomach																								
Squamous cell papilloma																								
Squamous cell carcinoma																								
Small intestine																								
+																								
Large intestine																								
Carcinoma, NOS, invasive																								
Adenomatous polyp, NOS																								
URINARY SYSTEM																								
Kidney																								
Tubular cell adenocarcinoma																								
Lipoma																								
Urinary bladder																								
Transitional cell carcinoma																								X

+: Tissue examined microscopically
 -: Required tissue not examined microscopically
 X: Tumor incidence
 N: Necropsy, no autolysis, no microscopic examination
 S: Animal missexed

: No tissue information submitted
 C: Necropsy, no histology due to protocol
 A: Autolysis
 M: Animal missing
 B: No necropsy performed

TABLE A2. INDIVIDUAL ANIMAL TUMOR PATHOLOGY OF MALE RATS: CONTROL
(Continued)

ANIMAL NUMBER	8 4 6	8 4 7	8 4 8	8 4 9	8 5 0	8 5 1	8 5 2	8 5 3	8 5 4	8 5 5	8 5 6	8 5 7	8 5 8	8 5 9	8 6 0	8 6 1	8 6 2	8 6 3	8 6 4	8 6 5	8 6 6	8 6 7	8 6 8	8 6 9	8 7 0		
WEEKS ON STUDY	1 1 9	1 3 0	1 3 4	1 0 8	0 7 6	1 2 9	1 1 1	1 4 4	1 2 0	1 0 5	1 1 1	1 1 6	1 1 4	1 2 2	1 3 3	1 1 0	1 2 2	1 0 0	1 1 1	1 3 5	1 4 5	1 0 1	0 8 2	0 8 5	0 8 5	1 2 0	
INTEGUMENTARY SYSTEM																											
Skin																											
Squamous cell papilloma	+	+	+	+	+	+	+	+	+	+	+	+	+	+	+	+	+	+	+	+	+	+	+	+	+	+	
Squamous cell carcinoma																											
Basal cell tumor																											
Basal cell carcinoma													X														
Trichoepithelioma																											
Keratoacanthoma																											
Subcutaneous tissue																											
Squamous cell carcinoma, invasive	+	+	+	+	+	+	+	+	+	+	+	+	+	+	+	+	+	+	+	+	+	+	+	+	+	+	
Sarcoma, NOS																											
Fibroma																											
Fibrosarcoma																											
Myxosarcoma																										X	
Neurofibroma													X														
RESPIRATORY SYSTEM																											
Lungs and bronchi																											
Squamous cell carcinoma	+	+	+	+	+	+	+	+	+	+	+	+	+	+	+	+	+	+	+	+	+	+	+	+	+	+	
Squamous cell carcinoma, metastatic																											
Alveolar/bronchiolar adenoma		X																									
Alveolar/bronchiolar carcinoma																											
Follicular cell carcinoma, metastatic																										X	
C-cell carcinoma, metastatic																											
Pheochromocytoma, metastatic																											
Mesothelioma, metastatic																											
Osteosarcoma, metastatic																											
Trachea																											
Follicular cell carcinoma, invasive	+	+	+	+	+	+	+	+	+	+	+	+	+	+	+	+	+	+	+	+	+	+	+	+	+	+	
																										X	
HEMATOPOIETIC SYSTEM																											
Bone marrow																											
	+	+	+	+	+	+	+	+	+	+	+	+	+	+	+	+	+	+	+	+	+	+	+	+	+	+	
Spleen																											
Hemangioma	+	+	+	+	+	+	+	+	+	+	+	+	+	+	+	+	+	+	+	+	+	+	+	+	+	+	
Hemangiosarcoma																											
Malignant lymphoma, histiocytic type																											
Lymph nodes																											
Carcinoma, NOS, metastatic	+	+	+	+	+	+	+	+	+	+	+	+	+	+	+	+	+	+	+	+	+	+	+	+	+	+	
Mesothelioma, metastatic																											
Hemangiosarcoma																											
Thymus																											
Squamous cell carcinoma, metastatic	+	-	+	-	+	+	-	+	+	-	+	+	-	+	+	-	+	+	-	+	+	-	+	+	-	+	
CIRCULATORY SYSTEM																											
Heart																											
Mesothelioma, invasive	+	+	+	+	+	+	+	+	+	+	+	+	+	+	+	+	+	+	+	+	+	+	+	+	+	+	
DIGESTIVE SYSTEM																											
Oral cavity																											
Squamous cell papilloma	N	N	N	N	N	N	N	N	N	N	N	N	N	N	N	N	N	N	N	N	N	N	N	N	N	N	
Squamous cell carcinoma			X																								
Squamous cell carcinoma, invasive																										X	
Salivary gland																											
Fibrosarcoma	+	+	+	+	+	+	+	+	+	+	+	+	+	+	+	+	+	+	+	+	+	+	+	+	+	+	
																										X	
Liver																											
Neoplastic nodule	+	+	+	+	+	+	+	+	+	+	+	+	+	+	+	+	+	+	+	+	+	+	+	+	+	+	
Hepatocellular carcinoma								X										X		X		X				+	
Bile duct																											
Gallbladder & common bile duct	N	N	N	N	N	N	N	N	N	N	N	N	N	N	N	N	N	N	N	N	N	N	N	N	N	N	
Pancreas																											
Carcinoma, NOS	+	+	+	+	+	+	+	+	+	+	+	+	+	+	+	+	+	+	+	+	+	+	+	+	+	+	
Acinar cell adenoma																											
Mixed tumor, benign																											
Esophagus																											
Stomach	+	+	+	+	+	+	+	+	+	+	+	+	+	+	+	+	+	+	+	+	+	+	+	+	+	+	
Squamous cell papilloma																											
Squamous cell carcinoma																											
Small intestine																											
Large intestine	+	+	+	+	+	+	+	+	+	+	+	+	+	+	+	+	+	+	+	+	+	+	+	+	+	+	
Carcinoma, NOS, invasive																											
Adenomatous polyp, NOS																											
													X														
URINARY SYSTEM																											
Kidney																											
Tubular cell adenocarcinoma	+	+	+	+	+	+	+	+	+	+	+	+	+	+	+	+	+	+	+	+	+	+	+	+	+	+	
Lipoma																											
Urinary bladder																											
Transitional cell carcinoma	+	+	+	+	+	+	+	+	+	+	+	+	+	+	+	+	+	+	+	+	+	+	+	+	+	+	

TABLE A2. INDIVIDUAL ANIMAL TUMOR PATHOLOGY OF MALE RATS: CONTROL
(Continued)

ANIMAL NUMBER	871	872	873	874	875	876	877	878	879	880	881	882	883	884	885	886	887	888	889	890	891	892	893	894	895		
WEEKS ON STUDY	093	110	293	311	413	510	611	711	811	920	101	114	123	132	143	156	167	178	184	190	201	212	223	234	245		
INTEGUMENTARY SYSTEM																											
Skin																											
Squamous cell papilloma	+	+	+	+	+	+	+	+	+	+	+	+	+	+	+	+	+	+	+	+	+	+	+	+	+	+	
Squamous cell carcinoma																											
Basal cell tumor																											
Basal cell carcinoma																											
Trichoepithelioma																											
Keratoacanthoma																											
Subcutaneous tissue	+	+	+	+	+	+	+	+	+	+	+	+	+	+	+	+	+	+	+	+	+	+	+	+	+	+	
Squamous cell carcinoma, invasive																											
Sarcoma, NOS																											
Fibroma																											
Fibrosarcoma																											
Myxosarcoma																											
Neurofibroma																											
RESPIRATORY SYSTEM																											
Lungs and bronchi																											
Squamous cell carcinoma	+	+	+	+	+	+	+	+	+	+	+	+	+	+	+	+	+	+	+	+	+	+	+	+	+	+	
Squamous cell carcinoma, metastatic																											
Alveolar/bronchiolar adenoma																											
Alveolar/bronchiolar carcinoma																											
Follicular cell carcinoma, metastatic																											
C-cell carcinoma, metastatic																											
Phaeochromocytoma, metastatic																											
Mesothelioma, metastatic																											
Osteosarcoma, metastatic																											
Trachea	+	+	+	+	+	+	+	+	+	+	+	+	+	+	+	+	+	+	+	+	+	+	+	+	+	+	
Follicular cell carcinoma, invasive																											
HEMATOPOIETIC SYSTEM																											
Bone marrow																											
	+	+	+	+	+	+	+	+	+	+	+	+	+	+	+	+	+	+	+	+	+	+	+	+	+	+	
Spleen																											
Hemangioma	+	+	+	+	+	+	+	+	+	+	+	+	+	+	+	+	+	+	+	+	+	+	+	+	+	+	
Hemangiosarcoma																											
Malignant lymphoma, histiocytic type																											
Lymph nodes	+	+	+	+	+	+	+	+	+	+	+	+	+	+	+	+	+	+	+	+	+	+	+	+	+	+	
Carcinoma, NOS, metastatic	X																										
Mesothelioma, metastatic																											
Hemangiosarcoma																											
Thymus	+	+	+	+	+	+	+	+	+	+	+	+	+	+	+	+	+	+	+	+	+	+	+	+	+	+	
Squamous cell carcinoma, metastatic																											
CIRCULATORY SYSTEM																											
Heart																											
Mesothelioma, invasive																											
DIGESTIVE SYSTEM																											
Oral cavity																											
Squamous cell papilloma	N	N	N	N	N	N	N	N	N	N	N	N	N	N	N	N	N	N	N	N	N	N	N	N	N	N	
Squamous cell carcinoma																											
Squamous cell carcinoma, invasive																											
Salivary gland	+	+	+	+	+	+	+	+	+	+	+	+	+	+	+	+	+	+	+	+	+	+	+	+	+	+	
Fibrosarcoma																											
Liver	+	+	+	+	+	+	+	+	+	+	+	+	+	+	+	+	+	+	+	+	+	+	+	+	+	+	
Neoplastic nodule																											
Hepatocellular carcinoma																											
Bile duct	+	+	+	+	+	+	+	+	+	+	+	+	+	+	+	+	+	+	+	+	+	+	+	+	+	+	
Gallbladder & common bile duct	N	N	N	N	N	N	N	N	N	N	N	N	N	N	N	N	N	N	N	N	N	N	N	N	N	N	
Pancreas	+	+	+	+	+	+	+	+	+	+	+	+	+	+	+	+	+	+	+	+	+	+	+	+	+	+	
Carcinoma, NOS	X																										
Acinar cell adenoma																											
Mixed tumor, benign																											
Esophagus	+	+	+	+	+	+	+	+	+	+	+	+	+	+	+	+	+	+	+	+	+	+	+	+	+	+	
Stomach	+	+	+	+	+	+	+	+	+	+	+	+	+	+	+	+	+	+	+	+	+	+	+	+	+	+	
Squamous cell papilloma																											
Squamous cell carcinoma																											
Small intestine	+	+	+	+	+	+	+	+	+	+	+	+	+	+	+	+	+	+	+	+	+	+	+	+	+	+	
Large intestine	+	+	+	+	+	+	+	+	+	+	+	+	+	+	+	+	+	+	+	+	+	+	+	+	+	+	
Carcinoma, NOS, invasive	X																										
Adenomatous polyp, NOS																											
URINARY SYSTEM																											
Kidney																											
Tubular cell adenocarcinoma	+	+	+	+	+	+	+	+	+	+	+	+	+	+	+	+	+	+	+	+	+	+	+	+	+	+	
Lipoma																											
Urinary bladder	+	+	+	+	+	+	+	+	+	+	+	+	+	+	+	+	+	+	+	+	+	+	+	+	+	+	
Transitional cell carcinoma																											

TABLE A2. INDIVIDUAL ANIMAL TUMOR PATHOLOGY OF MALE RATS: CONTROL
(Continued)

ANIMAL NUMBER	871	872	873	874	875	876	877	878	879	880	881	882	883	884	885	886	887	888	889	890	891	892	893	894	895		
WEEKS ON STUDY	093	110	012	114	111	113	110	111	111	111	111	111	111	111	111	111	111	111	111	111	017	112	111	111	111		
ENDOCRINE SYSTEM																											
Pituitary	+	+	+	+	+	+	+	+	+	+	+	+	+	+	+	+	+	+	+	+	+	+	+	+	+		
Carcinoma, NOS																											
Adenoma, NOS												X									X						
Adrenal	+	+	+	+	+	+	+	+	+	+	+	+	+	+	+	+	+	+	+	+	+	+	+	+	+		
Cortical adenoma																											
Pheochromocytoma				X				X		X		X		X		X					X		X		X		
Pheochromocytoma, malignant																											
Thyroid	+	+	+	+	+	+	+	+	+	+	+	+	+	+	+	+	+	+	+	+	+	+	+	+	+		
Follicular cell adenoma																											
Follicular cell carcinoma																											
C-cell adenoma																									X		
C-cell carcinoma																											
Parathyroid	-	+	-	+	+	+	+	+	+	+	+	+	+	+	+	+	+	+	+	+	+	+	+	+	+		
Adenoma, NOS												X		X							X				+		
Pancreatic islets	+	+	+	+	+	+	+	+	+	+	+	+	+	+	+	+	+	+	+	+	+	+	+	+	+		
Islet cell adenoma																											
Islet cell carcinoma																						X		X			
REPRODUCTIVE SYSTEM																											
Mammary gland	N	+	+	+	+	+	+	+	+	+	+	+	+	+	+	+	+	+	+	+	+	+	+	+	+		
Adenoma, NOS																											
Adenocarcinoma, NOS																											
Papillary cystadenocarcinoma, NOS																											
Fibroadenoma																											
Testis	+	+	+	+	+	+	+	+	+	+	+	+	+	+	+	+	+	+	+	+	+	+	+	+	+		
Carcinoma, NOS, metastatic																											
Interstitial cell tumor	X	X	X	X	X	X	X	X	X	X	X	X	X	X	X	X	X	X	X	X	X	X	X	X	X		
Prostate	+	+	+	+	+	+	+	+	+	+	+	+	+	+	+	+	+	+	+	+	+	+	+	+	+		
Leiomyosarcoma																											
Preputial/clitoral gland	N	N	N	N	N	N	N	N	N	N	N	N	N	N	N	N	N	N	N	N	N	N	N	N	N		
Carcinoma, NOS																											
Squamous cell carcinoma																											
Keratoacanthoma																											
NERVOUS SYSTEM																											
Brain	+	+	+	+	+	+	+	+	+	+	+	+	+	+	+	+	+	+	+	+	+	+	+	+	+		
Carcinoma, NOS, invasive																											
Glioma, NOS																											
Astrocytoma												X											X		X		
SPECIAL SENSE ORGANS																											
Zymbal gland	+	+	+	+	+	+	+	+	+	+	+	+	+	+	+	+	+	+	+	+	+	+	+	+	+		
Carcinoma, NOS																											
Squamous cell carcinoma																											
MUSCULOSKELETAL SYSTEM																											
Bone	N	N	N	N	N	N	N	N	N	N	N	N	N	N	N	N	N	N	N	N	N	N	N	N	N		
Fibroma																											
Fibrosarcoma, invasive																											
Osteosarcoma																											
Muscle	N	N	N	N	N	N	N	N	N	N	N	N	N	N	N	N	N	N	N	N	N	N	N	N	N		
Fibrosarcoma, invasive																											
BODY CAVITIES																											
Mediastinum	N	N	N	N	N	N	N	N	N	N	N	N	N	N	N	N	N	N	N	N	N	N	N	N	N		
Squamous cell carcinoma, metastatic																											
Mesothelioma, malignant																											
Mesothelioma, metastatic																											
Pericardium	N	N	N	N	N	N	N	N	N	N	N	N	N	N	N	N	N	N	N	N	N	N	N	N	N		
Osteosarcoma, metastatic																											
Peritoneum	N	N	N	N	N	N	N	N	N	N	N	N	N	N	N	N	N	N	N	N	N	N	N	N	N		
Pheochromocytoma, invasive																											
Liposarcoma																											
Tunica vaginalis	+	+	+	+	+	+	+	+	+	+	+	+	+	+	+	+	+	+	+	+	+	+	+	+	+		
Mesothelioma, malignant	X	X	X	X	X	X	X	X	X	X	X	X	X	X	X	X	X	X	X	X	X	X	X	X	X		
Mesentery	N	N	N	N	N	N	N	N	N	N	N	N	N	N	N	N	N	N	N	N	N	N	N	N	N		
Fibrosarcoma																											
Lipoma																											
ALL OTHER SYSTEMS																											
Multiple organs, NOS	N	N	N	N	N	N	N	N	N	N	N	N	N	N	N	N	N	N	N	N	N	N	N	N	N		
Squamous cell carcinoma, invasive																											
Fibrosarcoma, invasive																											
Fibrous histiocytoma																											
Mesothelioma, invasive	X	X				X	X																		X		
Malignant lymphoma, lymphocytic type					X																						
Malignant lymphoma, histiocytic type																											
Monocytic leukemia	X					X	X						X	X	X				X	X			X	X			

**TABLE A2. INDIVIDUAL ANIMAL TUMOR PATHOLOGY OF MALE RATS: 1% TREMOLITE
(Continued)**

ANIMAL NUMBER	0 5 7	0 5 8	0 5 9	0 6 0	0 6 1	0 6 2	0 6 3	0 6 4	0 6 5	0 6 6	0 6 7	0 6 8	0 6 9	0 7 0	0 7 1	0 7 2	0 7 3	0 7 4	0 7 5	0 7 6	0 7 7	0 7 8	0 7 9	0 8 0	0 8 1		
WEEKS ON STUDY	1 4 6	1 4 0	1 3 2	1 3 0	1 3 6	1 4 6	1 4 6	1 2 5	1 2 8	1 2 6	1 4 6	1 4 6	1 3 2	0 8 7	1 4 6	1 3 3	1 0 6	1 3 0	1 3 7	0 9 1	1 1 3	1 3 2	0 0 6	1 4 6	1 2 8		
INTEGUMENTARY SYSTEM																											
Skin	+																										
Squamous cell papilloma																											
Squamous cell carcinoma																											
Basal cell tumor																											
Basal cell carcinoma																											
Trichoepithelioma																											
Keratoacanthoma																											
Fibrosarcoma																											
Subcutaneous tissue																											
Squamous cell carcinoma, invasive	+																										
Sarcoma, NOS																											
Fibroma																											
Fibrosarcoma																											
Myxosarcoma																											
Liposarcoma																											
Hemangiosarcoma																											
Neurofibroma																											
Neurofibrosarcoma																											
RESPIRATORY SYSTEM																											
Lungs and bronchi	+																										
Squamous cell carcinoma, metastatic																											
Alveolar/bronchiolar carcinoma																											
Cortical carcinoma, metastatic																											
C-cell carcinoma, metastatic																											
Pheochromocytoma, metastatic																											
Sarcoma, NOS, metastatic																											
Fibrosarcoma, metastatic																											
Liposarcoma, metastatic																											
Trachea	+																										
HEMATOPOIETIC SYSTEM																											
Bone marrow	+																										
Spleen	+																										
Pheochromocytoma, metastatic																											
Sarcoma, NOS, metastatic																											
Fibroma																											
Fibrosarcoma																											
Hemangiosarcoma																											
Lymph nodes	+																										
C-cell carcinoma, metastatic																											
Pheochromocytoma, metastatic																											
Sarcoma, NOS, invasive																											
Fibrosarcoma, metastatic																											
Thymus	-																										
Carcinoma, NOS																											
Squamous cell carcinoma																											
CIRCULATORY SYSTEM																											
Heart	+																										
Liposarcoma, metastatic																											

**TABLE A2. INDIVIDUAL ANIMAL TUMOR PATHOLOGY OF MALE RATS: 1% TREMOLITE
(Continued)**

ANIMAL NUMBER	0	0	0	0	0	0	0	0	0	0	0	0	0	0	0	0	0	0	1	1	1	1	1	1	1		
	8	8	8	8	8	8	8	9	9	9	9	9	9	9	9	9	9	9	0	0	0	0	0	0	0		
WEEKS ON STUDY	2	3	4	5	6	7	8	9	0	1	2	3	4	5	6	7	8	9	0	1	2	3	4	5	6		
	1	1	1	1	1	1	1	1	1	0	1	1	0	1	1	0	1	1	0	1	1	0	1	1	1		
	4	3	3	4	2	4	2	3	3	4	9	3	3	8	2	0	4	1	0	9	1	0	3	2	3		
	6	8	6	6	9	1	9	3	9	6	0	4	7	4	2	3	8	8	9	6	1	3	3	8	4		
INTEGUMENTARY SYSTEM																											
Skin																											
Squamous cell papilloma																											
Squamous cell carcinoma																											
Basal cell tumor																											
Basal cell carcinoma																											
Trichoepithelioma																											
Keratoacanthoma																											
Fibrosarcoma																											
Subcutaneous tissue																											
Squamous cell carcinoma, invasive																											
Sarcoma, NOS																											
Fibroma																											
Fibrosarcoma																											
Myxosarcoma																											
Liposarcoma																											
Hemangiosarcoma																											
Neurofibroma																											
Neurofibrosarcoma																											
RESPIRATORY SYSTEM																											
Lungs and bronchi																											
Squamous cell carcinoma, metastatic																											
Alveolar/bronchiolar carcinoma																											
Cortical carcinoma, metastatic																											
C-cell carcinoma, metastatic																											
Pheochromocytoma, metastatic																											
Sarcoma, NOS, metastatic																											
Fibrosarcoma, metastatic																											
Liposarcoma, metastatic																											
Trachea																											
HEMATOPOIETIC SYSTEM																											
Bone marrow																											
Spleen																											
Pheochromocytoma, metastatic																											
Sarcoma, NOS, metastatic																											
Fibroma																											
Fibrosarcoma																											
Hemangiosarcoma																											
Lymph nodes																											
C-cell carcinoma, metastatic																											
Pheochromocytoma, metastatic																											
Sarcoma, NOS, invasive																											
Fibrosarcoma, metastatic																											
Thymus																											
Carcinoma, NOS																											
Squamous cell carcinoma																											
CIRCULATORY SYSTEM																											
Heart																											
Liposarcoma, metastatic																											

**TABLE A2. INDIVIDUAL ANIMAL TUMOR PATHOLOGY OF MALE RATS: 1% TREMOLITE
(Continued)**

ANIMAL NUMBER	1	1	1	1	1	1	1	1	1	1	1	1	1	1	1	1	1	1	2	2	2	2	2	2	2
WEEKS ON STUDY	8	8	8	8	8	8	8	9	9	9	9	9	9	9	9	9	9	9	0	0	0	0	0	0	0
	2	3	4	5	6	7	8	9	0	1	2	3	4	5	6	7	8	9	0	1	2	3	4	5	6
INTEGUMENTARY SYSTEM																									
Skin	+	+	+	+	+	+	+	+	+	+	+	+	+	+	+	+	+	+	+	+	+	+	+	+	N
Squamous cell papilloma																									
Squamous cell carcinoma																									
Basal cell tumor																									
Basal cell carcinoma																									
Trichoepithelioma																									
Keratoacanthoma																									
Fibrosarcoma																									
Subcutaneous tissue	+	+	+	+	+	+	+	+	+	+	+	+	+	+	+	+	+	+	+	+	+	+	+	+	N
Squamous cell carcinoma, invasive																									
Sarcoma, NOS																									
Fibroma				X			X				X	X					X				X				
Fibrosarcoma																									
Myxosarcoma																									
Liposarcoma																									
Hemangiosarcoma																									
Neurofibroma																									
Neurofibrosarcoma													X						X						
RESPIRATORY SYSTEM																									
Lungs and bronchi	+	+	+	+	+	+	+	+	+	+	+	+	+	+	+	+	+	+	+	+	+	+	+	+	+
Squamous cell carcinoma, metastatic																							X		
Alveolar/bronchiolar carcinoma																									
Cortical carcinoma, metastatic																									
C-cell carcinoma, metastatic																									
Pheochromocytoma, metastatic																									
Sarcoma, NOS, metastatic																									
Fibrosarcoma, metastatic																									
Liposarcoma, metastatic																									
Trachea	+	+	+	+	+	+	+	+	+	+	+	+	+	+	+	+	+	+	+	+	+	+	+	+	+
HEMATOPOIETIC SYSTEM																									
Bone marrow	+	+	+	+	+	+	+	-	+	+	+	+	+	+	+	+	+	+	+	+	+	+	+	+	+
Spleen	+	+	+	+	+	+	+	+	+	+	+	+	+	+	+	+	+	+	+	+	+	+	+	+	+
Pheochromocytoma, metastatic																									
Sarcoma, NOS, metastatic																									
Fibroma																									
Fibrosarcoma																									
Hemangiosarcoma																									
Lymph nodes	+	+	+	+	+	+	+	+	+	+	+	+	+	+	+	+	+	+	+	+	+	+	+	+	+
C-cell carcinoma, metastatic																									
Pheochromocytoma, metastatic																									
Sarcoma, NOS, invasive																									
Fibrosarcoma, metastatic																									
Thymus	+	+	+	+	+	+	+	+	+	-	-	+	+	-	+	+	+	-	+	+	-	-	+	-	+
Carcinoma, NOS																									
Squamous cell carcinoma																									
CIRCULATORY SYSTEM																									
Heart	+	+	+	+	+	+	+	+	+	+	+	+	+	+	+	+	+	+	+	+	+	+	+	+	+
Liposarcoma, metastatic																									

TABLE A2. INDIVIDUAL ANIMAL TUMOR PATHOLOGY OF MALE RATS: 1% TREMOLITE
(Continued)

ANIMAL NUMBER	207	208	209	210	211	212	213	214	215	216	217	218	219	220	221	222	223	224	225	226	227	228	229	230	231	232	233	234	235	236	237	238	239	240			
WEEKS ON STUDY	13	18	25	32	39	46	53	60	67	74	81	88	95	102	109	116	123	130	137	144	151	158	165	172	179	186	193	200	207	214	221	228	235	242			
INTEGUMENTARY SYSTEM																																					
Skin	N	+	+	+	+	+	+	+	+	+	+	+	+	+	+	+	+	+	+	+	+	+	+	+	+	+	+	+	+	+	+	+	+	+			
Squamous cell papilloma									X																												
Squamous cell carcinoma																																					
Basal cell tumor																																					
Basal cell carcinoma									X																												
Trichoepithelioma																																					
Keratoacanthoma																																					
Fibrosarcoma																																					
Subcutaneous tissue	N	+	+	+	+	+	+	+	+	+	+	+	+	+	+	+	+	+	+	+	+	+	+	+	+	+	+	+	+	+	+	+	+	+	+	+	
Squamous cell carcinoma, invasive																																					
Sarcoma, NOS																																					
Fibroma			X	X																																	
Fibrosarcoma																																					
Myxosarcoma																																					
Liposarcoma																																					
Hemangiosarcoma																																					
Neurofibroma																																					
Neurofibrosarcoma																																					
RESPIRATORY SYSTEM																																					
Lungs and bronchi	+	+	+	+	+	+	+	+	+	+	+	+	+	+	+	+	+	+	+	+	+	+	+	+	+	+	+	+	+	+	+	+	+	+	+	+	
Squamous cell carcinoma, metastatic																																					
Alveolar/bronchiolar carcinoma																																					
Cortical carcinoma, metastatic																																					
C-cell carcinoma, metastatic																																					
Pheochromocytoma, metastatic																																					
Sarcoma, NOS, metastatic																																					
Fibrosarcoma, metastatic																																					
Liposarcoma, metastatic																																					
Trachea	+	+	+	+	+	+	+	+	+	+	+	+	+	+	+	+	+	+	+	+	+	+	+	+	+	+	+	+	+	+	+	+	+	+	+	+	
HEMATOPOIETIC SYSTEM																																					
Bone marrow	+	+	+	+	+	+	+	+	+	+	+	+	+	+	+	+	+	+	+	+	+	+	+	+	+	+	+	+	+	+	+	+	+	+	+	+	
Spleen	+	+	+	+	+	+	+	+	+	+	+	+	+	+	+	+	+	+	+	+	+	+	+	+	+	+	+	+	+	+	+	+	+	+	+	+	
Pheochromocytoma, metastatic																																					
Sarcoma, NOS, metastatic																																					
Fibroma																																					
Fibrosarcoma																																					
Hemangiosarcoma																																					
Lymph nodes	+	+	+	+	+	+	+	+	+	+	+	+	+	+	+	+	+	+	+	+	+	+	+	+	+	+	+	+	+	+	+	+	+	+	+	+	
C-cell carcinoma, metastatic																																					
Pheochromocytoma, metastatic																																					
Sarcoma, NOS, invasive																																					
Fibrosarcoma, metastatic																																					
Thymus	+	+	-	+	+	+	+	+	+	+	+	+	+	+	+	+	+	+	+	+	+	+	+	+	+	+	+	+	+	+	+	+	+	+	+	+	
Carcinoma, NOS																																					
Squamous cell carcinoma																																					
CIRCULATORY SYSTEM																																					
Heart	+	+	+	+	+	+	+	+	+	+	+	+	+	+	+	+	+	+	+	+	+	+	+	+	+	+	+	+	+	+	+	+	+	+	+	+	
Liposarcoma, metastatic																																					

TABLE A2. INDIVIDUAL ANIMAL TUMOR PATHOLOGY OF MALE RATS: 1% TREMOLITE
(Continued)

NUMBER	5 7	5 8	5 9	6 0	6 1	6 2	6 3	6 4	6 5	6 6	6 7	6 8	6 9	7 0	7 1	7 2	7 3	7 4	7 5	7 6	7 7	7 8	7 9	8 0	8 1	TOTAL TISSUES TUMORS	
WEEKS ON STUDY	1 1 5	1 4 6	1 2 5	1 4 4	1 4 0	1 4 0	1 2 9	1 4 3	0 1 4	1 1 9	1 3 9	1 4 5	1 2 3	1 4 0	1 3 4	1 4 6	1 2 7	0 8 6	1 1 6	0 9 5	1 4 5	1 4 5	1 3 3	1 2 8	0 8 5		
INTEGUMENTARY SYSTEM																											
Skin																											
Squamous cell papilloma	+	+	+	+	+	+	+	+	+	+	+	+	+	+	+	+	+	+	+	+	+	+	+	+	+	+	*250
Squamous cell carcinoma			X								X															9	
Basal cell tumor																										4	
Basal cell carcinoma																										2	
Trichoepithelioma																										6	
Keratoacanthoma																	X									13	
Fibrosarcoma																										1	
Subcutaneous tissue																											
Squamous cell carcinoma, invasive	+	+	+	-	+	+	+	+	+	+	+	+	+	+	+	+	+	+	+	+	+	+	+	+	+	*250	
Sarcoma, NOS	X																									1	
Fibroma																										3	
Fibrosarcoma		X		X	X		X	X																		36	
Myxosarcoma																							X			11	
Liposarcoma																											
Hemangiosarcoma																											
Neurofibroma																											
Neurofibrosarcoma																											
RESPIRATORY SYSTEM																											
Lungs and bronchi																											
Squamous cell carcinoma, metastatic	+	+	+	+	+	+	+	+	+	+	+	+	+	+	+	+	+	+	+	+	+	+	+	+	+	250	
Alveolar/bronchiolar carcinoma																										1	
Cortical carcinoma, metastatic																										2	
C-cell carcinoma, metastatic																										1	
Pheochromocytoma, metastatic							X																			5	
Sarcoma, NOS, metastatic																										3	
Fibrosarcoma, metastatic	X																									1	
Liposarcoma, metastatic																										1	
Trachea	+	+	+	+	+	+	+	+	+	+	+	+	+	+	+	+	+	+	+	+	+	+	+	+	+	2	
																										250	
HEMATOPOIETIC SYSTEM																											
Bone marrow																											
Pheochromocytoma, metastatic	+	+	+	+	+	+	+	+	+	+	+	+	+	+	+	+	+	+	+	+	+	+	+	+	+	248	
Sarcoma, NOS, metastatic	+	+	+	+	+	+	+	+	+	+	+	+	+	+	+	+	+	+	+	+	+	+	+	+	+	250	
Fibroma																										1	
Fibrosarcoma																										1	
Hemangiosarcoma																										1	
Lymph nodes																										4	
Lymph nodes																											
C-cell carcinoma, metastatic	+	+	+	+	+	+	+	+	+	+	+	+	+	+	+	+	+	+	+	+	+	+	+	+	+	250	
Pheochromocytoma, metastatic																	X									2	
Sarcoma, NOS, invasive																										1	
Fibrosarcoma, metastatic																										2	
Thymus																										1	
Carcinoma, NOS	+	+	+	+	+	+	+	+	+	+	+	+	+	+	+	+	+	+	+	+	+	+	+	+	+	196	
Squamous cell carcinoma																										1	
CIRCULATORY SYSTEM																											
Heart																											
Liposarcoma, metastatic	+	+	+	+	+	+	+	+	+	+	+	+	+	+	+	+	+	+	+	+	+	+	+	+	+	250	

* Animals necropsied

TABLE A2. INDIVIDUAL ANIMAL TUMOR PATHOLOGY OF MALE RATS: 1% TREMOLITE
(Continued)

ANIMAL NUMBER	057	058	059	060	061	062	063	064	065	066	067	068	069	070	071	072	073	074	075	076	077	078	079	080	081	
WEEKS ON STUDY	146	140	132	130	134	134	134	134	134	134	134	134	134	134	134	134	134	134	134	134	134	134	134	134	134	
DIGESTIVE SYSTEM																										
Oral cavity	N	N	N	N	N	N	N	N	N	N	N	N	N	N	N	N	N	N	N	N	N	N	N	N	N	N
Squamous cell carcinoma																										
Salivary gland	+	+	+	+	+	+	+	+	+	+	+	+	+	+	+	+	+	+	+	+	+	+	+	+	+	+
Sarcoma, NOS																										
Fibrosarcoma																										
Liver	+	+	+	+	+	+	+	+	+	+	+	+	+	+	+	+	+	+	+	+	+	+	+	+	+	+
Bile duct carcinoma																										
Neoplastic nodule																										
Hepatocellular carcinoma	X																									
Monocytic leukemia																										
Bile duct	+	+	+	+	+	+	+	+	+	+	+	+	+	+	+	+	+	+	+	+	+	+	+	+	+	+
Gallbladder & common bile duct	N	N	N	N	N	N	N	N	N	N	N	N	N	N	N	N	N	N	N	N	N	N	N	N	N	N
Pancreas	+	+	+	+	+	+	+	+	+	+	+	+	+	+	+	+	+	+	+	+	+	+	+	+	+	+
Carcinoma, NOS																										
Transitional cell carcinoma, invasive																										
Acinar cell adenoma																										X
Acinar cell carcinoma																										
Mixed tumor, benign																										
Esophagus	+	+	+	+	+	+	+	+	+	+	+	+	+	+	+	+	+	+	+	+	+	+	+	+	+	+
Stomach	+	+	+	+	+	+	+	+	+	+	+	+	+	+	+	+	+	+	+	+	+	+	+	+	+	+
Squamous cell papilloma																										
Squamous cell carcinoma																										
Sarcoma, NOS																										X
Small intestine	+	+	+	+	+	+	+	+	+	+	+	+	+	+	+	+	+	+	+	+	+	+	+	+	+	+
Adenomatous polyp, NOS																										
Mucinous cystadenocarcinoma																										
Sarcoma, NOS, metastatic																										X
Fibroma																										
Leiomyoma																										
Leiomyosarcoma																										
Large intestine	+	+	+	+	+	+	+	+	+	+	+	+	+	+	+	+	+	+	+	+	+	+	+	+	+	+
Adenomatous polyp, NOS																										
Mucinous cystadenocarcinoma																										
URINARY SYSTEM																										
Kidney	+	+	+	+	+	+	+	+	+	+	+	+	+	+	+	+	+	+	+	+	+	+	+	+	+	+
Transitional cell carcinoma																										
Tubular cell adenoma																										
Tubular cell adenocarcinoma																										X
Sarcoma, NOS																										
Urinary bladder	+	+	+	+	+	+	+	+	+	+	+	+	+	+	+	+	+	+	+	+	+	+	+	+	+	+
ENDOCRINE SYSTEM																										
Pituitary	+	+	+	+	+	+	+	+	+	+	+	+	+	+	+	+	+	+	+	+	+	+	+	+	+	+
Carcinoma, NOS				X																						
Adenoma, NOS						X			X																X	
Adrenal	+	+	+	+	+	+	+	+	+	+	+	+	+	+	+	+	+	+	+	+	+	+	+	+	+	+
Cortical adenoma				X																						
Cortical carcinoma																										
Pheochromocytoma	X		X				X		X				X	X												X
Pheochromocytoma, malignant																										
Ganglioneuroma																										
Thyroid	+	+	+	+	+	+	+	+	+	+	+	+	+	+	+	+	+	+	+	+	+	+	+	+	+	+
Follicular cell adenoma																										
Follicular cell carcinoma																										
C-cell adenoma				X																						
C-cell carcinoma	X	X					X																			X
Parathyroid	+	+	+	+	+	+	+	+	+	+	+	+	+	+	+	+	+	+	+	+	+	+	+	+	+	+
Adenoma, NOS																										
Pancreatic islets	+	+	+	+	+	+	+	+	+	+	+	+	+	+	+	+	+	+	+	+	+	+	+	+	+	+
Islet cell adenoma																										
Islet cell carcinoma																										X

**TABLE A2. INDIVIDUAL ANIMAL TUMOR PATHOLOGY OF MALE RATS: 1% TREMOLITE
(Continued)**

ANIMAL NUMBER	0	0	0	0	0	0	0	0	0	0	0	0	0	0	0	0	0	0	1	1	1	1	1	1	1	1	
	8	8	8	8	8	8	8	8	9	9	9	9	9	9	9	9	9	9	0	0	0	0	0	0	0	0	
WEEKS ON STUDY	1	1	1	1	1	1	1	1	1	0	1	1	0	1	1	0	1	1	0	1	1	0	1	1	1	1	
	4	3	3	4	2	4	2	3	3	4	9	3	3	8	2	0	4	1	0	9	1	0	3	3	2	3	
	6	8	6	6	9	1	9	3	9	6	0	4	7	4	2	3	8	8	9	6	1	3	3	8	4		
DIGESTIVE SYSTEM																											
Oral cavity	N	N	N	N	N	N	N	N	N	N	N	N	N	N	N	N	N	N	N	N	N	N	N	N	N	N	
Squamous cell carcinoma																											
Salivary gland	+	+	+	+	+	+	+	+	+	+	+	-	+	+	+	+	+	+	+	+	+	+	+	+	+	+	
Sarcoma, NOS																											
Fibrosarcoma																											
Liver	+	+	+	+	+	+	+	+	+	+	+	+	+	+	+	+	+	+	+	+	+	+	+	+	+	+	
Bile duct carcinoma																											
Neoplastic nodule																											
Hepatocellular carcinoma																											
Monocytic leukemia																											
Bile duct																											
Gallbladder & common bile duct	N	N	N	N	N	N	N	N	N	N	N	N	N	N	N	N	N	N	N	N	N	N	N	N	N	N	
Pancreas	+	+	+	+	+	+	+	+	+	+	+	+	+	+	+	+	+	+	+	+	+	+	+	+	+	+	
Carcinoma, NOS																											
Transitional cell carcinoma, invasive																											
Acinar cell adenoma																											
Acinar cell carcinoma														X												X	
Mixed tumor, benign																											
Esophagus	+	+	+	+	+	+	+	+	+	+	+	+	+	+	+	+	+	+	+	+	+	+	+	+	+	+	
Stomach	+	+	+	+	+	+	+	+	+	+	+	+	+	+	+	+	+	+	+	+	+	+	+	+	+	+	
Squamous cell papilloma																											
Squamous cell carcinoma																											
Sarcoma, NOS																											
Small intestine	+	+	+	+	+	+	+	+	+	+	+	+	+	+	+	+	+	+	+	+	+	+	+	+	+	+	
Adenomatous polyp, NOS																											
Mucinous cystadenocarcinoma																											
Sarcoma, NOS, metastatic																											
Fibroma																											
Leiomyoma																											
Leiomyosarcoma																											
Large intestine	+	+	+	+	+	+	+	+	+	+	+	+	+	+	+	+	+	+	+	+	+	+	+	+	+	+	
Adenomatous polyp, NOS																											
Mucinous cystadenocarcinoma																											
URINARY SYSTEM																											
Kidney	+	+	+	+	+	+	+	+	+	+	+	+	+	+	+	+	+	+	+	+	+	+	+	+	+	+	
Transitional cell carcinoma																											
Tubular cell adenoma																											
Tubular cell adenocarcinoma																											
Sarcoma, NOS																											
Urinary bladder	+	+	+	+	+	+	+	+	+	+	+	+	+	+	+	+	+	+	+	+	+	+	+	+	+	+	
ENDOCRINE SYSTEM																											
Pituitary	+	+	+	+	+	+	+	+	+	+	+	+	+	+	+	+	+	+	+	+	+	+	+	+	+	+	
Carcinoma, NOS																											
Adenoma, NOS																										X	
Adrenal	+	+	+	+	+	+	+	+	+	+	+	+	+	+	+	+	+	+	+	+	+	+	+	+	+	+	
Cortical adenoma																											
Cortical carcinoma																											
Pheochromocytoma																											
Pheochromocytoma, malignant																											
Ganglioneuroma																											
Thyroid	+	+	+	+	+	+	+	+	+	+	+	+	+	+	+	+	+	+	+	+	+	+	+	+	+	+	
Follicular cell adenoma																											
Follicular cell carcinoma																										X	
C cell adenoma																											
C cell carcinoma																											
Parathyroid	+	+	+	+	+	+	+	+	+	+	+	+	+	+	+	+	+	+	+	+	+	+	+	+	+	+	
Adenoma, NOS																											
Pancreatic islets	+	+	+	+	+	+	+	+	+	+	+	+	+	+	+	+	+	+	+	+	+	+	+	+	+	+	
Islet cell adenoma																											
Islet cell carcinoma																											

TABLE A2. INDIVIDUAL ANIMAL TUMOR PATHOLOGY OF MALE RATS: 1% TREMOLITE
(Continued)

ANIMAL NUMBER	1 5 7	1 5 8	1 5 9	1 6 0	1 6 1	1 6 2	1 6 3	1 6 4	1 6 5	1 6 6	1 6 7	1 6 8	1 6 9	1 7 0	1 7 1	1 7 2	1 7 3	1 7 4	1 7 5	1 7 6	1 7 7	1 7 8	1 7 9	1 8 0	1 8 1		
WEEKS ON STUDY	4 1	2 2	0 8	1 6	3 5	3 8	2 3	2 8	1 5	2 3	1 1	1 6	3 3	1 1	0 5	0 3	1 2	1 3	3 8	9 8	4 6	1 0	2 1	7 5	1 1	4 6	
DIGESTIVE SYSTEM																											
Oral cavity	N	N	N	N	N	N	N	N	N	N	N	N	N	N	N	N	N	N	N	N	N	N	N	N	N	N	N
Squamous cell carcinoma																											
Salivary gland	+	+	+	+	-	+	+	+	+	+	+	+	+	+	+	+	+	+	+	+	+	+	+	+	+	+	+
Sarcoma, NOS																											
Fibrosarcoma																											
Liver	+	+	+	+	+	+	+	+	+	+	+	+	+	+	+	+	+	+	+	+	+	+	+	+	+	+	+
Bile duct carcinoma																											
Neoplastic nodule			X																								
Hepatocellular carcinoma																											
Monocytic leukemia																											
Bile duct	+	+	+	+	+	+	+	+	+	+	+	+	+	+	+	+	+	+	+	+	+	+	+	+	+	+	+
Gallbladder & common bile duct	N	N	N	N	N	N	N	N	N	N	N	N	N	N	N	N	N	N	N	N	N	N	N	N	N	N	N
Pancreas	+	+	+	+	+	+	+	+	+	+	+	+	+	+	+	+	+	+	+	+	+	+	+	+	+	+	+
Carcinoma, NOS																											
Transitional cell carcinoma, invasive																											
Acinar cell adenoma	X																										
Acinar cell carcinoma																											
Mixed tumor, benign																											
Esophagus	+	+	+	+	+	+	+	+	+	+	+	+	+	+	+	+	+	+	+	+	+	+	+	+	+	+	+
Stomach	+	+	+	+	+	+	+	+	+	+	+	+	+	+	+	+	+	+	+	+	+	+	+	+	+	+	+
Squamous cell papilloma																											
Squamous cell carcinoma																											
Sarcoma, NOS																											
Small intestine	+	+	+	+	+	+	+	+	+	+	+	+	+	+	+	+	+	+	+	+	+	+	+	+	+	+	+
Adenomatous polyp, NOS																											
Mucinous cystadenocarcinoma																											
Sarcoma, NOS, metastatic																											
Fibroma																											
Leiomyoma																											
Leiomyosarcoma																											
Large intestine	+	+	+	+	+	+	+	+	+	+	+	+	+	+	+	+	+	+	+	+	+	+	+	+	+	+	+
Adenomatous polyp, NOS																											
Mucinous cystadenocarcinoma																											
URINARY SYSTEM																											
Kidney	+	+	+	+	+	+	+	+	+	+	+	+	+	+	+	+	+	+	+	+	+	+	+	+	+	+	+
Transitional cell carcinoma																											
Tubular cell adenoma																											
Tubular cell adenocarcinoma																											
Sarcoma, NOS																											
Urinary bladder	+	+	+	+	+	+	+	+	+	+	+	+	+	+	+	+	+	+	+	+	+	+	+	+	+	+	+
ENDOCRINE SYSTEM																											
Pituitary	+	+	-	+	+	+	+	+	+	+	+	+	+	+	+	+	+	+	+	+	+	+	+	+	+	+	+
Carcinoma, NOS																											
Adenoma, NOS																											
Adrenal	+	+	+	+	+	+	+	+	+	+	+	+	+	+	+	+	+	+	+	+	+	+	+	+	+	+	+
Cortical adenoma																											
Cortical carcinoma																											
Pheochromocytoma																											
Pheochromocytoma, malignant																											
Ganglioneuroma																											
Thyroid	+	+	+	+	-	+	+	+	+	+	+	+	+	+	+	+	+	+	+	+	+	+	+	+	+	+	+
Follicular cell adenoma																											
Follicular cell carcinoma																											
C-cell adenoma																											
C-cell carcinoma			X																								
Parathyroid	+	+	+	+	-	+	+	+	+	+	+	+	+	+	+	+	+	+	+	+	+	+	+	+	+	+	+
Adenoma, NOS																											
Pancreatic islets	+	+	+	+	+	+	+	+	+	+	+	+	+	+	+	+	+	+	+	+	+	+	+	+	+	+	+
Islet cell adenoma																											
Islet cell carcinoma			X																								

**TABLE A2. INDIVIDUAL ANIMAL TUMOR PATHOLOGY OF MALE RATS: 1% TREMOLITE
(Continued)**

ANIMAL NUMBER	1 8 2	1 8 3	1 8 4	1 8 5	1 8 6	1 8 7	1 8 8	1 8 8	1 9 0	1 9 1	1 9 2	1 9 3	1 9 4	1 9 5	1 9 6	1 9 7	1 9 8	1 9 9	2 0 0	2 0 1	2 0 2	2 0 3	2 0 4	2 0 5	2 0 6		
WEEKS ON STUDY	1 9	1 1	1 0	1 2	1 2	1 3	1 8	1 2	1 3	1 8	1 4	1 1	1 2	1 3	1 8	1 4	1 3	1 3	1 2	1 2	1 0	1 9	1 8	1 3	1 7	1 1	
DIGESTIVE SYSTEM																											
Oral cavity	N	N	N	N	N	N	N	N	N	N	N	N	N	N	N	N	N	N	N	N	N	N	N	N	N	N	N
Squamous cell carcinoma																											
Salivary gland	+	+	+	+	+	+	+	+	+	+	+	+	+	+	+	+	+	+	+	+	+	+	+	+	+	+	+
Sarcoma, NOS																											
Fibrosarcoma																											
Liver	+	+	+	+	+	+	+	+	+	+	+	+	+	+	+	+	+	+	+	+	+	+	+	+	+	+	+
Bile duct carcinoma																											
Neoplastic nodule																											
Hepatocellular carcinoma																											
Monocytic leukemia																											
Bile duct																											
Gallbladder & common bile duct	N	N	N	N	N	N	N	N	N	N	N	N	N	N	N	N	N	N	N	N	N	N	N	N	N	N	N
Pancreas	+	+	+	+	+	+	+	+	+	+	+	+	+	+	+	+	+	+	+	+	+	+	+	+	+	+	+
Carcinoma, NOS																											
Transitional cell carcinoma, invasive																											
Acinar cell adenoma																											
Acinar cell carcinoma																											
Mixed tumor, benign																											
Esophagus	+	+	+	+	+	+	+	+	+	+	+	+	+	+	+	+	+	+	+	+	+	+	+	+	+	+	+
Stomach	+	+	+	+	+	+	+	+	+	+	+	+	+	+	+	+	+	+	+	+	+	+	+	+	+	+	+
Squamous cell papilloma																											
Squamous cell carcinoma																											
Sarcoma, NOS																											
Small intestine	+	+	+	+	+	+	+	+	+	+	+	+	+	+	+	+	+	+	+	+	+	+	+	+	+	+	+
Adenomatous polyp, NOS																											
Mucinous cystadenocarcinoma																											
Sarcoma, NOS, metastatic																											
Fibroma																											
Leiomyoma																											
Leiomyosarcoma																											
Large intestine	+	+	+	+	+	+	+	+	+	+	+	+	+	+	+	+	+	+	+	+	+	+	+	+	+	+	+
Adenomatous polyp, NOS																											
Mucinous cystadenocarcinoma																											
URINARY SYSTEM																											
Kidney	+	+	+	+	+	+	+	+	+	+	+	+	+	+	+	+	+	+	+	+	+	+	+	+	+	+	+
Transitional cell carcinoma																											
Tubular cell adenoma																											
Tubular cell adenocarcinoma																											
Sarcoma, NOS																											
Urinary bladder	+	+	+	+	+	+	+	+	+	+	+	+	+	+	+	+	+	+	+	+	+	+	+	+	+	+	+
ENDOCRINE SYSTEM																											
Pituitary	+	+	+	+	+	+	+	+	+	+	+	+	+	+	+	+	+	+	+	+	+	+	+	+	+	+	+
Carcinoma, NOS																											
Adenoma, NOS																											
Adrenal	+	+	+	+	+	+	+	+	+	+	+	+	+	+	+	+	+	+	+	+	+	+	+	+	+	+	+
Cortical adenoma																											
Cortical carcinoma																											
Pheochromocytoma																											
Pheochromocytoma, malignant																											
Ganglioneuroma																											
Thyroid	+	+	+	+	+	+	+	+	+	+	+	+	+	+	+	+	+	+	+	+	+	+	+	+	+	+	+
Follicular cell adenoma																											
Follicular cell carcinoma																											
C-cell adenoma																											
C-cell carcinoma																											
Parathyroid	-	+	+	+	+	+	+	+	+	+	+	+	+	+	+	+	+	+	+	+	+	+	+	+	+	+	+
Adenoma, NOS																											
Pancreatic islets	+	+	+	+	+	+	+	+	+	+	+	+	+	+	+	+	+	+	+	+	+	+	+	+	+	+	+
Islet cell adenoma																											
Islet cell carcinoma																											

**TABLE A2. INDIVIDUAL ANIMAL TUMOR PATHOLOGY OF MALE RATS: 1% TREMOLITE
(Continued)**

ANIMAL NUMBER	207	208	209	210	211	212	213	214	215	216	217	218	219	220	221	222	223	224	225	226	227	228	229	230	231	232	233	234	235	236	237	238	239	240				
WEEKS ON STUDY	13	18	25	32	40	48	56	64	72	80	88	96	104	112	120	128	136	144	152	160	168	176	184	192	200	208	216	224	232	240	248	256	264	272				
DIGESTIVE SYSTEM																																						
Oral cavity	N	N	N	N	N	N	N	N	N	N	N	N	N	N	N	N	N	N	N	N	N	N	N	N	N	N	N	N	N	N	N	N	N	N	N			
Squamous cell carcinoma																																						
Salivary gland																																						
Sarcoma, NOS	+	-	+	+	+	+	+	+	+	+	+	+	+	+	+	+	+	+	+	+	+	+	+	+	+	+	+	+	+	+	+	+	+	+	+	+		
Fibrosarcoma																																						
Liver																																						
Bile duct carcinoma																																						
Neoplastic nodule	X																																					
Hepatocellular carcinoma																																						
Monocytic leukemia																																						
Bile duct	+	+	+	+	+	+	+	+	+	+	+	+	+	+	+	+	+	+	+	+	+	+	+	+	+	+	+	+	+	+	+	+	+	+	+	+	+	
Gallbladder & common bile duct	N	N	N	N	N	N	N	N	N	N	N	N	N	N	N	N	N	N	N	N	N	N	N	N	N	N	N	N	N	N	N	N	N	N	N	N	N	
Pancreas	+	+	+	+	+	+	+	+	+	+	+	+	+	+	+	+	+	+	+	+	+	+	+	+	+	+	+	+	+	+	+	+	+	+	+	+	+	+
Carcinoma, NOS																																						
Transitional cell carcinoma, invasive																																						
Acinar cell adenoma																																						
Acinar cell carcinoma																																						
Mixed tumor, benign																																						
Esophagus	+	+	+	+	+	+	+	+	+	+	+	+	+	+	+	+	+	+	+	+	+	+	+	+	+	+	+	+	+	+	+	+	+	+	+	+	+	
Stomach	+	+	+	+	+	+	+	+	+	+	+	+	+	+	+	+	+	+	+	+	+	+	+	+	+	+	+	+	+	+	+	+	+	+	+	+	+	+
Squamous cell papilloma																																						
Squamous cell carcinoma																																						
Sarcoma, NOS																																						
Small intestine	+	+	+	+	+	+	+	+	+	+	+	+	+	+	+	+	+	+	+	+	+	+	+	+	+	+	+	+	+	+	+	+	+	+	+	+	+	+
Adenomatous polyp, NOS																																						
Mucinous cystadenocarcinoma																																						
Sarcoma, NOS, metastatic																																						
Fibroma																																						
Leiomyoma																																						
Leiomyosarcoma																																						
Large intestine	+	+	+	+	+	+	+	+	+	+	+	+	+	+	+	+	+	+	+	+	+	+	+	+	+	+	+	+	+	+	+	+	+	+	+	+	+	+
Adenomatous polyp, NOS																																						
Mucinous cystadenocarcinoma				X																																		
URINARY SYSTEM																																						
Kidney	+	+	+	+	+	+	+	+	+	+	+	+	+	+	+	+	+	+	+	+	+	+	+	+	+	+	+	+	+	+	+	+	+	+	+	+	+	+
Transitional cell carcinoma																																						
Tubular cell adenoma																																						
Tubular cell adenocarcinoma																																						
Sarcoma, NOS																																						
Urinary bladder	+	+	+	+	+	+	+	+	+	+	+	+	+	+	+	+	+	+	+	+	+	+	+	+	+	+	+	+	+	+	+	+	+	+	+	+	+	+
ENDOCRINE SYSTEM																																						
Pituitary	+	-	+	+	+	+	+	+	+	+	+	+	+	+	+	+	+	+	+	+	+	+	+	+	+	+	+	+	+	+	+	+	+	+	+	+	+	+
Carcinoma, NOS																																						
Adenoma, NOS																																						
Adrenal	+	+	+	+	+	+	+	+	+	+	+	+	+	+	+	+	+	+	+	+	+	+	+	+	+	+	+	+	+	+	+	+	+	+	+	+	+	+
Cortical adenoma																																						
Cortical carcinoma																																						
Pheochromocytoma																																						
Pheochromocytoma, malignant																																						
Ganglioneuroma																																						
Thyroid	+	-	+	+	+	+	+	+	+	+	+	+	+	+	+	+	+	+	+	+	+	+	+	+	+	+	+	+	+	+	+	+	+	+	+	+	+	
Follicular cell adenoma																																						
Follicular cell carcinoma																																						
C-cell adenoma																																						
C-cell carcinoma																																						
Parathyroid	+	-	+	+	+	+	+	+	+	+	+	+	+	+	+	+	+	+	+	+	+	+	+	+	+	+	+	+	+	+	+	+	+	+	+	+	+	+
Adenoma, NOS																																						
Pancreatic islets	+	+	+	+	+	+	+	+	+	+	+	+	+	+	+	+	+	+	+	+	+	+	+	+	+	+	+	+	+	+	+	+	+	+	+	+	+	+
Islet cell adenoma																																						
Islet cell carcinoma	X																																					

TABLE A2. INDIVIDUAL ANIMAL TUMOR PATHOLOGY OF MALE RATS: 1% TREMOLITE
(Continued)

ANIMAL NUMBER	057	058	059	060	061	062	063	064	065	066	067	068	069	070	071	072	073	074	075	076	077	078	079	080	081
WEEKS ON STUDY	146	140	132	110	103	104	111	111	122	122	144	144	133	188	144	133	100	133	133	199	111	111	111	111	111
REPRODUCTIVE SYSTEM																									
Mammary gland	+	+	+	+	+	+	+	+	+	+	+	+	+	+	+	+	+	+	+	+	+	+	+	N	+
Adenoma, NOS																									
Adenocarcinoma, NOS																									
Papillary adenocarcinoma																									
Fibroadenoma			X				X							X						X				X	
Testis	+	+	+	+	+	+	+	+	+	+	+	+	+	+	+	+	+	+	+	+	+	+	+	+	+
Interstitial cell tumor	X	X	X	X	X	X	X	X	X	X	X	X	X	X	X	X	X	X	X	X	X	X	X	X	X
Prostate	+	+	+	+	+	+	+	+	+	+	+	+	+	+	+	+	+	+	+	+	+	+	+	+	+
Penis	N	N	N	N	N	N	N	N	N	N	N	N	N	N	N	N	N	N	N	N	N	N	N	N	N
Keratoacanthoma																									
Preputial/clitoral gland																									
Squamous cell carcinoma																									
Epididymis	N	N	N	N	N	N	N	N	N	N	N	N	N	N	N	N	N	N	N	N	N	N	N	N	N
Lipoma																									
Mesothelioma, invasive																									
NERVOUS SYSTEM																									
Brain	+	+	+	+	+	+	+	+	+	+	+	+	+	+	+	+	+	+	+	+	+	+	+	+	+
Carcinoma, NOS, invasive																									
Astrocytoma																									
Spinal cord	N	N	N	N	N	N	N	N	N	N	N	N	N	N	N	N	N	N	N	N	N	N	N	N	N
Astrocytoma																									
SPECIAL SENSE ORGANS																									
Zymbal gland	+	+	+	+	+	+	+	+	+	+	+	+	+	+	+	+	+	+	+	+	+	+	+	+	+
Squamous cell carcinoma																									
Keratoacanthoma																									
MUSCULOSKELETAL SYSTEM																									
Bone	N	N	N	N	N	N	N	N	N	N	N	N	N	N	N	N	N	N	N	N	N	N	N	N	N
Squamous cell carcinoma, invasive																									
Fibrosarcoma, invasive																									
Liposarcoma, invasive																									
Osteosarcoma																									
BODY CAVITIES																									
Mediastinum	N	N	N	N	N	N	N	N	N	N	N	N	N	N	N	N	N	N	N	N	N	N	N	N	N
Fibrosarcoma, invasive																									
Peritoneum	N	N	N	N	N	N	N	N	N	N	N	N	N	N	N	N	N	N	N	N	N	N	N	N	N
Fibrosarcoma																									
Liposarcoma																									
Tunica vaginalis	+	+	+	+	+	+	+	+	+	+	+	+	+	+	+	+	+	+	+	+	+	+	+	+	+
Mesothelioma, malignant																									
Mesentery	N	N	N	N	N	N	N	N	N	N	N	N	N	N	N	N	N	N	N	N	N	N	N	N	N
Pheochromocytoma, metastatic																									
Sarcoma, NOS																									
Fibrosarcoma																									
Hemangiosarcoma																									
ALL OTHER SYSTEMS																									
Multiple organs, NOS	N	N	N	N	N	N	N	N	N	N	N	N	N	N	N	N	N	N	N	N	N	N	N	N	N
Carcinoma, NOS, invasive																									
Squamous cell carcinoma, invasive																									
Transitional cell carcinoma, metastatic																									
Sarcoma, NOS, invasive																									
Fibrosarcoma, invasive																									
Fibrous histiocytoma, malignant																									
Mesothelioma, invasive																									
Mesothelioma, metastatic																									
Malignant lymphoma, histiocytic type																									
Myelomonocytic leukemia																									
Monocytic leukemia																									
Megakaryocytic leukemia																									
Cranial cavity																									
Osteoma																									
Sacral region																									
Hemangiopericytoma, NOS																									
Scrotum, NOS																									
Mesothelioma, invasive																									

**TABLE A2. INDIVIDUAL ANIMAL TUMOR PATHOLOGY OF MALE RATS: 1% TREMOLITE
(Continued)**

ANIMAL NUMBER	0	0	0	0	0	0	0	0	0	0	0	0	0	0	0	0	0	0	0	1	1	1	1	1	1	1	1	1	1
	8	8	8	8	8	8	8	8	9	9	9	9	9	9	9	9	9	9	9	0	0	0	0	0	0	0	0	0	0
WEEKS ON STUDY	1	1	1	1	1	1	1	1	1	0	1	1	0	1	1	0	1	1	0	1	1	0	1	1	1	1	1	1	1
	4	3	3	4	2	4	2	3	3	4	9	3	3	8	2	0	4	1	0	9	1	0	9	1	0	3	2	3	3
	6	8	6	6	9	1	9	3	9	6	0	4	7	4	2	3	8	8	9	6	1	3	3	3	8	4			
REPRODUCTIVE SYSTEM																													
Mammary gland	+																												
Adenoma, NOS	+																												
Adenocarcinoma, NOS	+																												
Papillary adenocarcinoma	+																												
Fibroadenoma	+																												
Testis	X	X	X	X	X	X	X	X	X	X	X	X	X	X	X	X	X	X	X	X	X	X	X	X	X	X	X	X	X
Interstitial cell tumor	+	+	+	+	+	+	+	+	+	+	+	+	+	+	+	+	+	+	+	+	+	+	+	+	+	+	+	+	+
Prostate	X	X	X	X	X	X	X	X	X	X	X	X	X	X	X	X	X	X	X	X	X	X	X	X	X	X	X	X	X
Penis	+	+	+	+	+	+	+	+	+	+	+	+	+	+	+	+	+	+	+	+	+	+	+	+	+	+	+	+	+
Keratoacanthoma	N	N	N	N	N	N	N	N	N	N	N	N	N	N	N	N	N	N	N	N	N	N	N	N	N	N	N	N	N
Preputial/clitoral gland	X	X	X	X	X	X	X	X	X	X	X	X	X	X	X	X	X	X	X	X	X	X	X	X	X	X	X	X	X
Squamous cell carcinoma	N	N	N	N	N	N	N	N	N	N	N	N	N	N	N	N	N	N	N	N	N	N	N	N	N	N	N	N	N
Epididymis	N	N	N	N	N	N	N	N	N	N	N	N	N	N	N	N	N	N	N	N	N	N	N	N	N	N	N	N	N
Lipoma																													
Mesothelioma, invasive																													
NERVOUS SYSTEM																													
Brain	+																												
Carcinoma, NOS, invasive	+																												
Astrocytoma																													
Spinal cord	N	N	N	N	N	N	N	N	N	N	N	N	N	N	N	N	N	N	N	N	N	N	N	N	N	N	N	N	N
Astrocytoma																													
SPECIAL SENSE ORGANS																													
Zymbal gland	+																												
Squamous cell carcinoma	+																												
Keratoacanthoma	+																												
MUSCULOSKELETAL SYSTEM																													
Bone	N																												
Squamous cell carcinoma, invasive	N																												
Fibrosarcoma, invasive	N																												
Liposarcoma, invasive	N																												
Osteosarcoma	N																												
BODY CAVITIES																													
Mediastinum	N																												
Fibrosarcoma, invasive	N																												
Peritoneum	N																												
Fibrosarcoma	N																												
Liposarcoma	N																												
Tunica vaginalis	+	+	+	+	+	+	+	+	+	+	+	+	+	+	+	+	+	+	+	+	+	+	+	+	+	+	+	+	+
Mesothelioma, malignant	N	N	N	N	N	N	N	N	N	N	N	N	N	N	N	N	N	N	N	N	N	N	N	N	N	N	N	N	N
Mesentery	N																												
Pheochromocytoma, metastatic	N																												
Sarcoma, NOS	N																												
Fibrosarcoma	N																												
Hemangiosarcoma	N																												
ALL OTHER SYSTEMS																													
Multiple organs, NOS	N																												
Carcinoma, NOS, invasive	N																												
Squamous cell carcinoma, invasive	N																												
Transitional cell carcinoma, metastatic	N																												
Sarcoma, NOS, invasive	N																												
Fibrosarcoma, invasive	N																												
Fibrous histiocytoma, malignant	N																												
Mesothelioma, invasive	N																												
Mesothelioma, metastatic	N																												
Malignant lymphoma, histiocytic type	N																												
Myelomonocytic leukemia	N																												
Monocytic leukemia	X	X	X	X	X	X	X	X	X	X	X	X	X	X	X	X	X	X	X	X	X	X	X	X	X	X	X	X	
Megakaryocytic leukemia																													
Cranial cavity	N																												
Osteoma	N																												
Sacral region	N																												
Hemangioepithelioma, NOS	N																												
Scrotum, NOS	N																												
Mesothelioma, invasive	N																												

TABLE A2. INDIVIDUAL ANIMAL TUMOR PATHOLOGY OF MALE RATS: 1% TREMOLITE
(Continued)

ANIMAL NUMBER	1	1	1	1	1	1	1	1	1	1	1	1	1	1	1	1	1	1	2	2	2	2	2	2	2	2	
WEEKS ON STUDY	8	8	8	8	8	8	8	8	9	9	9	9	9	9	9	9	9	9	0	0	0	0	0	0	0	0	
	2	3	4	5	6	7	8	9	0	1	2	3	4	5	6	7	8	9	0	1	2	3	4	5	6		
REPRODUCTIVE SYSTEM																											
Mammary gland	+	+	+	+	+	+	N	+	+	N	+	+	N	+	N	+	+	+	+	+	+	+	N	+	+	N	
Adenoma, NOS																											
Adenocarcinoma, NOS																											
Papillary adenocarcinoma																											
Fibroadenoma																											
Testis	+	+	+	+	+	+	+	+	+	+	+	+	+	+	+	+	+	+	+	+	+	+	+	+	+	+	
Interstitial cell tumor	X	X	X	X	X	X	X	X	X	X	X	X	X	X	X	X	X	X	X	X	X	X	X	X	X	X	
Prostate	+	+	+	+	+	+	+	+	+	+	+	+	+	+	+	+	+	+	+	+	+	+	+	+	+	+	
Penis	N	N	N	N	N	N	N	N	N	N	N	N	N	N	N	N	N	N	N	N	N	N	N	N	N	N	
Keratoacanthoma																											
Preputial/clitoral gland	N	N	N	N	N	N	N	N	N	N	N	N	N	N	N	N	N	N	N	N	N	N	N	N	N	N	
Squamous cell carcinoma																											
Epididymis	N	N	N	N	N	N	N	N	N	N	N	N	N	N	N	N	N	N	N	N	N	N	N	N	N	N	
Lipoma																											
Mesothelioma, invasive																											
NERVOUS SYSTEM																											
Brain	+	+	+	+	+	+	+	+	+	+	+	+	+	+	+	+	+	+	+	+	+	+	+	+	+	+	
Carcinoma, NOS, invasive																											
Astrocytoma																											
Spinal cord	N	N	N	N	N	N	N	N	N	N	N	N	N	N	N	N	N	N	N	N	N	N	N	N	N	N	
Astrocytoma																											
SPECIAL SENSE ORGANS																											
Zymbal gland	+	+	+	+	+	+	N	+	+	+	+	+	+	+	+	+	+	+	+	+	+	+	+	N	+	+	+
Squamous cell carcinoma																											
Keratoacanthoma																											
MUSCULOSKELETAL SYSTEM																											
Bone	N	N	N	N	N	N	N	N	N	N	N	N	N	N	N	N	N	N	N	N	N	N	N	N	N	N	
Squamous cell carcinoma, invasive																											
Fibrosarcoma, invasive																											
Liposarcoma, invasive																											
Osteosarcoma																											
BODY CAVITIES																											
Mediastinum	N	N	N	N	N	N	N	N	N	N	N	N	N	N	N	N	N	N	N	N	N	N	N	N	N	N	
Fibrosarcoma, invasive																											
Peritoneum	N	N	N	N	N	N	N	N	N	N	N	N	N	N	N	N	N	N	N	N	N	N	N	N	N	N	
Fibrosarcoma																											
Liposarcoma																											
Tunica vaginalis	+	+	+	+	+	+	+	+	+	+	+	+	+	+	+	+	+	+	+	+	+	+	+	+	+	+	
Mesothelioma, malignant										X	X																
Mesentery	N	N	N	N	N	N	N	N	N	N	N	N	N	N	N	N	N	N	N	N	N	N	N	N	N	N	
Pheochromocytoma, metastatic																											
Sarcoma, NOS																											
Fibrosarcoma																											
Hemangiosarcoma																										X	
ALL OTHER SYSTEMS																											
Multiple organs, NOS	N	N	N	N	N	N	N	N	N	N	N	N	N	N	N	N	N	N	N	N	N	N	N	N	N	N	
Carcinoma, NOS, invasive																											
Squamous cell carcinoma, invasive																											
Transitional cell carcinoma, metastatic																											
Sarcoma, NOS, invasive																											
Fibrosarcoma, invasive																											
Fibrous histiocytoma, malignant																											
Mesothelioma, invasive											X																
Mesothelioma, metastatic																											
Malignant lymphoma, histiocytic type																											
Myelomonocytic leukemia																											
Monocytic leukemia																											
Megakaryocytic leukemia	X	X		X	X	X																					
Cranial cavity																											
Osteoma																											
Sacral region																											
Hemangiopericytoma, NOS																											
Scrotum, NOS																											
Mesothelioma, invasive																											

**TABLE A2. INDIVIDUAL ANIMAL TUMOR PATHOLOGY OF MALE RATS: 1% TREMOLITE
(Continued)**

ANIMAL NUMBER	207	208	209	210	211	212	213	214	215	216	217	218	219	220	221	222	223	224	225	226	227	228	229	230	231	232	233	234	235	236	237	238	239	240		
WEEKS ON STUDY	13	18	25	32	40	48	56	64	72	80	88	96	104	112	120	128	136	144	152	160	168	176	184	192	200	208	216	224	232	240	248	256	264	272		
REPRODUCTIVE SYSTEM																																				
Mammary gland	N	+	+	+	+	+	+	+	N	+	+	+	+	+	+	+	+	+	+	+	+	+	+	+	+	+	+	+	+	+	+	+	+	+		
Adenoma, NOS																																				
Adenocarcinoma, NOS																																				
Papillary adenocarcinoma																																				
Fibroadenoma																																				
Testis	+	+	+	+	+	+	+	+	+	+	+	+	+	+	+	+	+	+	+	+	+	+	+	+	+	+	+	+	+	+	+	+	+	+	+	
Interstitial cell tumor	X	X	X	X	X	X	X	X	X	X	X	X	X	X	X	X	X	X	X	X	X	X	X	X	X	X	X	X	X	X	X	X	X	X	X	
Prostate	+	+	+	+	+	+	+	+	+	+	+	+	+	+	+	+	+	+	+	+	+	+	+	+	+	+	+	+	+	+	+	+	+	+	+	
Penis	N	N	N	N	N	N	N	N	N	N	N	N	N	N	N	N	N	N	N	N	N	N	N	N	N	N	N	N	N	N	N	N	N	N	N	
Keratoacanthoma																																				
Preputial/clitoral gland	N	N	N	N	N	N	N	N	N	N	N	N	N	N	N	N	N	N	N	N	N	N	N	N	N	N	N	N	N	N	N	N	N	N	N	
Squamous cell carcinoma																																				
Epididymis	N	N	N	N	N	N	N	N	N	N	N	N	N	N	N	N	N	N	N	N	N	N	N	N	N	N	N	N	N	N	N	N	N	N	N	
Lipoma																																				
Mesothelioma, invasive																																				
NERVOUS SYSTEM																																				
Brain	+	+	+	+	+	+	+	+	+	+	+	+	+	+	+	+	+	+	+	+	+	+	+	+	+	+	+	+	+	+	+	+	+	+	+	
Carcinoma, NOS, invasive																																				
Astrocytoma																																				
Spinal cord	N	N	N	N	N	N	N	N	N	N	N	N	N	N	N	N	N	N	N	N	N	N	N	N	N	N	N	N	N	N	N	N	N	N	N	
Astrocytoma																																				
SPECIAL SENSE ORGANS																																				
Zymbal gland	+	N	+	+	+	+	+	+	+	+	+	+	+	+	+	+	+	+	+	+	+	+	+	+	+	+	+	+	+	+	+	+	+	+	+	
Squamous cell carcinoma																																				
Keratoacanthoma																																				
MUSCULOSKELETAL SYSTEM																																				
Bone	N	N	N	N	N	N	N	N	N	N	N	N	N	N	N	N	N	N	N	N	N	N	N	N	N	N	N	N	N	N	N	N	N	N	N	
Squamous cell carcinoma, invasive																																				
Fibrosarcoma, invasive																																				
Liposarcoma, invasive																																				
Osteosarcoma	X																																			
BODY CAVITIES																																				
Mediastinum	N	N	N	N	N	N	N	N	N	N	N	N	N	N	N	N	N	N	N	N	N	N	N	N	N	N	N	N	N	N	N	N	N	N	N	
Fibrosarcoma, invasive																																				
Peritoneum	N	N	N	N	N	N	N	N	N	N	N	N	N	N	N	N	N	N	N	N	N	N	N	N	N	N	N	N	N	N	N	N	N	N	N	
Fibrosarcoma																																				
Liposarcoma																																				
Tunica vaginalis	+	+	+	+	+	+	+	+	+	+	+	+	+	+	+	+	+	+	+	+	+	+	+	+	+	+	+	+	+	+	+	+	+	+	+	
Mesothelioma, malignant	N	N	N	N	N	N	N	N	N	N	N	N	N	N	N	N	N	N	N	N	N	N	N	N	N	N	N	N	N	N	N	N	N	N	N	
Mesentery																																				
Pheochromocytoma, metastatic																																				
Sarcoma, NOS																																				
Fibrosarcoma																																				
Hemangiosarcoma																																				
ALL OTHER SYSTEMS																																				
Multiple organs, NOS	N	N	N	N	N	N	N	N	N	N	N	N	N	N	N	N	N	N	N	N	N	N	N	N	N	N	N	N	N	N	N	N	N	N	N	
Carcinoma, NOS, invasive																																				
Squamous cell carcinoma, invasive																																				
Transitional cell carcinoma, metastatic																																				
Sarcoma, NOS, invasive																																				
Fibrosarcoma, invasive																																				
Fibrous histiocytoma, malignant																																				
Mesothelioma, invasive																																				
Mesothelioma, metastatic																																				
Malignant lymphoma, histiocytic type																																				
Myelomonocytic leukemia																																				
Monocytic leukemia																																				
Megakaryocytic leukemia																																				
Cranial cavity																																				
Osteoma																																				
Sacral region																																				
Hemangiosarcoma, NOS																																				
Scrotum, NOS																																				
Mesothelioma, invasive																																				

TABLE A3. ANALYSIS OF PRIMARY TUMORS IN MALE RATS IN THE LIFETIME FEED STUDY OF TREMOLITE

	Untreated Control	1% Tremolite
Skin: Keratoacanthoma		
Overall Rates (a)	6/118 (5%)	13/250 (5%)
Adjusted Rates (b)	44.4%	23.6%
Terminal Rates (c)	1/5 (20%)	5/35 (14%)
Week of First Observation	114	118
Life Table Test (d)		P=0.221N
Incidental Tumor Test (d)		P=0.565N
Fisher Exact Test (d)		P=0.591
Skin: Basal Cell Carcinoma		
Overall Rates (a)	4/118 (3%)	8/250 (3%)
Adjusted Rates (b)	18.8%	11.5%
Terminal Rates (c)	0/5 (0%)	0/35 (0%)
Week of First Observation	121	116
Life Table Tests (d)		P=0.416N
Incidental Tumor Tests (d)		P=0.541N
Fisher Exact Test (d)		P=0.572N
Skin: Basal Cell Tumor or Carcinoma		
Overall Rates (a)	6/118 (5%)	9/250 (4%)
Adjusted Rates (b)	36.8%	12.1%
Terminal Rates (c)	1/5 (20%)	0/35 (0%)
Week of First Observation	121	116
Life Table Tests (d)		P=0.171N
Incidental Tumor Tests (d)		P=0.296N
Fisher Exact Test (d)		P=0.339N
Skin: Basal Cell Tumor, Basal Cell Carcinoma, or Trichoepithelioma		
Overall Rates (a)	6/118 (5%)	10/250 (4%)
Adjusted Rates (b)	36.8%	12.6%
Terminal Rates (c)	1/5 (20%)	0/35 (0%)
Week of First Observation	121	115
Life Table Tests (d)		P=0.230N
Incidental Tumor Tests (d)		P=0.359N
Fisher Exact Test (d)		P=0.409N
Skin: Squamous Cell Papilloma		
Overall Rates (a)	3/118 (3%)	9/250 (4%)
Adjusted Rates (b)	6.0%	13.6%
Terminal Rates (c)	0/5 (0%)	3/35 (9%)
Week of First Observation	114	109
Life Table Test (d)		P=0.607
Incidental Tumor Test (d)		P=0.421
Fisher Exact Test (d)		P=0.428
Skin: Squamous Cell Papilloma or Carcinoma		
Overall Rates (a)	5/118 (4%)	13/250 (5%)
Adjusted Rates (b)	8.3%	17.9%
Terminal Rates (c)	0/5 (0%)	4/35 (11%)
Week of First Observation	105	98
Life Table Test (d)		P=0.567N
Incidental Tumor Test (d)		P=0.447
Fisher Exact Test (d)		P=0.456
Integumentary System: Fibroma		
Overall Rates (a)	14/118 (12%)	36/250 (14%)
Adjusted Rates (b)	36.1%	38.2%
Terminal Rates (c)	0/5 (0%)	6/35 (17%)
Week of First Observation	112	87
Life Table Tests (d)		P=0.507N
Incidental Tumor Tests (d)		P=0.325
Fisher Exact Test (d)		P=0.313

TABLE A3. ANALYSIS OF PRIMARY TUMORS IN MALE RATS IN THE LIFETIME FEED STUDY OF TREMOLITE (Continued)

	Untreated Control	1% Tremolite
Integumentary System: Neurofibroma		
Overall Rates (a)	2/118 (2%)	6/250 (2%)
Adjusted Rates (b)	3.9%	5.6%
Terminal Rates (c)	0/5 (0%)	0/35 (0%)
Week of First Observation	111	121
Life Table Tests (d)		P=0.534
Incidental Tumor Tests (d)		P=0.503
Fisher Exact Test (d)		P=0.499
Integumentary System: Fibroma or Neurofibroma		
Overall Rates (a)	15/118 (13%)	41/250 (16%)
Adjusted Rates (b)	36.8%	41.1%
Terminal Rates (c)	0/5 (0%)	6/35 (17%)
Week of First Observation	111	87
Life Table Tests (d)		P=0.521
Incidental Tumor Tests (d)		P=0.240
Fisher Exact Test (d)		P=0.224
Integumentary System: Fibrosarcoma		
Overall Rates (a)	3/118 (3%)	12/250 (5%)
Adjusted Rates (b)	5.8%	17.4%
Terminal Rates (c)	0/5 (0%)	3/35 (9%)
Week of First Observation	85	85
Life Table Tests (d)		P=0.407
Incidental Tumor Tests (d)		P=0.246
Fisher Exact Test (d)		P=0.235
Integumentary System: Sarcoma, Fibrosarcoma, Neurofibrosarcoma, or Myxosarcoma		
Overall Rates (a)	5/118 (4%)	17/250 (7%)
Adjusted Rates (b)	18.3%	27.4%
Terminal Rates (c)	0/5 (0%)	5/35 (14%)
Week of First Observation	85	85
Life Table Tests (d)		P=0.553
Incidental Tumor Tests (d)		P=0.247
Fisher Exact Test (d)		P=0.236
Integumentary System: Neurofibroma or Neurofibrosarcoma		
Overall Rates (a)	2/118 (2%)	7/250 (3%)
Adjusted Rates (b)	3.9%	6.2%
Terminal Rates (c)	0/5 (0%)	0/35 (0%)
Week of First Observation	111	116
Life Table Tests (d)		P=0.442
Incidental Tumor Tests (d)		P=0.421
Fisher Exact Test (d)		P=0.407
Integumentary System: Fibroma or Fibrosarcoma		
Overall Rates (a)	17/118 (14%)	47/250 (19%)
Adjusted Rates (b)	39.9%	49.6%
Terminal Rates (c)	0/5 (0%)	9/35 (26%)
Week of First Observation	85	85
Life Table Tests (d)		P=0.542
Incidental Tumor Tests (d)		P=0.203
Fisher Exact Test (d)		P=0.187
Integumentary System: Fibroma, Neurofibroma, Sarcoma, Fibrosarcoma, Neurofibrosarcoma, or Myxosarcoma		
Overall Rates (a)	20/118 (17%)	57/250 (23%)
Adjusted Rates (b)	49.5%	57.3%
Terminal Rates (c)	0/5 (0%)	11/35 (31%)
Week of First Observation	85	85
Life Table Tests (d)		P=0.507
Incidental Tumor Tests (d)		P=0.142
Fisher Exact Test (d)		P=0.124

TABLE A3. ANALYSIS OF PRIMARY TUMORS IN MALE RATS IN THE LIFETIME FEED STUDY OF TREMOLITE (Continued)

	Untreated Control	1% Tremolite
Integumentary System or Salivary Gland: Sarcoma, Fibrosarcoma, Neurofibrosarcoma, or Myxosarcoma		
Overall Rates (a)	6/118 (5%)	20/250 (8%)
Adjusted Rates (b)	20.3%	30.9%
Terminal Rates (c)	0/5 (0%)	7/35 (20%)
Week of First Observation	85	85
Life Table Tests (d)		P=0.540
Incidental Tumor Tests (d)		P=0.236
Fisher Exact Test (d)		P=0.214
Integumentary System or Salivary Gland: Fibroma, Neurofibroma, Sarcoma, Fibrosarcoma, Neurofibrosarcoma, or Myxosarcoma		
Overall Rates (a)	21/118 (18%)	59/250 (24%)
Adjusted Rates (b)	50.7%	60.8%
Terminal Rates (c)	0/5 (0%)	13/35 (37%)
Week of First Observation	85	85
Life Table Tests (d)		P=0.551N
Incidental Tumor Tests (d)		P=0.149
Fisher Exact Test (d)		P=0.130
Lung: Alveolar/Bronchiolar Adenoma or Carcinoma		
Overall Rates (e)	3/118 (3%)	2/250 (1%)
Adjusted Rates (b)	9.1%	3.9%
Terminal Rates (c)	0/5 (0%)	1/35 (3%)
Week of First Observation	127	132
Life Table Test (d)		P=0.109N
Incidental Tumor Test (d)		P=0.179N
Fisher Exact Test (d)		P=0.190N
Hematopoietic System: Leukemia		
Overall Rates (a)	43/118 (36%)	102/250 (41%)
Adjusted Rates (b)	100.0%	75.0%
Terminal Rates (c)	5/5 (100%)	16/35 (46%)
Week of First Observation	105	84
Life Table Test (d)		P=0.289N
Incidental Tumor Test (d)		P=0.257
Fisher Exact Test (d)		P=0.247
Hematopoietic System: Lymphoma		
Overall Rates (a)	5/118 (4%)	1/250 (<1%)
Adjusted Rates (b)	9.2%	0.5%
Terminal Rates (c)	0/5 (0%)	0/35 (0%)
Week of First Observation	76	107
Life Table Test (d)		P=0.009N
Incidental Tumor Test (d)		P=0.019N
Fisher Exact Test (d)		P=0.014N
Circulatory System: Hemangiosarcoma		
Overall Rates (a)	2/118 (2%)	8/250 (3%)
Adjusted Rates (b)	9.5%	10.2%
Terminal Rates (c)	0/5 (0%)	2/35 (6%)
Week of First Observation	132	90
Life Table Test (d)		P=0.465
Incidental Tumor Test (d)		P=0.287
Fisher Exact Test (d)		P=0.327
Circulatory System: Hemangioma or Hemangiosarcoma		
Overall Rates (a)	3/118 (3%)	8/250 (3%)
Adjusted Rates (b)	18.5%	10.2%
Terminal Rates (c)	0/5 (0%)	2/35 (6%)
Week of First Observation	132	90
Life Table Test (d)		P=0.586N
Incidental Tumor Test (d)		P=0.465
Fisher Exact Test (d)		P=0.508

TABLE A3. ANALYSIS OF PRIMARY TUMORS IN MALE RATS IN THE LIFETIME FEED STUDY OF TREMOLITE (Continued)

	Untreated Control	1% Tremolite
Liver: Neoplastic Nodule		
Overall Rates (e)	10/118 (8%)	8/250 (3%)
Adjusted Rates (b)	28.4%	9.4%
Terminal Rates (c)	0/5 (0%)	1/35 (3%)
Week of First Observation	105	113
Life Table Test (d)		P = 0.009N
Incidental Tumor Test (d)		P = 0.018N
Fisher Exact Test (d)		P = 0.030N
Liver: Hepatocellular Carcinoma		
Overall Rates (e)	6/118 (5%)	6/250 (2%)
Adjusted Rates (b)	27.0%	9.3%
Terminal Rates (c)	0/5 (0%)	2/35 (6%)
Week of First Observation	127	122
Life Table Test (d)		P = 0.048N
Incidental Tumor Test (d)		P = 0.126N
Fisher Exact Test (d)		P = 0.150N
Liver: Neoplastic Nodule or Hepatocellular Carcinoma		
Overall Rates (e)	16/118 (14%)	14/250 (6%)
Adjusted Rates (b)	48.0%	18.0%
Terminal Rates (c)	0/5 (0%)	3/35 (9%)
Week of First Observation	105	113
Life Table Test (d)		P < 0.001N
Incidental Tumor Test (d)		P = 0.004N
Fisher Exact Test (d)		P = 0.010N
Pancreas: Acinar Cell Adenoma		
Overall Rates (e)	10/118 (8%)	22/250 (9%)
Adjusted Rates (b)	50.8%	35.5%
Terminal Rates (c)	1/5 (20%)	7/35 (20%)
Week of First Observation	120	111
Life Table Tests (d)		P = 0.199N
Incidental Tumor Tests (d)		P = 0.578N
Fisher Exact Test (d)		P = 0.545
Pancreas: Acinar Cell Adenoma or Carcinoma		
Overall Rates (e)	10/118 (8%)	(f) 24/250 (10%)
Adjusted Rates (b)	50.8%	36.2%
Terminal Rates (c)	1/5 (20%)	7/35 (20%)
Week of First Observation	120	105
Life Table Tests (d)		P = 0.292N
Incidental Tumor Tests (d)		P = 0.459
Fisher Exact Test (d)		P = 0.446
Pancreas: Benign Mixed Tumor		
Overall Rates (e)	3/118 (3%)	3/250 (1%)
Adjusted Rates (b)	27.3%	7.0%
Terminal Rates (c)	1/5 (20%)	2/35 (6%)
Week of First Observation	130	137
Life Table Test (d)		P = 0.085N
Incidental Tumor Test (d)		P = 0.287N
Fisher Exact Test (d)		P = 0.294N
Stomach: Squamous Cell Papilloma or Carcinoma		
Overall Rates (e)	3/118 (3%)	2/250 (1%)
Adjusted Rates (b)	21.2%	3.3%
Terminal Rates (c)	0/5 (0%)	1/35 (3%)
Week of First Observation	125	109
Life Table Test (d)		P = 0.067N
Incidental Tumor Test (d)		P = 0.195N
Fisher Exact Test (d)		P = 0.190N

TABLE A3. ANALYSIS OF PRIMARY TUMORS IN MALE RATS IN THE LIFETIME FEED STUDY OF TREMOLITE (Continued)

	Untreated Control	1% Tremolite
Kidney: Tubular Cell Adenocarcinoma		
Overall Rates (e)	1/118 (1%)	5/250 (2%)
Adjusted Rates (b)	1.9%	5.8%
Terminal Rates (c)	0/5 (0%)	0/35 (0%)
Week of First Observation	127	131
Life Table Test (d)		P=0.417
Incidental Tumor Test (d)		P=0.369
Fisher Exact Test (d)		P=0.375
Kidney: Tubular Cell Adenoma or Adenocarcinoma		
Overall Rates (e)	1/118 (1%)	6/250 (2%)
Adjusted Rates (b)	1.9%	8.5%
Terminal Rates (c)	0/5 (0%)	1/35 (3%)
Week of First Observation	127	131
Life Table Test (d)		P=0.379
Incidental Tumor Test (d)		P=0.285
Fisher Exact Test (d)		P=0.285
Pituitary Gland: Adenoma		
Overall Rates (e)	20/118 (17%)	37/247 (15%)
Adjusted Rates (b)	44.1%	36.7%
Terminal Rates (c)	0/5 (0%)	5/35 (14%)
Week of First Observation	105	97
Life Table Test (d)		P=0.150N
Incidental Tumor Test (d)		P=0.351N
Fisher Exact Test (d)		P=0.366N
Pituitary Gland: Adenoma or Carcinoma		
Overall Rates (e)	22/118 (19%)	41/247 (17%)
Adjusted Rates (b)	47.9%	39.4%
Terminal Rates (c)	0/5 (0%)	5/35 (14%)
Week of First Observation	105	97
Life Table Test (d)		P=0.147N
Incidental Tumor Test (d)		P=0.345N
Fisher Exact Test (d)		P=0.365N
Adrenal Medulla: Pheochromocytoma		
Overall Rates (e)	38/118 (32%)	62/250 (25%)
Adjusted Rates (b)	91.0%	68.3%
Terminal Rates (c)	3/5 (60%)	17/35 (49%)
Week of First Observation	104	103
Life Table Test (d)		P=0.002N
Incidental Tumor Test (d)		P=0.082N
Fisher Exact Test (d)		P=0.087N
Adrenal Medulla: Malignant Pheochromocytoma		
Overall Rates (e)	3/118 (3%)	7/250 (3%)
Adjusted Rates (b)	23.8%	10.4%
Terminal Rates (c)	1/5 (20%)	2/35 (6%)
Week of First Observation	130	113
Life Table Test (d)		P=0.482N
Incidental Tumor Test (d)		P=0.627
Fisher Exact Test (d)		P=0.594
Adrenal Medulla: Pheochromocytoma or Malignant Pheochromocytoma		
Overall Rates (e)	41/118 (35%)	68/250 (27%)
Adjusted Rates (b)	95.7%	72.9%
Terminal Rates (c)	4/5 (80%)	19/35 (54%)
Week of First Observation	104	103
Life Table Test (d)		P=0.001N
Incidental Tumor Test (d)		P=0.075N
Fisher Exact Test (d)		P=0.088N

TABLE A3. ANALYSIS OF PRIMARY TUMORS IN MALE RATS IN THE LIFETIME FEED STUDY OF TREMOLITE (Continued)

	Untreated Control	1% Tremolite
Thyroid Gland: Follicular Cell Adenoma		
Overall Rates (e)	5/117 (4%)	12/247 (5%)
Adjusted Rates (b)	8.8%	18.4%
Terminal Rates (c)	0/5 (0%)	4/35 (11%)
Week of First Observation	105	111
Life Table Test (d)		P=0.501N
Incidental Tumor Test (d)		P=0.474
Fisher Exact Test (d)		P=0.519
Thyroid Gland: Follicular Cell Carcinoma		
Overall Rates (e)	6/117 (5%)	13/247 (5%)
Adjusted Rates (b)	24.7%	18.4%
Terminal Rates (c)	0/5 (0%)	2/35 (6%)
Week of First Observation	128	104
Life Table Test (d)		P=0.391N
Incidental Tumor Test (d)		P=0.599
Fisher Exact Test (d)		P=0.589
Thyroid Gland: Follicular Cell Adenoma or Carcinoma		
Overall Rates (e)	11/117 (9%)	25/247 (10%)
Adjusted Rates (b)	31.4%	34.1%
Terminal Rates (c)	0/5 (0%)	6/35 (17%)
Week of First Observation	105	104
Life Table Test (d)		P=0.346N
Incidental Tumor Test (d)		P=0.479
Fisher Exact Test (d)		P=0.497
Thyroid Gland: C-Cell Adenoma		
Overall Rates (e)	11/117 (9%)	22/247 (9%)
Adjusted Rates (b)	35.9%	17.8%
Terminal Rates (c)	1/5 (20%)	0/35 (0%)
Week of First Observation	108	97
Life Table Test (d)		P=0.386N
Incidental Tumor Test (d)		P=0.572N
Fisher Exact Test (d)		P=0.509N
Thyroid Gland: C-Cell Carcinoma		
Overall Rates (e)	16/117 (14%)	48/247 (19%)
Adjusted Rates (b)	62.4%	53.0%
Terminal Rates (c)	2/5 (40%)	9/35 (26%)
Week of First Observation	91	85
Life Table Test (d)		P=0.505
Incidental Tumor Test (d)		P=0.130
Fisher Exact Test (d)		P=0.114
Thyroid Gland: C-Cell Adenoma or Carcinoma		
Overall Rates (e)	27/117 (23%)	70/247 (28%)
Adjusted Rates (b)	79.9%	61.5%
Terminal Rates (c)	3/5 (60%)	9/35 (26%)
Week of First Observation	91	85
Life Table Test (d)		P=0.473N
Incidental Tumor Test (d)		P=0.170
Fisher Exact Test (d)		P=0.175
Pancreatic Islets: Islet Cell Adenoma		
Overall Rates (e)	5/118 (4%)	12/250 (5%)
Adjusted Rates (b)	31.8%	11.4%
Terminal Rates (c)	1/5 (20%)	1/35 (3%)
Week of First Observation	129	103
Life Table Test (d)		P=0.529N
Incidental Tumor Test (d)		P=0.494
Fisher Exact Test (d)		P=0.522

TABLE A3. ANALYSIS OF PRIMARY TUMORS IN MALE RATS IN THE LIFETIME FEED STUDY OF TREMOLITE (Continued)

	Untreated Control	1% Tremolite
Pancreatic Islets: Islet Cell Carcinoma		
Overall Rates (e)	7/118 (6%)	11/250 (4%)
Adjusted Rates (b)	19.5%	16.1%
Terminal Rates (c)	0/5 (0%)	3/35 (9%)
Week of First Observation	120	108
Life Table Test (d)		P = 0.173N
Incidental Tumor Test (d)		P = 0.320N
Fisher Exact Test (d)		P = 0.345N
Pancreatic Islets: Islet Cell Adenoma or Carcinoma		
Overall Rates (e)	11/118 (9%)	22/250 (9%)
Adjusted Rates (b)	43.2%	25.3%
Terminal Rates (c)	1/5 (20%)	4/35 (11%)
Week of First Observation	120	103
Life Table Test (d)		P = 0.250N
Incidental Tumor Test (d)		P = 0.502N
Fisher Exact Test (d)		P = 0.505N
Mammary Gland: Fibroadenoma		
Overall Rates (a)	17/118 (14%)	32/250 (13%)
Adjusted Rates (b)	59.4%	49.6%
Terminal Rates (c)	1/5 (20%)	12/35 (34%)
Week of First Observation	112	110
Life Table Tests (d)		P = 0.041N
Incidental Tumor Tests (d)		P = 0.347N
Fisher Exact Test (d)		P = 0.393N
Preputial Gland: Squamous Cell Carcinoma		
Overall Rates (e)	6/118 (5%)	14/250 (6%)
Adjusted Rates (b)	13.2%	19.2%
Terminal Rates (c)	0/5 (0%)	3/35 (9%)
Week of First Observation	110	103
Life Table Tests (d)		P = 0.456N
Incidental Tumor Tests (d)		P = 0.507
Fisher Exact Test (d)		P = 0.528
Preputial Gland: Carcinoma or Squamous Cell Carcinoma		
Overall Rates (e)	7/118 (6%)	14/250 (6%)
Adjusted Rates (b)	14.0%	19.2%
Terminal Rates (c)	0/5 (0%)	3/35 (9%)
Week of First Observation	85	103
Life Table Tests (d)		P = 0.328N
Incidental Tumor Tests (d)		P = 0.553N
Fisher Exact Test (d)		P = 0.534N
Testis: Interstitial Cell Tumor		
Overall Rates (e)	114/118 (97%)	237/250 (95%)
Adjusted Rates (b)	100.0%	100.0%
Terminal Rates (c)	5/5 (100%)	35/35 (100%)
Week of First Observation	76	76
Life Table Test (d)		P = 0.022N
Incidental Tumor Test (d)		P = 0.590N
Fisher Exact Test (d)		P = 0.315N
Brain: Astrocytoma		
Overall Rates (e)	7/118 (6%)	6/250 (2%)
Adjusted Rates (b)	30.3%	4.9%
Terminal Rates (c)	1/5 (20%)	0/35 (0%)
Week of First Observation	61	48
Life Table Tests (d)		P = 0.047N
Incidental Tumor Tests (d)		P = 0.066N
Fisher Exact Test (d)		P = 0.082N

TABLE A3. ANALYSIS OF PRIMARY TUMORS IN MALE RATS IN THE LIFETIME FEED STUDY OF TREMOLITE (Continued)

	Untreated Control	1% Tremolite
Brain: Glioma or Astrocytoma		
Overall Rates (e)	8/118 (7%)	6/250 (2%)
Adjusted Rates (b)	31.0%	4.9%
Terminal Rates (c)	1/5 (20%)	0/35 (0%)
Week of First Observation	61	48
Life Table Tests (d)		P=0.022N
Incidental Tumor Tests (d)		P=0.035N
Fisher Exact Test (d)		P=0.043N
All Sites: Malignant Mesothelioma		
Overall Rates (a)	10/118 (8%)	8/250 (3%)
Adjusted Rates (b)	18.0%	7.0%
Terminal Rates (c)	0/5 (0%)	1/35 (3%)
Week of First Observation	92	94
Life Table Test (d)		P=0.017N
Incidental Tumor Test (d)		P=0.046N
Fisher Exact Test (d)		P=0.030N
All Sites: Benign Tumors		
Overall Rates (a)	115/118 (97%)	238/250 (95%)
Adjusted Rates (b)	100.0%	100.0%
Terminal Rates (c)	5/5 (100%)	35/35 (100%)
Week of First Observation	76	76
Life Table Test (d)		P=0.021N
Incidental Tumor Test (d)		P=0.528N
Fisher Exact Test (d)		P=0.235N
All Sites: Malignant Tumors		
Overall Rates (a)	96/118 (81%)	199/250 (80%)
Adjusted Rates (b)	100.0%	96.5%
Terminal Rates (c)	5/5 (100%)	29/35 (83%)
Week of First Observation	61	48
Life Table Test (d)		P=0.032N
Incidental Tumor Test (d)		P=0.428N
Fisher Exact Test (d)		P=0.403N
All Sites: All Tumors		
Overall Rates (a)	117/118 (99%)	241/250 (96%)
Adjusted Rates (b)	100.0%	100.0%
Terminal Rates (c)	5/5 (100%)	35/35 (100%)
Week of First Observation	61	48
Life Table Test (d)		P=0.019N
Incidental Tumor Test (d)		P=0.351N
Fisher Exact Test (d)		P=0.116N

(a) Number of tumor-bearing animals/number of animals examined grossly at the site

(b) Kaplan-Meier estimated tumor incidences at the end of the study after adjusting for intercurrent mortality

(c) Observed tumor incidence in animals killed at the end of the study

(d) Beneath the dosed group incidence are the P values corresponding to pairwise comparisons between the dosed group and the controls. The life table analysis regards tumors in animals dying prior to terminal kill as being (directly or indirectly) the cause of death. The incidental tumor test regards these lesions as nonfatal. The Fisher exact test compares directly the overall incidence rates. A lower incidence in the dosed group than in controls is indicated by (N).

(e) Number of tumor-bearing animals/number of animals examined microscopically at the site

(f) Includes one carcinoma, NOS

TABLE A4a. INCIDENCE OF EPITHELIAL TUMORS OF THE LARGE INTESTINE IN MALE F344/N RATS RECEIVING NO TREATMENT IN LIFETIME STUDIES

Asbestos Studies	Incidence	Diagnosis
SR Chrysotile	0/87 (0.0%)	
IR Chrysotile	0/85 (0.0%)	
Tremolite	1/118 (0.8%)	Adenomatous polyp, NOS
Crocidolite (a)	1/117 (0.8%)	Adenomatous polyp, NOS
Amosite	0/117 (0.0%)	Carcinoma, NOS
TOTAL	2/524 (0.4%)	
SD (b)	0.47%	

(a) Both tumors occurred in the same animal
 (b) Standard deviation

TABLE A4b. INCIDENCE OF EPITHELIAL TUMORS OF THE SMALL INTESTINE IN MALE F344/N RATS RECEIVING NO TREATMENT IN LIFETIME STUDIES

Asbestos Studies	Incidence	Diagnosis
SR Chrysotile	1/88 (0.6%)	Mucinous cystadenocarcinoma
IR Chrysotile	0/85 (0.0%)	
Tremolite	0/118 (0.0%)	
Crocidolite	1/117 (0.9%)	Adenocarcinoma, NOS
Amosite	1/117 (0.9%)	Adenomatous polyp
	2/117 (1.7%)	Mucinous cystadenocarcinoma
TOTAL	5/524 (1.0%)	
SD (a)	1.05%	

(a) Standard deviation

TABLE A5. SUMMARY OF THE INCIDENCE OF NONNEOPLASTIC LESIONS IN MALE RATS IN THE LIFETIME FEED STUDY OF TREMOLITE

	Untreated Control	1% Tremolite
Animals initially in study	18	250
Animals necropsied	18	250
Animals examined histopathologically	18	250
INTEGUMENTARY SYSTEM		
*Skin	(118)	(250)
Epidermal inclusion cyst	4 (3%)	3 (1%)
Abscess, NOS	2 (2%)	2 (1%)
Inflammation, chronic focal		1 (0.4%)
Granuloma, NOS		1 (0.4%)
Fibrosis, focal		2 (1%)
Necrosis, focal		1 (0.4%)
Hyperplasia, basal cell	1 (1%)	1 (0.4%)
Hyperkeratosis	2 (2%)	10 (4%)
Acanthosis	5 (4%)	6 (2%)
*Subcutaneous tissue	(118)	(250)
Edema, NOS		1 (0.4%)
Hemorrhage		2 (1%)
Steatitis		1 (0.4%)
Abscess, NOS	1 (1%)	3 (1%)
Inflammation, chronic focal	1 (1%)	
RESPIRATORY SYSTEM		
*Nasal turbinate	(118)	(250)
Inflammation, acute diffuse		1 (0.4%)
Necrosis, focal		1 (0.4%)
#Lung/bronchus	(118)	(250)
Fibrosis, focal		1 (0.4%)
#Lung	(118)	(250)
Congestion, NOS	7 (6%)	11 (4%)
Hemorrhage	8 (7%)	13 (5%)
Inflammation, interstitial	8 (7%)	9 (4%)
Pneumonia, aspiration	1 (1%)	1 (0.4%)
Inflammation, fibrinous		1 (0.4%)
Inflammation, acute focal	2 (2%)	1 (0.4%)
Inflammation, chronic	89 (75%)	230 (92%)
Inflammation, chronic focal	1 (1%)	
Fibrosis, diffuse		2 (1%)
Pigmentation, NOS		3 (1%)
Hyperplasia, alveolar epithelium	7 (6%)	8 (3%)
Metaplasia, osseous		1 (0.4%)
#Lung/alveoli	(118)	(250)
Edema, NOS	1 (1%)	1 (0.4%)
Histiocytosis	6 (5%)	12 (5%)
HEMATOPOIETIC SYSTEM		
#Bone marrow	(117)	(248)
Hemorrhage	1 (1%)	1 (0.4%)
Hypoplasia, NOS	5 (4%)	11 (4%)
Hyperplasia, NOS	7 (6%)	9 (4%)
#Spleen	(118)	(250)
Congestion, NOS		1 (0.4%)
Hemorrhage		3 (1%)
Fibrosis, focal	11 (9%)	18 (7%)
Fibrosis, multifocal		3 (1%)
Fibrosis, diffuse	6 (5%)	8 (3%)
Necrosis, NOS		1 (0.4%)
Necrosis, focal	1 (1%)	11 (4%)
Amyloidosis		1 (0.4%)
Metamorphosis fatty		2 (1%)

TABLE A5. SUMMARY OF THE INCIDENCE OF NONNEOPLASTIC LESIONS IN MALE RATS IN THE LIFETIME FEED STUDY OF TREMOLITE (Continued)

	Untreated Control	1% Tremolite
HEMATOPOIETIC SYSTEM		
#Spleen (Continued)	(118)	(250)
Pigmentation, NOS		2 (1%)
Hemosiderosis	19 (16%)	49 (20%)
Hyperplasia, nodular		1 (0.4%)
Hyperplasia, stromal		1 (0.4%)
Hyperplasia, reticulum cell		2 (1%)
Hyperplasia, lymphoid		3 (1%)
Hematopoiesis	35 (30%)	54 (22%)
#Splenic capsule	(118)	(250)
Cyst, NOS	1 (1%)	
#Splenic follicles	(118)	(250)
Atrophy, NOS	2 (2%)	9 (4%)
Atrophy, focal	1 (1%)	
#Mandibular lymph node	(118)	(250)
Congestion, NOS	1 (1%)	1 (0.4%)
Hemorrhage	1 (1%)	1 (0.4%)
Abscess, NOS		1 (0.4%)
Pigmentation, NOS		1 (0.4%)
Hyperplasia, NOS	1 (1%)	
Hyperplasia, reticulum cell		1 (0.4%)
Hyperplasia, lymphoid	30 (25%)	37 (15%)
#Cervical lymph node	(118)	(250)
Erythrophagocytosis		1 (0.4%)
Hyperplasia, lymphoid		1 (0.4%)
#Mediastinal lymph node	(118)	(250)
Congestion, NOS	5 (4%)	3 (1%)
Hemorrhage	6 (5%)	12 (5%)
Inflammation, acute		1 (0.4%)
Inflammation, chronic		1 (0.4%)
Necrosis, NOS		1 (0.4%)
Pigmentation, NOS	20 (17%)	22 (9%)
Atrophy, NOS	1 (1%)	1 (0.4%)
Erythrophagocytosis	6 (5%)	6 (2%)
Hyperplasia, reticulum cell	6 (5%)	5 (2%)
Hyperplasia, lymphoid	8 (7%)	3 (1%)
Hematopoiesis		1 (0.4%)
#Pancreatic lymph node	(118)	(250)
Pigmentation, NOS	5 (4%)	4 (2%)
Hyperplasia, reticulum cell	4 (3%)	6 (2%)
Hyperplasia, lymphoid	1 (1%)	2 (1%)
#Mesenteric lymph node	(118)	(250)
Hemorrhage	2 (2%)	1 (0.4%)
Pigmentation, NOS	1 (1%)	2 (1%)
Atrophy, NOS	1 (1%)	
Erythrophagocytosis	2 (2%)	7 (3%)
Hyperplasia, reticulum cell	29 (25%)	65 (26%)
Hyperplasia, lymphoid	6 (5%)	13 (5%)
#Ileocolic lymph node	(118)	(250)
Hemorrhage		1 (0.4%)
Inflammation, chronic		1 (0.4%)
Fibrosis	1 (1%)	
Fibrosis, focal		1 (0.4%)
Hyperplasia, reticulum cell	1 (1%)	
#Renal lymph node	(118)	(250)
Pigmentation, NOS	1 (1%)	4 (2%)
Hyperplasia, reticulum cell	1 (1%)	3 (1%)
Hyperplasia, lymphoid		2 (1%)
#Iliac lymph node	(118)	(250)
Inflammation, acute		1 (0.4%)
Erythrophagocytosis		1 (0.4%)
#Lung	(118)	(250)
Leukocytosis, NOS	1 (1%)	

TABLE A5. SUMMARY OF THE INCIDENCE OF NONNEOPLASTIC LESIONS IN MALE RATS IN THE LIFETIME FEED STUDY OF TREMOLITE (Continued)

	Untreated Control	1% Tremolite
HEMATOPOIETIC SYSTEM (Continued)		
#Liver	(118)	(250)
Leukocytosis, NOS	2 (2%)	5 (2%)
Hematopoiesis	1 (1%)	3 (1%)
#Thymus	(89)	(196)
Cystic ducts	1 (1%)	
Congestion, NOS		2 (1%)
Hyperplasia, epithelial	2 (2%)	
CIRCULATORY SYSTEM		
#Cerebrum	(118)	(250)
Thrombosis, NOS	1 (1%)	
*Mediastinum	(118)	(250)
Thrombosis, NOS	1 (1%)	
Periarteritis		1 (0.4%)
#Spleen	(118)	(250)
Thrombosis, NOS		3 (1%)
#Mandibular lymph node	(118)	(250)
Lymphangiectasis	4 (3%)	11 (4%)
#Mediastinal lymph node	(118)	(250)
Lymphangiectasis	5 (4%)	5 (2%)
Thrombosis, NOS		1 (0.4%)
#Pancreatic lymph node	(118)	(250)
Lymphangiectasis	1 (1%)	1 (0.4%)
#Mesenteric lymph node	(118)	(250)
Lymphangiectasis	6 (5%)	11 (4%)
#Ileocolic lymph node	(118)	(250)
Lymphangiectasis	3 (3%)	2 (1%)
#Iliac lymph node	(118)	(250)
Lymphangiectasis		2 (1%)
#Lung	(118)	(250)
Thrombosis, NOS		3 (1%)
#Heart	(118)	(250)
Inflammation, chronic		1 (0.4%)
Inflammation, chronic focal	1 (1%)	
Inflammation, chronic diffuse		1 (0.4%)
#Heart/atrium	(118)	(250)
Thrombosis, NOS	5 (4%)	3 (1%)
#Myocardium	(118)	(250)
Mineralization	2 (2%)	1 (0.4%)
Inflammation, acute focal		1 (0.4%)
Inflammation, chronic focal	35 (30%)	88 (35%)
Inflammation, chronic diffuse	35 (30%)	100 (40%)
Fibrosis, focal	2 (2%)	
Fibrosis, multifocal		1 (0.4%)
Degeneration, NOS		1 (0.4%)
#Cardiac valve	(118)	(250)
Inflammation, chronic		1 (0.4%)
Inflammation, chronic focal	1 (1%)	1 (0.4%)
*Aorta	(118)	(250)
Mineralization	1 (1%)	2 (1%)
*Mesenteric artery	(118)	(250)
Mineralization	4 (3%)	1 (0.4%)
#Liver	(118)	(250)
Embolus, septic		1 (0.4%)
#Pancreas	(118)	(250)
Periarteritis	2 (2%)	4 (2%)
*Mesentery	(118)	(250)
Periarteritis	3 (3%)	8 (3%)
#Kidney	(118)	(250)
Embolus, septic		1 (0.4%)

TABLE A5. SUMMARY OF THE INCIDENCE OF NONNEOPLASTIC LESIONS IN MALE RATS IN THE LIFETIME FEED STUDY OF TREMOLITE (Continued)

	Untreated Control	1% Tremolite
CIRCULATORY SYSTEM (Continued)		
#Testis	(118)	(250)
Periarteritis	2 (2%)	1 (0.4%)
#Adrenal	(118)	(250)
Thrombosis, NOS	3 (3%)	3 (1%)
#Adrenal cortex	(118)	(250)
Thrombosis, NOS		1 (0.4%)
DIGESTIVE SYSTEM		
*Hard palate	(118)	(250)
Hyperkeratosis		1 (0.4%)
Acanthosis		1 (0.4%)
*Tongue	(118)	(250)
Acanthosis	1 (1%)	2 (1%)
#Salivary gland	(116)	(245)
Atrophy, NOS		1 (0.4%)
Atrophy, diffuse		1 (0.4%)
#Parotid gland	(116)	(245)
Inflammation, chronic		1 (0.4%)
Degeneration, NOS		1 (0.4%)
#Liver	(118)	(250)
Congestion, NOS	1 (1%)	3 (1%)
Hemorrhage	3 (3%)	1 (0.4%)
Hemorrhagic cyst		1 (0.4%)
Inflammation, acute focal		1 (0.4%)
Inflammation, acute diffuse		1 (0.4%)
Abscess, NOS		1 (0.4%)
Inflammation, chronic	1 (1%)	
Inflammation, chronic focal		1 (0.4%)
Granuloma, NOS	12 (10%)	15 (6%)
Fibrosis, focal	1 (1%)	
Fibrosis, multifocal	1 (1%)	
Hepatitis, toxic	15 (13%)	28 (11%)
Degeneration, NOS	17 (14%)	18 (7%)
Degeneration, cystic	1 (1%)	2 (1%)
Necrosis, NOS		1 (0.4%)
Necrosis, focal	18 (15%)	20 (8%)
Necrosis, diffuse		1 (0.4%)
Metamorphosis fatty	17 (14%)	36 (14%)
Pigmentation, NOS	10 (8%)	38 (15%)
Focal cellular change	39 (33%)	66 (26%)
Angiectasis	3 (3%)	10 (4%)
#Bile duct	(118)	(250)
Dilatation, NOS		1 (0.4%)
Inflammation, chronic	23 (19%)	24 (10%)
Fibrosis	5 (4%)	2 (1%)
Necrosis, focal	1 (1%)	
Pigmentation, NOS	1 (1%)	
Hyperplasia, NOS	38 (32%)	45 (18%)
#Pancreas	(118)	(250)
Ectopia	3 (3%)	9 (4%)
Calculus, unknown gross or microscopic observation		1 (0.4%)
Inflammation, chronic focal	1 (1%)	2 (1%)
Fibrosis, diffuse		1 (0.4%)
Degeneration, NOS		1 (0.4%)
Lipoidosis	1 (1%)	
Pigmentation, NOS		1 (0.4%)
Atrophy, NOS		2 (1%)
Atrophy, focal	18 (15%)	27 (11%)
Atrophy, diffuse	5 (4%)	4 (2%)
Hyperplasia, focal		2 (1%)

TABLE A5. SUMMARY OF THE INCIDENCE OF NONNEOPLASTIC LESIONS IN MALE RATS IN THE LIFETIME FEED STUDY OF TREMOLITE (Continued)

	Untreated Control	1% Tremolite
DIGESTIVE SYSTEM (Continued)		
#Pancreatic duct	(118)	(250)
Hyperplasia, NOS		1 (0.4%)
#Pancreatic acinus	(118)	(250)
Hyperplasia, focal	7 (6%)	17 (7%)
#Esophagus	(116)	(249)
Inflammation, chronic diffuse	1 (1%)	
Necrosis, focal	2 (2%)	1 (0.4%)
Hyperkeratosis	9 (8%)	18 (7%)
Acanthosis	1 (1%)	
#Stomach	(118)	(250)
Embryonal rest		1 (0.4%)
Mineralization	10 (8%)	4 (2%)
Cyst, NOS		1 (0.4%)
Edema, NOS	1 (1%)	2 (1%)
Hemorrhage	2 (2%)	
Inflammation, acute focal	1 (1%)	2 (1%)
Inflammation, chronic	1 (1%)	
Inflammation, chronic focal	4 (3%)	12 (5%)
Inflammation, chronic diffuse	14 (12%)	27 (11%)
Ulcer, perforated	10 (8%)	17 (7%)
Fibrosis, diffuse		1 (0.4%)
Adhesion, NOS		1 (0.4%)
Necrosis, focal	19 (16%)	46 (18%)
Hyperplasia, epithelial	2 (2%)	
Hyperplasia, diffuse		1 (0.4%)
Hyperkeratosis	17 (14%)	34 (14%)
Acanthosis	26 (22%)	54 (22%)
Polyp, inflammatory		1 (0.4%)
#Gastric muscularis	(118)	(250)
Degeneration, NOS	7 (6%)	
Necrosis, diffuse		1 (0.4%)
#Gastric fundus	(118)	(250)
Hyperplasia, epithelial	3 (3%)	
Hyperplasia, focal		1 (0.4%)
Hyperplasia, diffuse	4 (3%)	
#Small intestine	(118)	(250)
Inflammation, chronic		1 (0.4%)
#Duodenum	(118)	(250)
Necrosis, focal	2 (2%)	1 (0.4%)
#Jejunum	(118)	(250)
Abscess, NOS	1 (1%)	
#Ileum	(118)	(250)
Inflammation, chronic diffuse		1 (0.4%)
Granuloma, NOS		1 (0.4%)
Ulcer, perforated		1 (0.4%)
#Large intestine	(118)	(250)
Parasitism		1 (0.4%)
#Colon	(118)	(250)
Edema, NOS		1 (0.4%)
Inflammation, acute focal		1 (0.4%)
Inflammation, chronic focal		3 (1%)
Inflammation, chronic diffuse		1 (0.4%)
Parasitism	5 (4%)	32 (13%)
Necrosis, focal		3 (1%)
Hyperplasia, epithelial		1 (0.4%)
#Colonic muscularis propria	(118)	(250)
Degeneration, NOS	1 (1%)	
#Cecum	(118)	(250)
Congestion, NOS		1 (0.4%)
Edema, NOS		1 (0.4%)
Hemorrhage	1 (1%)	1 (0.4%)
Inflammation, acute focal	1 (1%)	

TABLE A5. SUMMARY OF THE INCIDENCE OF NONNEOPLASTIC LESIONS IN MALE RATS IN THE LIFETIME FEED STUDY OF TREMOLITE (Continued)

	Untreated Control	1% Tremolite
DIGESTIVE SYSTEM		
#Cecum (Continued)	(118)	(250)
Inflammation, chronic diffuse		2 (1%)
Parasitism		2 (1%)
Necrosis, focal	1 (1%)	2 (1%)
Necrosis, diffuse		2 (1%)
#Descending colon	(118)	(250)
Abscess, NOS	1 (1%)	
*Rectum	(118)	(250)
Necrosis, focal		1 (0.4%)
URINARY SYSTEM		
#Kidney	(118)	(250)
Mineralization	9 (8%)	10 (4%)
Hydronephrosis		2 (1%)
Congestion, NOS	2 (2%)	2 (1%)
Inflammation, acute focal		1 (0.4%)
Inflammation, chronic	92 (78%)	228 (91%)
Fibrosis, diffuse		1 (0.4%)
Infarct, NOS	1 (1%)	
Infarct, healed		2 (1%)
Pigmentation, NOS		1 (0.4%)
Hyperplasia, tubular cell	1 (1%)	5 (2%)
#Kidney/cortex	(118)	(250)
Cyst, NOS	19 (16%)	12 (5%)
Multilocular cyst		2 (1%)
Multiple cysts	2 (2%)	1 (0.4%)
#Kidney/medulla	(118)	(250)
Necrosis, focal		1 (0.4%)
#Renal papilla	(118)	(250)
Hyperplasia, papillary		1 (0.4%)
#Kidney/tubule	(118)	(250)
Pigmentation, NOS	29 (25%)	56 (22%)
#Kidney/pelvis	(118)	(250)
Dilatation, NOS		1 (0.4%)
#Urinary bladder	(118)	(250)
Hemorrhage	2 (2%)	6 (2%)
Inflammation, acute diffuse	2 (2%)	4 (2%)
Inflammation, chronic diffuse		3 (1%)
Necrosis, focal		1 (0.4%)
Necrosis, diffuse		2 (1%)
Hyperplasia, epithelial	1 (1%)	
Hyperplasia, diffuse		1 (0.4%)
Hyperplasia, papillary	2 (2%)	3 (1%)
Metaplasia, squamous		1 (0.4%)
#Urinary bladder/submucosa	(118)	(250)
Fibrosis, diffuse	1 (1%)	
*Urethra	(118)	(250)
Inflammation, acute focal	1 (1%)	
ENDOCRINE SYSTEM		
#Pituitary	(118)	(247)
Cyst, NOS	2 (2%)	7 (3%)
Hemorrhage	1 (1%)	3 (1%)
Hemorrhagic cyst		3 (1%)
Inflammation, acute	1 (1%)	
Necrosis, NOS	1 (1%)	
Pigmentation, NOS	1 (1%)	1 (0.4%)
Hyperplasia, focal	12 (10%)	17 (7%)
Angiectasis	11 (9%)	16 (6%)

TABLE A5. SUMMARY OF THE INCIDENCE OF NONNEOPLASTIC LESIONS IN MALE RATS IN THE LIFETIME FEED STUDY OF TREMOLITE (Continued)

	Untreated Control	1% Tremolite
ENDOCRINE SYSTEM (Continued)		
#Adrenal	(118)	(250)
Mineralization		1 (0.4%)
Hemorrhage	1 (1%)	1 (0.4%)
Hemorrhagic cyst	1 (1%)	
Inflammation, chronic focal	1 (1%)	
Inflammation, chronic diffuse		1 (0.4%)
Necrosis, focal	1 (1%)	1 (0.4%)
Infarct, NOS		1 (0.4%)
Angiectasis	1 (1%)	3 (1%)
#Adrenal/capsule	(118)	(250)
Fibrosis, focal		1 (0.4%)
Fibrosis, diffuse		1 (0.4%)
#Adrenal cortex	(118)	(250)
Degeneration, NOS	1 (1%)	3 (1%)
Degeneration, lipoid		1 (0.4%)
Metamorphosis fatty	27 (23%)	50 (20%)
Hyperplasia, focal	12 (10%)	13 (5%)
Angiectasis	5 (4%)	
#Adrenal medulla	(118)	(250)
Hyperplasia, NOS	1 (1%)	
Hyperplasia, focal	40 (34%)	77 (31%)
#Thyroid	(117)	(247)
Cystic follicles	1 (1%)	2 (1%)
Follicular cyst, NOS	4 (3%)	14 (6%)
Hyperplasia, C-cell	25 (21%)	50 (20%)
Hyperplasia, follicular cell		1 (0.4%)
#Parathyroid	(109)	(236)
Inflammation, chronic	1 (1%)	
Hyperplasia, NOS	26 (24%)	22 (9%)
#Pancreatic islets	(118)	(250)
Hyperplasia, focal	4 (3%)	3 (1%)
REPRODUCTIVE SYSTEM		
*Mammary gland	(118)	(250)
Galactocele	1 (1%)	1 (0.4%)
Cystic ducts	6 (5%)	8 (3%)
Hyperplasia, NOS		1 (0.4%)
Hyperplasia, focal	1 (1%)	2 (1%)
Hyperplasia, diffuse	9 (8%)	12 (5%)
*Preputial gland	(118)	(250)
Cyst, NOS		1 (0.4%)
Cystic ducts	2 (2%)	13 (5%)
Inflammation, acute diffuse		2 (1%)
Abscess, NOS	1 (1%)	3 (1%)
Inflammation, chronic		1 (0.4%)
Inflammation, chronic diffuse		1 (0.4%)
Hyperplasia, diffuse		1 (0.4%)
Hyperkeratosis	1 (1%)	
#Prostate	(118)	(249)
Cyst, NOS		4 (2%)
Hemorrhage		2 (1%)
Inflammation, acute focal		1 (0.4%)
Inflammation, acute diffuse		1 (0.4%)
Abscess, NOS	9 (8%)	27 (11%)
Inflammation, acute/chronic		1 (0.4%)
Inflammation, chronic		1 (0.4%)
Inflammation, chronic focal	36 (31%)	67 (27%)
Inflammation, chronic diffuse	4 (3%)	28 (11%)
Necrosis, focal		1 (0.4%)
Hyperplasia, focal	11 (9%)	24 (10%)

TABLE A5. SUMMARY OF THE INCIDENCE OF NONNEOPLASTIC LESIONS IN MALE RATS IN THE LIFETIME FEED STUDY OF TREMOLITE (Continued)

	Untreated Control	1% Tremolite
REPRODUCTIVE SYSTEM		
#Prostate (Continued)	(118)	(249)
Hyperkeratosis		1 (0.4%)
Metaplasia, squamous		2 (1%)
*Seminal vesicle	(118)	(250)
Cyst, NOS	3 (3%)	13 (5%)
Cystic ducts		3 (1%)
Hemorrhage		1 (0.4%)
Inflammation, acute diffuse		3 (1%)
Abscess, NOS		4 (2%)
Inflammation, chronic		1 (0.4%)
Inflammation, chronic diffuse	1 (1%)	2 (1%)
Hyperplasia, epithelial	1 (1%)	1 (0.4%)
Hyperplasia, diffuse	2 (2%)	7 (3%)
*Coagulating gland	(118)	(250)
Hyperplasia, NOS		1 (0.4%)
Metaplasia, squamous		1 (0.4%)
#Testis	(118)	(250)
Granuloma, spermatic	1 (1%)	
Degeneration, NOS	10 (8%)	31 (12%)
Infarct, NOS	1 (1%)	1 (0.4%)
Hyperplasia, interstitial cell	36 (31%)	89 (36%)
*Epididymis	(118)	(250)
Steatitis		1 (0.4%)
Fibrosis, focal		1 (0.4%)
Necrosis, NOS		1 (0.4%)
Necrosis, fat		4 (2%)
*Vas deferens/muscula	(118)	(250)
Degeneration, NOS	1 (1%)	
NERVOUS SYSTEM		
#Cerebrum	(118)	(250)
Hemorrhage		4 (2%)
Inflammation, chronic		1 (0.4%)
Necrosis, focal		1 (0.4%)
Necrosis, diffuse		1 (0.4%)
#Cerebellum	(118)	(250)
Hemorrhage	3 (3%)	5 (2%)
Gliosis	1 (1%)	
Necrosis, focal		1 (0.4%)
#Medulla oblongata	(118)	(250)
Necrosis, focal	1 (1%)	
*Spinal cord	(118)	(250)
Gliosis	1 (1%)	
SPECIAL SENSE ORGANS		
*Eye	(118)	(250)
Hemorrhage	7 (6%)	11 (4%)
Inflammation, chronic diffuse	1 (1%)	
Synechia, posterior	7 (6%)	8 (3%)
Cataract	21 (18%)	34 (14%)
Phthisis bulbi	2 (2%)	4 (2%)
*Eye anterior chamber	(118)	(250)
Empyema	4 (3%)	2 (1%)
*Vitreous body	(118)	(250)
Vascularization	3 (3%)	2 (1%)
*Eye/cornea	(118)	(250)
Inflammation, focal	1 (1%)	
Inflammation, necrotizing	2 (2%)	
Inflammation, chronic		1 (0.4%)
Inflammation, chronic focal	6 (5%)	1 (0.4%)

TABLE A5. SUMMARY OF THE INCIDENCE OF NONNEOPLASTIC LESIONS IN MALE RATS IN THE LIFETIME FEED STUDY OF TREMOLITE (Continued)

	Untreated Control	1% Tremolite
SPECIAL SENSE ORGANS		
*Eye/cornea (Continued)	(118)	(250)
Inflammation, chronic diffuse	2 (2%)	3 (1%)
*Eye/retina	(118)	(250)
Degeneration, NOS	35 (30%)	66 (26%)
*Eye/crystalline lens	(118)	(250)
Rupture	6 (5%)	3 (1%)
*Harderian gland	(118)	(250)
Inflammation, acute diffuse		1 (0.4%)
*Zymbal gland	(118)	(250)
Cystic ducts	20 (17%)	36 (14%)
Hyperkeratosis		2 (1%)
Acanthosis	1 (1%)	
MUSCULOSKELETAL SYSTEM		
*Skull	(118)	(250)
Osteopetrosis	2 (2%)	4 (2%)
Fibrous osteodystrophy	2 (2%)	1 (0.4%)
*Temporal bone	(118)	(250)
Fibrous osteodystrophy	1 (1%)	
*Maxilla	(118)	(250)
Exostosis		1 (0.4%)
*Sternum	(118)	(250)
Fibrosis	1 (1%)	
Degeneration, NOS		1 (0.4%)
Fibrous osteodystrophy	2 (2%)	
Exostosis	1 (1%)	
*Rib	(118)	(250)
Degeneration, NOS		3 (1%)
Fibrous osteodystrophy	1 (1%)	
BODY CAVITIES		
*Mediastinum	(118)	(250)
Ectopia	2 (2%)	
Inflammation, acute diffuse	1 (1%)	1 (0.4%)
Inflammation, chronic	1 (1%)	
Hemosiderosis	1 (1%)	
*Abdominal cavity	(118)	(250)
Hemorrhage		1 (0.4%)
Abscess, NOS		1 (0.4%)
Inflammation, chronic diffuse		1 (0.4%)
Necrosis, fat	7 (6%)	14 (6%)
*Mesentery	(118)	(250)
Hematoma, organized	1 (1%)	
Inflammation, acute diffuse	1 (1%)	1 (0.4%)
Inflammation, chronic focal		5 (2%)
Inflammation, chronic diffuse		1 (0.4%)
Necrosis, fat	1 (1%)	
ALL OTHER SYSTEMS		
*Multiple organs	(118)	(250)
Mineralization	5 (4%)	
Hemorrhage	1 (1%)	
Inflammation, acute	1 (1%)	
Inflammation, chronic	23 (19%)	10 (4%)
Necrosis, diffuse		1 (0.4%)
Metamorphosis fatty		1 (0.4%)
Pigmentation, NOS		1 (0.4%)
Hyperplasia, NOS	1 (1%)	1 (0.4%)

TABLE A5. SUMMARY OF THE INCIDENCE OF NONNEOPLASTIC LESIONS IN MALE RATS IN THE LIFETIME FEED STUDY OF TREMOLITE (Continued)

	Untreated Control	1% Tremolite
ALL OTHER SYSTEMS (Continued)		
Diaphragm		
Hernia, NOS		2
Mesentery of colon		
Inflammation, acute diffuse	2	
Inflammation, acute/chronic		1
Inflammation, chronic diffuse		2

SPECIAL MORPHOLOGY SUMMARY

None

* Number of animals receiving complete necropsy examination; all gross lesions including masses examined microscopically.
 # Number of animals examined microscopically at this site

APPENDIX B

SUMMARY OF LESIONS IN FEMALE RATS IN THE LIFETIME FEED STUDY OF TREMOLITE

		PAGE
TABLE B1	SUMMARY OF THE INCIDENCE OF NEOPLASMS IN FEMALE RATS IN THE LIFETIME FEED STUDY OF TREMOLITE	110
TABLE B2	INDIVIDUAL ANIMAL TUMOR PATHOLOGY OF FEMALE RATS IN THE LIFETIME FEED STUDY OF TREMOLITE	114
TABLE B3	ANALYSIS OF PRIMARY TUMORS IN FEMALE RATS IN THE LIFETIME FEED STUDY OF TREMOLITE	144
TABLE B4	SUMMARY OF THE INCIDENCE OF NONNEOPLASTIC LESIONS IN FEMALE RATS IN THE LIFETIME FEED STUDY OF TREMOLITE	151

TABLE B1. SUMMARY OF THE INCIDENCE OF NEOPLASMS IN FEMALE RATS IN THE LIFETIME FEED STUDY OF TREMOLITE

	Untreated Control	1% Tremolite
Animals initially in study	118	250
Animals necropsied	118	250
Animals examined histopathologically	118	250
INTEGUMENTARY SYSTEM		
*Skin	(118)	(250)
Squamous cell papilloma	1 (1%)	7 (3%)
Squamous cell carcinoma		1 (0.4%)
Keratoacanthoma		2 (1%)
Fibroma	1 (1%)	2 (1%)
Fibrosarcoma		1 (0.4%)
Neurofibrosarcoma	1 (1%)	
*Subcutaneous tissue	(118)	(250)
Squamous cell carcinoma, invasive	1 (1%)	2 (1%)
Fibroma	5 (4%)	8 (3%)
Fibrosarcoma	2 (2%)	4 (2%)
Fibrous histiocytoma, malignant		1 (0.4%)
Lipoma		1 (0.4%)
Neurofibroma	3 (3%)	2 (1%)
Neurofibrosarcoma		3 (1%)
RESPIRATORY SYSTEM		
#Trachea	(118)	(250)
Follicular cell carcinoma, invasive		1 (0.4%)
#Lung	(118)	(250)
Papillary carcinoma, metastatic		1 (0.4%)
Squamous cell carcinoma, metastatic		2 (1%)
Adenocarcinoma, NOS, metastatic	1 (1%)	1 (0.4%)
Alveolar/bronchiolar adenoma		1 (0.4%)
Alveolar/bronchiolar carcinoma	3 (3%)	2 (1%)
Follicular cell carcinoma, metastatic		1 (0.4%)
C-cell carcinoma, metastatic	1 (1%)	2 (1%)
Pheochromocytoma, metastatic		1 (0.4%)
Fibrosarcoma, metastatic		1 (0.4%)
Osteosarcoma, metastatic	1 (1%)	1 (0.4%)
HEMATOPOIETIC SYSTEM		
*Multiple organs	(118)	(250)
Malignant lymphoma, NOS		1 (0.4%)
Malignant lymphoma, undifferentiated type	1 (1%)	
Myelomonocytic leukemia	2 (2%)	6 (2%)
Monocytic leukemia	50 (42%)	95 (38%)
#Spleen	(118)	(250)
Leiomyosarcoma, invasive	1 (1%)	
#Mandibular lymph node	(118)	(250)
Carcinoma, NOS, metastatic		1 (0.4%)
C-cell carcinoma, metastatic	1 (1%)	
#Cervical lymph node	(118)	(250)
Malignant lymphoma, lymphocytic type	1 (1%)	
#Mediastinal lymph node	(118)	(250)
Neurofibrosarcoma, metastatic		1 (0.4%)
#Liver	(118)	(250)
Monocytic leukemia	4 (3%)	
#Thymus	(83)	(221)
Carcinoma, NOS		1 (0.5%)

TABLE B1. SUMMARY OF THE INCIDENCE OF NEOPLASMS IN FEMALE RATS IN THE LIFETIME FEED STUDY OF TREMOLITE (Continued)

	Untreated Control	1% Tremolite
CIRCULATORY SYSTEM		
*Multiple organs	(118)	(250)
Hemangiosarcoma, invasive		1 (0.4%)
*Mesentery	(118)	(250)
Hemangiosarcoma		1 (0.4%)
#Uterus	(118)	(249)
Hemangiosarcoma	1 (1%)	
DIGESTIVE SYSTEM		
*Oral mucous membrane	(118)	(250)
Squamous cell carcinoma	1 (1%)	3 (1%)
*Palate	(118)	(250)
Squamous cell carcinoma, invasive	1 (1%)	
*Tongue	(118)	(250)
Squamous cell papilloma		1 (0.4%)
Squamous cell carcinoma		1 (0.4%)
Squamous cell carcinoma, invasive		1 (0.4%)
#Salivary gland	(118)	(249)
Sarcoma, NOS		1 (0.4%)
#Parotid gland	(118)	(249)
Squamous cell carcinoma, invasive		1 (0.4%)
Fibrosarcoma	1 (1%)	
#Liver	(118)	(250)
Neoplastic nodule	2 (2%)	10 (4%)
#Pancreas	(118)	(250)
Acinar cell adenoma		3 (1%)
Fibrosarcoma	1 (1%)	
#Esophagus	(118)	(248)
Follicular cell carcinoma, invasive		2 (1%)
#Duodenum	(118)	(250)
Fibroma		1 (0.4%)
Leiomyosarcoma	1 (1%)	1 (0.4%)
#Jejunum	(118)	(250)
Adenomatous polyp, NOS	1 (1%)	
#Ileum	(118)	(250)
Leiomyoma	1 (1%)	
#Colon	(118)	(250)
Leiomyosarcoma	1 (1%)	
#Cecum	(118)	(250)
Fibroma	1 (1%)	
#Descending colon	(118)	(250)
Adenocarcinoma in adenomatous polyp		1 (0.4%)
URINARY SYSTEM		
#Kidney	(118)	(250)
Tubular cell adenoma		2 (1%)
Tubular cell adenocarcinoma		2 (1%)
Mixed tumor, malignant		2 (1%)
#Urinary bladder	(118)	(246)
Transitional cell papilloma		1 (0.4%)
ENDOCRINE SYSTEM		
#Pituitary	(117)	(248)
Carcinoma, NOS	5 (4%)	11 (4%)
Adenoma, NOS	51 (44%)	93 (38%)
#Adrenal	(118)	(250)
Cortical adenoma	9 (8%)	13 (5%)
Pheochromocytoma	22 (19%)	32 (13%)
Pheochromocytoma, malignant	1 (1%)	4 (2%)
Ganglioneuroma		1 (0.4%)

TABLE B1. SUMMARY OF THE INCIDENCE OF NEOPLASMS IN FEMALE RATS IN THE LIFETIME FEED STUDY OF TREMOLITE (Continued)

	Untreated Control	1% Tremolite
ENDOCRINE SYSTEM (Continued)		
#Thyroid	(118)	(250)
Follicular cell adenoma	3 (3%)	7 (3%)
Follicular cell carcinoma	5 (4%)	15 (6%)
C-cell adenoma	7 (6%)	8 (3%)
C-cell carcinoma	18 (15%)	41 (16%)
#Parathyroid	(113)	(238)
Adenoma, NOS	1 (1%)	
#Pancreatic islets	(118)	(250)
Islet cell adenoma	5 (4%)	8 (3%)
Islet cell carcinoma	3 (3%)	6 (2%)
REPRODUCTIVE SYSTEM		
*Mammary gland	(118)	(250)
Carcinoma, NOS		1 (0.4%)
Adenoma, NOS	2 (2%)	4 (2%)
Adenocarcinoma, NOS	24 (20%)	21 (8%)
Papillary adenocarcinoma		1 (0.4%)
Papillary cystadenoma, NOS	1 (1%)	
Fibroadenoma	62 (53%)	127 (51%)
Neurofibroma		1 (0.4%)
*Preputial gland	(118)	(250)
Carcinoma, NOS		1 (0.4%)
Squamous cell papilloma		1 (0.4%)
Squamous cell carcinoma	6 (5%)	15 (6%)
Keratoacanthoma		1 (0.4%)
*Vagina	(118)	(250)
Squamous cell carcinoma	1 (1%)	
#Uterus	(118)	(249)
Carcinoma, NOS	1 (1%)	
Papillary carcinoma		1 (0.4%)
Adenocarcinoma, NOS	1 (1%)	
Papillary adenocarcinoma	1 (1%)	3 (1%)
Papillary cystadenocarcinoma, NOS	1 (1%)	
Leiomyosarcoma	1 (1%)	
Endometrial stromal polyp	15 (13%)	28 (11%)
Endometrial stromal sarcoma	1 (1%)	3 (1%)
#Cervix uteri	(118)	(249)
Fibrosarcoma		1 (0.4%)
Endometrial stromal sarcoma, invasive	1 (1%)	1 (0.4%)
#Uterus/endometrium	(118)	(249)
Papillary adenocarcinoma		1 (0.4%)
#Ovary	(118)	(249)
Papillary cystadenocarcinoma, NOS	1 (1%)	
Granulosa cell tumor	3 (3%)	3 (1%)
Granulosa cell carcinoma		1 (0.4%)
NERVOUS SYSTEM		
#Cerebrum	(118)	(250)
Carcinoma, NOS, invasive	3 (3%)	3 (1%)
Glioma, NOS		1 (0.4%)
Astrocytoma	1 (1%)	2 (1%)
#Cerebellum	(118)	(250)
Carcinoma, NOS, invasive	1 (1%)	5 (2%)
*Spinal cord	(118)	(250)
Osteosarcoma, invasive		1 (0.4%)

TABLE B1. SUMMARY OF THE INCIDENCE OF NEOPLASMS IN FEMALE RATS IN THE LIFETIME FEED STUDY OF TREMOLITE (Continued)

	Untreated Control	1% Tremolite
SPECIAL SENSE ORGANS		
*Zybal gland	(118)	(250)
Carcinoma in-situ, NOS		1 (0.4%)
Squamous cell papilloma		1 (0.4%)
Squamous cell carcinoma	3 (3%)	6 (2%)
Keratoacanthoma	1 (1%)	
MUSCULOSKELETAL SYSTEM		
*Maxilla	(118)	(250)
Squamous cell carcinoma, invasive	1 (1%)	
*Mandible	(118)	(250)
Squamous cell carcinoma, invasive	1 (1%)	2 (1%)
*Vertebra	(118)	(250)
Osteosarcoma	1 (1%)	1 (0.4%)
BODY CAVITIES		
None		
ALL OTHER SYSTEMS		
*Multiple organs	(118)	(250)
Carcinoma, NOS, invasive		1 (0.4%)
Adenocarcinoma, NOS, invasive	1 (1%)	
Adenocarcinoma, NOS, metastatic		1 (0.4%)
C-cell carcinoma, metastatic		1 (0.4%)
Granulosa cell carcinoma, metastatic		1 (0.4%)
Fibrosarcoma, invasive	1 (1%)	
Fibrosarcoma, metastatic	1 (1%)	
Pituitary fossa		
Carcinoma, NOS, invasive		1
ANIMAL DISPOSITION SUMMARY		
Animals initially in study	18	250
Natural death	15	30
Moribund sacrifice	90	196
Terminal sacrifice	12	21
Accidentally killed, nda	1	3
TUMOR SUMMARY		
Total animals with primary tumors**	115	243
Total primary tumors	342	633
Total animals with benign tumors	100	201
Total benign tumors	192	356
Total animals with malignant tumors	96	188
Total malignant tumors	145	264
Total animals with secondary tumors##	12	30
Total secondary tumors	17	37
Total animals with tumors-- uncertain benign or malignant	5	13
Total uncertain tumors	5	13

* Number of animals receiving complete necropsy examination; all gross lesions including masses examined microscopically.

** Primary tumors: all tumors except secondary tumors

Number of animals examined microscopically at this site

Secondary tumors: metastatic tumors or tumors invasive into an adjacent organ

TABLE B2. INDIVIDUAL ANIMAL TUMOR PATHOLOGY OF FEMALE RATS: CONTROL
(Continued)

ANIMAL NUMBER	0 5	0 6	0 7	0 8	0 9	0 0	0 1	0 2	0 3	0 4	0 5	0 6	0 7	0 8	0 9	0 0	0 1	0 2	0 3	0 4	0 5	0 6	0 7	0 8	0 9	0 0	0 1
WEEKS ON STUDY	1 4	1 3	1 4	1 2	1 2	1 2	1 2	1 2	1 3	1 4	1 3	1 4	1 3	1 4	1 4	1 0	1 1	1 2	1 3	1 4	1 5	1 6	1 7	1 8	1 9	1 0	1 1
INTEGUMENTARY SYSTEM																											
Skin	+	+	+	+	+	+	+	+	+	+	+	+	+	+	+	+	+	+	+	+	+	+	+	+	+	+	+
Squamous cell papilloma																											
Fibroma																											
Neurofibrosarcoma																											
Subcutaneous tissue	+	+	+	+	+	+	+	+	+	+	+	+	+	+	+	+	+	+	+	+	+	+	+	+	+	+	+
Squamous cell carcinoma, invasive																											
Fibroma																											
Fibrosarcoma																											
Neurofibroma																											
RESPIRATORY SYSTEM																											
Lungs and bronchi	+	+	+	+	+	+	+	+	+	+	+	+	+	+	+	+	+	+	+	+	+	+	+	+	+	+	+
Adenocarcinoma, NOS, metastatic																											
Alveolar/bronchiolar carcinoma																											
C-cell carcinoma, metastatic																											
Osteosarcoma, metastatic																											
Trachea	+	+	+	+	+	+	+	+	+	+	+	+	+	+	+	+	+	+	+	+	+	+	+	+	+	+	+
HEMATOPOIETIC SYSTEM																											
Bone marrow	+	+	+	+	+	+	+	+	+	+	+	+	+	+	+	+	+	+	+	+	+	+	+	+	+	+	+
Spleen	+	+	+	+	+	+	+	+	+	+	+	+	+	+	+	+	+	+	+	+	+	+	+	+	+	+	+
Leiomyosarcoma, invasive																											
Lymph nodes	+	+	+	+	+	+	+	+	+	+	+	+	+	+	+	+	+	+	+	+	+	+	+	+	+	+	+
C-cell carcinoma, metastatic																											
Malignant lymphoma, lymphocytic type																											
Thymus	+	+	+	+	+	+	+	+	+	+	+	+	+	+	+	+	+	+	+	+	+	+	+	+	+	+	+
CIRCULATORY SYSTEM																											
Heart	+	+	+	+	+	+	+	+	+	+	+	+	+	+	+	+	+	+	+	+	+	+	+	+	+	+	+
DIGESTIVE SYSTEM																											
Oral cavity	N	N	N	N	N	N	N	N	N	N	N	N	N	N	N	N	N	N	N	N	N	N	N	N	N	N	N
Squamous cell carcinoma																											
Squamous cell carcinoma, invasive																											
Salivary gland																											
Fibrosarcoma																											
Liver	+	+	+	+	+	+	+	+	+	+	+	+	+	+	+	+	+	+	+	+	+	+	+	+	+	+	+
Neoplastic nodule																											
Monocytic leukemia																											
Bile duct	+	+	+	+	+	+	+	+	+	+	+	+	+	+	+	+	+	+	+	+	+	+	+	+	+	+	+
Gallbladder & common bile duct	N	N	N	N	N	N	N	N	N	N	N	N	N	N	N	N	N	N	N	N	N	N	N	N	N	N	N
Pancreas	+	+	+	+	+	+	+	+	+	+	+	+	+	+	+	+	+	+	+	+	+	+	+	+	+	+	+
Fibrosarcoma																											
Esophagus	+	+	+	+	+	+	+	+	+	+	+	+	+	+	+	+	+	+	+	+	+	+	+	+	+	+	+
Stomach	+	+	+	+	+	+	+	+	+	+	+	+	+	+	+	+	+	+	+	+	+	+	+	+	+	+	+
Small intestine	+	+	+	+	+	+	+	+	+	+	+	+	+	+	+	+	+	+	+	+	+	+	+	+	+	+	+
Adenomatous polyp, NOS																											
Leiomyoma																											
Leiomyosarcoma																											
Large intestine	+	+	+	+	+	+	+	+	+	+	+	+	+	+	+	+	+	+	+	+	+	+	+	+	+	+	+
Fibroma																											
Leiomyosarcoma																											
URINARY SYSTEM																											
Kidney	+	+	+	+	+	+	+	+	+	+	+	+	+	+	+	+	+	+	+	+	+	+	+	+	+	+	+
Urinary bladder	+	+	+	+	+	+	+	+	+	+	+	+	+	+	+	+	+	+	+	+	+	+	+	+	+	+	+
ENDOCRINE SYSTEM																											
Pituitary	+	+	+	+	+	+	+	+	+	+	+	+	+	+	+	+	+	+	+	+	+	+	+	+	+	+	+
Carcinoma, NOS																											
Adenoma, NOS																											
Adrenal	X	X	X																								
Cortical adenoma																											
Pheochromocytoma																											
Pheochromocytoma, malignant																											
Thyroid	+	+	+	+	+	+	+	+	+	+	+	+	+	+	+	+	+	+	+	+	+	+	+	+	+	+	+
Follicular cell adenoma																											
Follicular cell carcinoma																											
C-cell adenoma																											
C-cell carcinoma																											
Parathyroid	+	+	+	+	+	+	+	+	+	+	+	+	+	+	+	+	+	+	+	+	+	+	+	+	+	+	+
Adenoma, NOS																											
Pancreatic islets	+	+	+	+	+	+	+	+	+	+	+	+	+	+	+	+	+	+	+	+	+	+	+	+	+	+	+
Islet cell adenoma																											
Islet cell carcinoma																											

TABLE B2. INDIVIDUAL ANIMAL TUMOR PATHOLOGY OF FEMALE RATS: CONTROL
(Continued)

ANIMAL NUMBER	932	933	934	935	936	937	938	939	940	941	942	943	944	945	946	947	948	949	950	951	952	953	954	955	956		
WEEKS ON STUDY	102	106	106	104	107	102	105	102	101	101	101	101	101	108	107	100	104	104	104	101	104	101	104	104	101	104	
INTEGUMENTARY SYSTEM																											
Skin	+	+	+	+	+	+	+	+	+	+	+	+	+	+	+	+	+	+	+	+	+	+	+	+	+	+	
Squamous cell papilloma																											
Fibroma																											
Neurofibrosarcoma																											
Subcutaneous tissue	+	+	+	+	+	+	+	+	+	+	+	+	+	+	+	+	+	+	+	+	+	+	+	+	+	+	
Squamous cell carcinoma, invasive																											
Fibroma																											
Fibrosarcoma														X													
Neurofibroma																											
RESPIRATORY SYSTEM																											
Lungs and bronchi	+	+	+	+	+	+	+	+	+	+	+	+	+	+	+	+	+	+	+	+	+	+	+	+	+	+	
Adenocarcinoma, NOS, metastatic																											
Alveolar/bronchiolar carcinoma																											
C-cell carcinoma, metastatic																											
Osteosarcoma, metastatic																											
Trachea	+	+	+	+	+	+	+	+	+	+	+	+	+	+	+	+	+	+	+	+	+	+	+	+	+	+	
HEMATOPOIETIC SYSTEM																											
Bone marrow	+	+	+	+	+	+	+	+	+	+	+	+	+	+	+	+	+	+	+	+	+	+	+	+	+	+	
Spleen	+	+	+	+	+	+	+	+	+	+	+	+	+	+	+	+	+	+	+	+	+	+	+	+	+	+	
Leiomyosarcoma, invasive																											
Lymph nodes	+	+	+	+	+	+	+	+	+	+	+	+	+	+	+	+	+	+	+	+	+	+	+	+	+	+	
C-cell carcinoma, metastatic																											
Malignant lymphoma, lymphocytic type																											
Thymus	-	+	+	-	+	+	+	+	+	-	-	-	+	-	-	-	+	-	-	+	-	-	+	-	+		
CIRCULATORY SYSTEM																											
Heart	+	+	+	+	+	+	+	+	+	+	+	+	+	+	+	+	+	+	+	+	+	+	+	+	+	+	
DIGESTIVE SYSTEM																											
Oral cavity	N	N	N	N	N	N	N	N	N	N	N	N	N	N	N	N	N	N	N	N	N	N	N	N	N	N	
Squamous cell carcinoma																											
Squamous cell carcinoma, invasive														X													
Salivary gland	+	+	+	+	+	+	+	+	+	+	+	+	+	+	+	+	+	+	+	+	+	+	+	+	+		
Fibrosarcoma																											
Liver	+	+	+	+	+	+	+	+	+	+	+	+	+	+	+	+	+	+	+	+	+	+	+	+	+		
Neoplastic nodule				X																							
Monocytic leukemia																											
Bile duct	+	+	+	+	+	+	+	+	+	+	+	+	+	+	+	+	+	+	+	+	+	+	+	+	+		
Gallbladder & common bile duct	N	N	N	N	N	N	N	N	N	N	N	N	N	N	N	N	N	N	N	N	N	N	N	N	N		
Pancreas	+	+	+	+	+	+	+	+	+	+	+	+	+	+	+	+	+	+	+	+	+	+	+	+	+		
Fibrosarcoma																											
Esophagus	+	+	+	+	+	+	+	+	+	+	+	+	+	+	+	+	+	+	+	+	+	+	+	+	+		
Stomach	+	+	+	+	+	+	+	+	+	+	+	+	+	+	+	+	+	+	+	+	+	+	+	+	+		
Small intestine	+	+	+	+	+	+	+	+	+	+	+	+	+	+	+	+	+	+	+	+	+	+	+	+	+		
Adenomatous polyp, NOS																											
Leiomyoma																											
Leiomyosarcoma																											
Large intestine	X																										
Fibroma	+	+	+	+	+	+	+	+	+	+	+	+	+	+	+	+	+	+	+	+	+	+	+	+	+		
Leiomyosarcoma																											
URINARY SYSTEM																											
Kidney	+	+	+	+	+	+	+	+	+	+	+	+	+	+	+	+	+	+	+	+	+	+	+	+	+		
Urinary bladder	+	+	+	+	+	+	+	+	+	+	+	+	+	+	+	+	+	+	+	+	+	+	+	+	+		
ENDOCRINE SYSTEM																											
Pituitary	+	+	+	+	+	+	+	+	+	+	+	+	+	+	+	+	+	+	+	+	+	+	+	+	+		
Carcinoma, NOS																											
Adenoma, NOS				X																							
Adrenal	+	+	+	+	+	+	+	+	+	+	+	+	+	+	+	+	+	+	+	+	+	+	+	+	+		
Cortical adenoma																											
Pheochromocytoma																											
Pheochromocytoma, malignant																											
Thyroid	+	+	+	+	+	+	+	+	+	+	+	+	+	+	+	+	+	+	+	+	+	+	+	+			
Follicular cell adenoma																											
Follicular cell carcinoma																											
C-cell adenoma																											
C-cell carcinoma	X	X																									
Parathyroid	+	+	+	+	+	+	+	+	+	+	+	+	+	+	+	+	+	+	+	+	+	+	+	+	+		
Adenoma, NOS																											
Pancreatic islets	+	+	+	+	+	+	+	+	+	+	+	+	+	+	+	+	+	+	+	+	+	+	+	+	+		
Islet cell adenoma																											
Islet cell carcinoma																											

TABLE B2.. INDIVIDUAL ANIMAL TUMOR PATHOLOGY OF FEMALE RATS: CONTROL
(Continued)

ANIMAL NUMBER	957	958	959	960	961	962	963	964	965	966	967	968	969	970	971	972	973	974	975	976	977	978	979	980	981		
WEEKS ON STUDY	098	117	126	094	114	144	223	304	502	707	776	811	869	088	124	144	100	108	004	008	007	008	009	000	114	114	
INTEGUMENTARY SYSTEM																											
Skin	+	+	+	+	+	+	+	+	+	+	+	+	+	+	+	+	+	+	+	+	+	+	+	+	+	+	
Squamous cell papilloma																											
Fibroma																											
Neurofibrosarcoma																											
Subcutaneous tissue	+	+	+	+	+	+	+	+	+	+	+	+	+	+	+	+	+	+	+	+	+	+	+	+	+	+	+
Squamous cell carcinoma, invasive																											
Fibroma																											
Fibrosarcoma																											
Neurofibroma																											
RESPIRATORY SYSTEM																											
Lungs and bronchi	+	+	+	+	+	+	+	+	+	+	+	+	+	+	+	+	+	+	+	+	+	+	+	+	+	+	+
Adenocarcinoma, NOS, metastatic																											
Alveolar/bronchiolar carcinoma																											
C-cell carcinoma, metastatic																											
Osteosarcoma, metastatic																											
Trachea	+	+	+	+	+	+	+	+	+	+	+	+	+	+	+	+	+	+	+	+	+	+	+	+	+	+	+
HEMATOPOIETIC SYSTEM																											
Bone marrow	+	+	+	+	+	+	+	+	+	+	+	+	+	+	+	+	+	+	+	+	+	+	+	+	+	+	+
Spleen	+	+	+	+	+	+	+	+	+	+	+	+	+	+	+	+	+	+	+	+	+	+	+	+	+	+	+
Leiomyosarcoma, invasive																											
Lymph nodes	+	+	+	+	+	+	+	+	+	+	+	+	+	+	+	+	+	+	+	+	+	+	+	+	+	+	+
C-cell carcinoma, metastatic																											
Malignant lymphoma, lymphocytic type																											
Thymus	-	+	+	-	+	+	+	+	+	+	+	+	+	+	+	+	+	+	+	+	+	+	+	+	+	+	+
CIRCULATORY SYSTEM																											
Heart	+	+	+	+	+	+	+	+	+	+	+	+	+	+	+	+	+	+	+	+	+	+	+	+	+	+	+
DIGESTIVE SYSTEM																											
Oral cavity	N	N	N	N	N	N	N	N	N	N	N	N	N	N	N	N	N	N	N	N	N	N	N	N	N	N	N
Squamous cell carcinoma																											
Squamous cell carcinoma, invasive																											
Salivary gland	+	+	+	+	+	+	+	+	+	+	+	+	+	+	+	+	+	+	+	+	+	+	+	+	+	+	+
Fibrosarcoma																											
Liver	+	+	+	+	+	+	+	+	+	+	+	+	+	+	+	+	+	+	+	+	+	+	+	+	+	+	+
Neoplastic nodule																											
Monocytic leukemia																											
Bile duct	+	+	+	+	+	+	+	+	+	+	+	+	+	+	+	+	+	+	+	+	+	+	+	+	+	+	+
Gallbladder & common bile duct	N	N	N	N	N	N	N	N	N	N	N	N	N	N	N	N	N	N	N	N	N	N	N	N	N	N	N
Pancreas	+	+	+	+	+	+	+	+	+	+	+	+	+	+	+	+	+	+	+	+	+	+	+	+	+	+	+
Fibrosarcoma																											
Esophagus	+	+	+	+	+	+	+	+	+	+	+	+	+	+	+	+	+	+	+	+	+	+	+	+	+	+	+
Stomach	+	+	+	+	+	+	+	+	+	+	+	+	+	+	+	+	+	+	+	+	+	+	+	+	+	+	+
Small intestine	+	+	+	+	+	+	+	+	+	+	+	+	+	+	+	+	+	+	+	+	+	+	+	+	+	+	+
Adenomatous polyp, NOS																											
Leiomyoma																											
Leiomyosarcoma																											
Large intestine	+	+	+	+	+	+	+	+	+	+	+	+	+	+	+	+	+	+	+	+	+	+	+	+	+	+	+
Fibroma																											
Leiomyosarcoma																											
URINARY SYSTEM																											
Kidney	+	+	+	+	+	+	+	+	+	+	+	+	+	+	+	+	+	+	+	+	+	+	+	+	+	+	+
Urinary bladder	+	+	+	+	+	+	+	+	+	+	+	+	+	+	+	+	+	+	+	+	+	+	+	+	+	+	+
ENDOCRINE SYSTEM																											
Pituitary	+	+	+	+	+	+	+	+	+	+	+	+	+	+	+	+	+	+	+	+	+	+	+	+	+	+	+
Carcinoma, NOS																											
Adenoma, NOS	X	X	X	X	X	X	X					X	X	X	X	X										X	
Adrenal	+	+	+	+	+	+	+	+	+	+	+	+	+	+	+	+	+	+	+	+	+	+	+	+	+	+	+
Cortical adenoma																											
Pheochromocytoma																											
Pheochromocytoma, malignant																											
Thyroid	+	+	+	+	+	+	+	+	+	+	+	+	+	+	+	+	+	+	+	+	+	+	+	+	+	+	+
Follicular cell adenoma																											
Follicular cell carcinoma																											
C-cell adenoma																											
C-cell carcinoma																											
Parathyroid	+	+	+	-	+	+	+	+	+	+	+	+	+	+	+	+	+	+	+	+	+	+	+	+	+	+	+
Adenoma, NOS																											
Pancreatic islets	+	+	+	+	+	+	+	+	+	+	+	+	+	+	+	+	+	+	+	+	+	+	+	+	+	+	+
Islet cell adenoma																											
Islet cell carcinoma																											

TABLE B2. INDIVIDUAL ANIMAL TUMOR PATHOLOGY OF FEMALE RATS: CONTROL
(Continued)

ANIMAL NUMBER	957	958	959	960	961	962	963	964	965	966	967	968	969	970	971	972	973	974	975	976	977	978	979	980	981
WEEKS ON STUDY	098	117	126	094	114	111	114	223	030	333	222	448	224	000	880	008	009	000	119	000	111	114	111	114	111
REPRODUCTIVE SYSTEM																									
Mammary gland	+	+	+	+	+	+	+	+	+	+	+	+	+	+	+	+	+	+	+	+	+	+	+	+	+
Adenoma, NOS																									
Adenocarcinoma, NOS				X	X						X	X	X		X										X
Papillary cystadenoma, NOS																									
Fibroadenoma				X	X						X	X	X												X
Preputial/clitoral gland	N	N	N	N	N	N	N	N	N	N	N	N	N	N	N	N	N	N	N	N	N	N	N	N	N
Squamous cell carcinoma																									
Vagina	N	N	N	N	N	N	N	N	N	N	N	N	N	N	N	N	N	N	N	N	N	N	N	N	N
Squamous cell carcinoma																									
Uterus	+	+	+	+	+	+	+	+	+	+	+	+	+	+	+	+	+	+	+	+	+	+	+	+	+
Carcinoma, NOS																									
Adenocarcinoma, NOS																									
Papillary adenocarcinoma																									
Papillary cystadenocarcinoma, NOS																									
Leiomyosarcoma																									
Endometrial stromal polyp																									
Endometrial stromal sarcoma																							X		X
Endometrial stromal sarcoma, invasive																									
Hemangiosarcoma																									
Ovary	+	+	+	+	+	+	+	+	+	+	+	+	+	+	+	+	+	+	+	+	+	+	+	+	+
Papillary cystadenocarcinoma, NOS																									
Granulosa cell tumor																									
NERVOUS SYSTEM																									
Brain	+	+	+	+	+	+	+	+	+	+	+	+	+	+	+	+	+	+	+	+	+	+	+	+	+
Carcinoma, NOS, invasive																									
Astrocytoma																									
SPECIAL SENSE ORGANS																									
Zymbal gland	+	+	+	+	+	+	+	+	+	+	+	+	+	+	+	+	+	+	+	+	+	+	+	+	+
Squamous cell carcinoma																									
Keratoacanthoma																									
MUSCULOSKELETAL SYSTEM																									
Bone	N	N	N	N	N	N	N	N	N	N	N	N	N	N	N	N	N	N	N	N	N	N	N	N	N
Squamous cell carcinoma, invasive																									
Osteosarcoma																									
ALL OTHER SYSTEMS																									
Multiple organs, NOS	N	N	N	N	N	N	N	N	N	N	N	N	N	N	N	N	N	N	N	N	N	N	N	N	N
Adenocarcinoma, NOS, invasive																									
Fibrosarcoma, invasive																									
Fibrosarcoma, metastatic																									
Malignant lymphoma, undifferentiated type																									
Myelomonocytic leukemia																									
Monocytic leukemia	X	X		X	X		X	X										X		X	X		X		X

**TABLE B2. INDIVIDUAL ANIMAL TUMOR PATHOLOGY OF FEMALE RATS: 1% TREMOLITE
(Continued)**

ANIMAL NUMBER	307	308	309	310	311	312	313	314	315	316	317	318	319	320	321	322	323	324	325	326	327	328	329	330	331		
WEEKS ON STUDY	13	12	11	10	9	8	7	6	5	4	3	2	1	0	1	2	3	4	5	6	7	8	9	10	11	12	
INTEGUMENTARY SYSTEM																											
Skin																											
Squamous cell papilloma	+	+	+	+	+	+	+	+	+	+	+	+	+	+	+	+	+	+	+	+	+	+	+	+	+	+	
Squamous cell carcinoma																										X	
Keratoacanthoma																											
Fibroma																											
Fibrosarcoma																											
Subcutaneous tissue																											
Squamous cell carcinoma, invasive	+	+	+	+	+	+	+	+	+	+	+	+	+	+	+	+	+	+	+	+	+	+	+	+	+	+	
Fibroma																											
Fibrosarcoma																											
Fibrous histiocytoma, malignant																											
Lipoma																											
Neurofibroma																											
Neurofibrosarcoma																											
RESPIRATORY SYSTEM																											
Lungs and bronchi:																											
Papillary carcinoma, metastatic																											
Squamous cell carcinoma, metastatic																											
Adenocarcinoma, NOS, metastatic																											
Alveolar/bronchiolar adenoma																											
Alveolar/bronchiolar carcinoma																											
Follicular cell carcinoma, metastatic																											
C-cell carcinoma, metastatic																											
Pheochromocytoma, metastatic																											
Fibrosarcoma, metastatic																											
Osteosarcoma, metastatic																											
Trachea																											
Follicular cell carcinoma, invasive	+	+	+	+	+	+	+	+	+	+	+	+	+	+	+	+	+	+	+	+	+	+	+	+	+	+	
HEMATOPOIETIC SYSTEM																											
Bone marrow																											
Spleen	+	+	+	+	+	+	+	+	+	+	+	+	+	+	+	+	+	+	+	+	+	+	+	+	+	+	
Lymph nodes	+	+	+	+	+	+	+	+	+	+	+	+	+	+	+	+	+	+	+	+	+	+	+	+	+	+	
Carcinoma, NOS, metastatic																											
Neurofibrosarcoma, metastatic																											
Thymus	+	+	+	+	+	+	+	+	+	+	+	+	+	+	+	+	+	+	+	+	+	+	+	+	+	+	
Carcinoma, NOS																											
CIRCULATORY SYSTEM																											
Heart																											
	+	+	+	+	+	+	+	+	+	+	+	+	+	+	+	+	+	+	+	+	+	+	+	+	+	+	
DIGESTIVE SYSTEM																											
Oral cavity																											
Squamous cell papilloma	N	N	N	N	N	N	N	N	N	N	N	N	N	N	N	N	N	N	N	N	N	N	N	N	N	N	
Squamous cell carcinoma																											
Squamous cell carcinoma, invasive																											
Salivary gland																											
Squamous cell carcinoma, invasive	+	+	+	+	+	+	+	+	+	+	+	+	+	+	+	+	+	+	+	+	+	+	+	+	+	+	
Sarcoma, NOS																											
Liver																											
Neoplastic nodule	+	+	+	+	+	+	+	+	+	+	+	+	+	+	+	+	+	+	+	+	+	+	+	+	+	+	
Bile duct																											
Gallbladder & common bile duct																											
Pancreas	+	+	+	+	+	+	+	+	+	+	+	+	+	+	+	+	+	+	+	+	+	+	+	+	+	+	
Acinar cell adenoma																											
Esophagus																											
Follicular cell carcinoma, invasive	+	+	+	+	+	+	+	+	+	+	+	+	+	+	+	+	+	+	+	+	+	+	+	+	+	+	
Stomach																											
Small intestine	+	+	+	+	+	+	+	+	+	+	+	+	+	+	+	+	+	+	+	+	+	+	+	+	+	+	
Fibroma																											
Leiomyosarcoma																											
Large intestine																											
Adenocarcinoma in adenomatous polyp	+	+	+	+	+	+	+	+	+	+	+	+	+	+	+	+	+	+	+	+	+	+	+	+	+	+	
URINARY SYSTEM																											
Kidney																											
Tubular cell adenoma	+	+	+	+	+	+	+	+	+	+	+	+	+	+	+	+	+	+	+	+	+	+	+	+	+	+	
Tubular cell adenocarcinoma																											
Mixed tumor, malignant																											
Urinary bladder																											
Transitional cell papilloma	+	+	+	+	+	+	+	+	+	+	+	+	+	+	+	+	+	+	+	+	+	+	+	+	+	+	

**TABLE B2. INDIVIDUAL ANIMAL TUMOR PATHOLOGY OF FEMALE RATS: 1% TREMOLITE
(Continued)**

ANIMAL NUMBER	37	38	39	30	31	32	33	34	35	36	37	38	39	40	41	42	43	44	45	46	47	48	49	50	51		
WEEKS ON STUDY	11	12	22	14	14	22	14	11	09	14	11	11	11	11	08	14	11	11	11	11	14	11	11	09	11	12	
INTEGUMENTARY SYSTEM																											
Skin																											
Squamous cell papilloma	+	+	+	+	+	+	+	+	+	+	+	+	+	+	+	+	+	+	+	+	+	+	+	+	+	+	
Squamous cell carcinoma																											
Keratoacanthoma	X																										
Fibroma																											
Fibrosarcoma																											
Subcutaneous tissue																											
Squamous cell carcinoma, invasive	+	+	+	+	+	+	+	+	+	+	+	+	+	+	+	+	+	+	+	+	+	+	+	+	+	+	
Fibroma																											
Fibrosarcoma																											
Fibrous histiocytoma, malignant																											
Lipoma																											
Neurofibroma																											
Neurofibrosarcoma																											
RESPIRATORY SYSTEM																											
Lungs and bronchi																											
Papillary carcinoma, metastatic																											
Squamous cell carcinoma, metastatic																											
Adenocarcinoma, NOS, metastatic																											
Alveolar/bronchiolar adenoma																											
Alveolar/bronchiolar carcinoma																											
Follicular cell carcinoma, metastatic																											
C-cell carcinoma, metastatic																											
Pheochromocytoma, metastatic																											
Fibrosarcoma, metastatic																											
Osteosarcoma, metastatic																											
Trachea																											
Follicular cell carcinoma, invasive	+	+	+	+	+	+	+	+	+	+	+	+	+	+	+	+	+	+	+	+	+	+	+	+	+	+	
HEMATOPOIETIC SYSTEM																											
Bone marrow																											
	+	+	+	+	+	+	+	+	+	+	+	+	+	+	+	+	+	+	+	+	+	+	+	+	+	+	
Spleen																											
	+	+	+	+	+	+	+	+	+	+	+	+	+	+	+	+	+	+	+	+	+	+	+	+	+	+	
Lymph nodes																											
	+	+	+	+	+	+	+	+	+	+	+	+	+	+	+	+	+	+	+	+	+	+	+	+	+	+	
Carcinoma, NOS, metastatic																											
Neurofibrosarcoma, metastatic																											
Thymus																											
	+	+	+	+	+	+	+	+	+	+	+	+	+	+	+	+	+	+	+	+	+	+	+	+	+	+	
Carcinoma, NOS																											
CIRCULATORY SYSTEM																											
Heart																											
	+	+	+	+	+	+	+	+	+	+	+	+	+	+	+	+	+	+	+	+	+	+	+	+	+	+	
DIGESTIVE SYSTEM																											
Oral cavity																											
Squamous cell papilloma	N	N	N	N	N	N	N	N	N	N	N	N	N	N	N	N	N	N	N	N	N	N	N	N	N	N	
Squamous cell carcinoma																											
Squamous cell carcinoma, invasive																											
Salivary gland																											
Squamous cell carcinoma, invasive	+	+	+	+	+	+	+	+	+	+	+	+	+	+	+	+	+	+	+	+	+	+	+	+	+	+	
Sarcoma, NOS																											
Liver																											
Neoplastic nodule	+	+	+	+	+	+	+	+	+	+	+	+	+	+	+	+	+	+	+	+	+	+	+	+	+	+	
Bile duct																											
Gallbladder & common bile duct	N	N	N	N	N	N	N	N	N	N	N	N	N	N	N	N	N	N	N	N	N	N	N	N	N	N	
Pancreas	+	+	+	+	+	+	+	+	+	+	+	+	+	+	+	+	+	+	+	+	+	+	+	+	+	+	
Acinar cell adenoma																											
Esophagus																											
Follicular cell carcinoma, invasive	+	+	+	+	+	+	+	+	+	+	+	+	+	+	+	+	+	+	+	+	+	+	+	+	+	+	
Stomach																											
	+	+	+	+	+	+	+	+	+	+	+	+	+	+	+	+	+	+	+	+	+	+	+	+	+	+	
Small intestine																											
	+	+	+	+	+	+	+	+	+	+	+	+	+	+	+	+	+	+	+	+	+	+	+	+	+	+	
Fibroma																											
Leiomyosarcoma																											
Large intestine																											
Adenocarcinoma in adenomatous polyp	+	+	+	+	+	+	+	+	+	+	+	+	+	+	+	+	+	+	+	+	+	+	+	+	+	+	
URINARY SYSTEM																											
Kidney																											
Tubular cell adenoma	+	+	+	+	+	+	+	+	+	+	+	+	+	+	+	+	+	+	+	+	+	+	+	+	+	+	
Tubular cell adenocarcinoma																											
Mixed tumor, malignant																											
Urinary bladder																											
Transitional cell papilloma	+	+	+	+	+	+	+	+	+	+	+	+	+	+	+	+	+	+	+	+	+	+	+	+	+	+	

**TABLE B2. INDIVIDUAL ANIMAL TUMOR PATHOLOGY OF FEMALE RATS: 1% TREMOLITE
(Continued)**

ANIMAL NUMBER	3 8 2	3 8 3	3 8 4	3 8 5	3 8 6	3 8 7	3 8 8	3 8 8	3 8 9	3 8 0	3 8 1	3 8 2	3 8 3	3 8 3	3 8 4	3 8 5	3 8 6	3 8 7	3 8 8	3 8 9	3 8 0	3 8 1	3 8 2	3 8 3	3 8 4	3 8 5	3 8 6	3 8 7	3 8 8	3 8 9	3 8 0	3 8 1	3 8 2	3 8 3	3 8 4	3 8 5	3 8 6		
WEEKS ON STUDY	0 8 8	1 4 8	1 1 9	1 3 6	1 4 8	1 2 7	0 8 8	1 1 7	0 9 2	1 4 6	1 1 1	1 3 6	1 1 3	1 1 4	1 1 1	1 1 1	1 1 1	1 1 1	1 1 1	1 1 1	1 1 1	1 1 1	1 1 1	1 1 1	1 1 1	1 1 1	1 1 1	1 1 1	1 1 1	1 1 1	1 1 1	1 1 1	1 1 1	1 1 1	1 1 1	1 1 1	1 1 1	1 1 1	
INTEGUMENTARY SYSTEM																																							
Skin	+																																						
Squamous cell papilloma																																							
Squamous cell carcinoma																																							
Keratoacanthoma																																							
Fibroma																																							
Fibrosarcoma																																							
Subcutaneous tissue	+																																						
Squamous cell carcinoma, invasive																																							
Fibroma	X																																						
Fibrosarcoma																																							
Fibrous histiocytoma, malignant																																							
Lipoma																																							
Neurofibroma																																							
Neurofibrosarcoma																																							
RESPIRATORY SYSTEM																																							
Lungs and bronchi	+																																						
Papillary carcinoma, metastatic																																							
Squamous cell carcinoma, metastatic																																							
Adenocarcinoma, NOS, metastatic																																							
Alveolar/bronchiolar adenoma																																							
Alveolar/bronchiolar carcinoma																																							
Follicular cell carcinoma, metastatic																																							
C-cell carcinoma, metastatic																																							
Pheochromocytoma, metastatic	X																																						
Fibrosarcoma, metastatic																																							
Osteosarcoma, metastatic																																							
Trachea	+																																						
Follicular cell carcinoma, invasive																																							
HEMATOPOIETIC SYSTEM																																							
Bone marrow	+																																						
Spleen	+																																						
Lymph nodes	+																																						
Carcinoma, NOS, metastatic																																							
Neurofibrosarcoma, metastatic	X																																						
Thymus	+																																						
Carcinoma, NOS																																							
CIRCULATORY SYSTEM																																							
Heart	+																																						
DIGESTIVE SYSTEM																																							
Oral cavity	N																																						
Squamous cell papilloma	N																																						
Squamous cell carcinoma	N																																						
Squamous cell carcinoma, invasive	N																																						
Salivary gland	+																																						
Squamous cell carcinoma, invasive	+																																						
Sarcoma, NOS	+																																						
Liver	+																																						
Neoplastic nodule	+																																						
Bile duct	+																																						
Gallbladder & common bile duct	N																																						
Pancreas	N																																						
Acinar cell adenoma	+																																						
Esophagus	+																																						
Follicular cell carcinoma, invasive	+																																						
Stomach	+																																						
Small intestine	+																																						
Fibroma	+																																						
Leiomyosarcoma	+																																						
Large intestine	+																																						
Adenocarcinoma in adenomatous polyp	+																																						
URINARY SYSTEM																																							
Kidney	+																																						
Tubular cell adenoma	+																																						
Tubular cell adenocarcinoma	+																																						
Mixed tumor, malignant	+																																						
Urinary bladder	+																																						
Transitional cell papilloma	+																																						

**TABLE B2. INDIVIDUAL ANIMAL TUMOR PATHOLOGY OF FEMALE RATS: 1% TREMOLITE
(Continued)**

ANIMAL NUMBER	407	408	409	410	411	412	413	414	415	416	417	418	419	420	421	422	423	424	425	426	427	428	429	430	431	432	
WEEKS ON STUDY	148	140	143	142	144	141	145	146	147	149	150	151	152	153	154	155	156	157	158	159	160	161	162	163	164	165	
INTEGUMENTARY SYSTEM																											
Skin	+																										
Squamous cell papilloma																											
Squamous cell carcinoma																											
Keratoacanthoma																											
Fibroma																											
Fibrosarcoma																											
Subcutaneous tissue	+																										
Squamous cell carcinoma, invasive																											
Fibroma																											
Fibrosarcoma																											
Fibrous histiocytoma, malignant																											
Lipoma																											
Neurofibroma																											
Neurofibrosarcoma																											
RESPIRATORY SYSTEM																											
Lungs and bronchi	+																										
Papillary carcinoma, metastatic																											
Squamous cell carcinoma, metastatic																											
Adenocarcinoma, NOS, metastatic																											
Alveolar/bronchiolar adenoma																											
Alveolar/bronchiolar carcinoma																											
Follicular cell carcinoma, metastatic																											
C-cell carcinoma, metastatic																											
Pheochromocytoma, metastatic																											
Fibrosarcoma, metastatic																											
Osteosarcoma, metastatic																											
Trachea	+																										
Follicular cell carcinoma, invasive																											
HEMATOPOIETIC SYSTEM																											
Bone marrow	+																										
Spleen	+																										
Lymph nodes	+																										
Carcinoma, NOS, metastatic																											
Neurofibrosarcoma, metastatic																											
Thymus	+																										
Carcinoma, NOS																											
CIRCULATORY SYSTEM																											
Heart	+																										
DIGESTIVE SYSTEM																											
Oral cavity	N																										
Squamous cell papilloma	N																										
Squamous cell carcinoma	N																										
Squamous cell carcinoma, invasive	N																										
Salivary gland	+																										
Squamous cell carcinoma, invasive	+																										
Sarcoma, NOS	+																										
Liver	+																										
Neoplastic nodule																											
Bile duct	+																										
Gallbladder & common bile duct	+																										
Pancreas	N																										
Acinar cell adenoma	N																										
Esophagus	+																										
Follicular cell carcinoma, invasive	+																										
Stomach	+																										
Small intestine	+																										
Fibroma	+																										
Leiomyosarcoma	+																										
Large intestine	+																										
Adenocarcinoma in adenomatous polyp	+																										
URINARY SYSTEM																											
Kidney	+																										
Tubular cell adenoma	+																										
Tubular cell adenocarcinoma	+																										
Mixed tumor, malignant	+																										
Urinary bladder	+																										
Transitional cell papilloma	+																										

TABLE B2. INDIVIDUAL ANIMAL TUMOR PATHOLOGY OF FEMALE RATS: 1% TREMOLITE
(Continued)

ANIMAL NUMBER	457	458	459	460	461	462	463	464	465	466	467	468	469	470	471	472	473	474	475	476	477	478	479	480	
WEEKS ON STUDY	137	142	145	149	150	152	153	154	155	156	157	158	159	160	161	162	163	164	165	166	167	168	169	170	
INTEGUMENTARY SYSTEM																									
Skin	+	+	+	+	+	+	+	+	+	+	+	+	+	+	+	+	+	+	+	+	+	+	+	+	
Squamous cell papilloma																									
Squamous cell carcinoma																									
Keratoacanthoma																									
Fibroma																									
Fibrosarcoma																									
Subcutaneous tissue	+	+	+	+	+	+	+	+	+	+	+	+	+	+	+	+	+	+	+	+	+	+	+	+	
Squamous cell carcinoma, invasive																									
Fibroma																									
Fibrosarcoma																									
Fibrous histiocytoma, malignant																									
Lipoma																									
Neurofibroma																									
Neurofibrosarcoma																									
RESPIRATORY SYSTEM																									
Lungs and bronchi	+	+	+	+	+	+	+	+	+	+	+	+	+	+	+	+	+	+	+	+	+	+	+	+	
Papillary carcinoma, metastatic																									
Squamous cell carcinoma, metastatic																									
Adenocarcinoma, NOS, metastatic																									
Alveolar/bronchiolar adenoma																									
Alveolar/bronchiolar carcinoma																									
Follicular cell carcinoma, metastatic																									
C-cell carcinoma, metastatic																									
Phaeochromocytoma, metastatic																									
Fibrosarcoma, metastatic																									
Osteosarcoma, metastatic																									
Trachea	+	+	+	+	+	+	+	+	+	+	+	+	+	+	+	+	+	+	+	+	+	+	+	+	
Follicular cell carcinoma, invasive																									
HEMATOPOIETIC SYSTEM																									
Bone marrow	+	+	+	+	+	+	+	+	+	+	+	+	+	+	+	+	+	+	+	+	+	+	+	+	
Spleen	+	+	+	+	+	+	+	+	+	+	+	+	+	+	+	+	+	+	+	+	+	+	+	+	
Lymph nodes	+	+	+	+	+	+	+	+	+	+	+	+	+	+	+	+	+	+	+	+	+	+	+	+	
Carcinoma, NOS, metastatic																									
Neurofibrosarcoma, metastatic																									
Thymus	+	-	+	+	+	+	+	+	-	-	+	+	+	+	+	+	-	+	+	+	+	+	+	-	
Carcinoma, NOS																									
CIRCULATORY SYSTEM																									
Heart	+	+	+	+	+	+	+	+	+	+	+	+	+	+	+	+	+	+	+	+	+	+	+	+	
DIGESTIVE SYSTEM																									
Oral cavity	N	N	N	N	N	N	N	N	N	N	N	N	N	N	N	N	N	N	N	N	N	N	N	N	
Squamous cell papilloma																									
Squamous cell carcinoma																									
Squamous cell carcinoma, invasive																									
Salivary gland	+	+	+	+	+	+	+	+	+	+	+	+	+	+	+	+	+	+	+	+	+	+	+	+	
Squamous cell carcinoma, invasive																									
Sarcoma, NOS																									
Liver	+	+	+	+	+	+	+	+	+	+	+	+	+	+	+	+	+	+	+	+	+	+	+	+	
Neoplastic nodule																									
Bile duct	+	+	+	+	+	+	+	+	+	+	+	+	+	+	+	+	+	+	+	+	+	+	+	+	
Gallbladder & common bile duct	N	N	N	N	N	N	N	N	N	N	N	N	N	N	N	N	N	N	N	N	N	N	N	N	
Pancreas	+	+	+	+	+	+	+	+	+	+	+	+	+	+	+	+	+	+	+	+	+	+	+	+	
Acinar cell adenoma																									
Esophagus	+	+	+	+	+	+	+	+	+	+	+	+	+	+	+	+	+	+	+	+	+	+	+	+	
Follicular cell carcinoma, invasive																									
Stomach	+	+	+	+	+	+	+	+	+	+	+	+	+	+	+	+	+	+	+	+	+	+	+	+	
Small intestine	+	+	+	+	+	+	+	+	+	+	+	+	+	+	+	+	+	+	+	+	+	+	+	+	
Fibroma																									
Leiomyosarcoma																									
Large intestine	+	+	+	+	+	+	+	+	+	+	+	+	+	+	+	+	+	+	+	+	+	+	+	+	
Adenocarcinoma in adenomatous polyp																									
URINARY SYSTEM																									
Kidney	+	+	+	+	+	+	+	+	+	+	+	+	+	+	+	+	+	+	+	+	+	+	+	+	
Tubular cell adenoma																									
Tubular cell adenocarcinoma																									
Mixed tumor, malignant																									
Urinary bladder	+	+	+	+	+	+	+	+	+	+	+	+	+	+	+	+	+	+	+	+	+	+	+	+	
Transitional cell papilloma																									

**TABLE B2. INDIVIDUAL ANIMAL TUMOR PATHOLOGY OF FEMALE RATS: 1% TREMOLITE
(Continued)**

ANIMAL NUMBER	4	4	4	4	4	4	4	4	4	4	4	4	4	4	4	4	4	4	5	5	5	5	5	5	5		
	8	8	8	8	8	8	8	8	9	9	9	9	9	9	9	9	9	9	0	0	0	0	0	0	0		
WEEKS ON STUDY	1	1	1	1	1	0	0	1	1	1	0	1	1	1	1	1	1	1	1	1	1	1	1	1	1		
	3	4	2	3	0	9	8	2	0	0	9	1	3	1	1	3	4	2	3	4	3	4	2	0	4		
	2	8	0	1	4	5	6	7	1	7	1	3	2	6	9	0	7	8	9	0	1	2	3	4	5	6	
INTEGUMENTARY SYSTEM																											
Skin																											
Squamous cell papilloma	+	+	+	+	+	+	+	+	+	+	+	+	+	+	+	+	+	+	+	+	+	+	+	+	+	+	
Squamous cell carcinoma																											
Keratoacanthoma																											
Fibroma																											
Fibrosarcoma																											
Subcutaneous tissue																											
Squamous cell carcinoma, invasive	+	+	+	+	+	+	+	+	+	+	+	+	+	+	+	+	+	+	+	+	+	+	+	+	+	+	
Fibroma																											
Fibrosarcoma																											
Fibrous histiocytoma, malignant																											
Lipoma																											
Neurofibroma																											
Neurofibrosarcoma																											
RESPIRATORY SYSTEM																											
Lungs and bronchi																											
Papillary carcinoma, metastatic	+	+	+	+	+	+	+	+	+	+	+	+	+	+	+	+	+	+	+	+	+	+	+	+	+	+	
Squamous cell carcinoma, metastatic																											
Adenocarcinoma, NOS, metastatic																											
Alveolar/bronchiolar adenoma																											
Alveolar/bronchiolar carcinoma																											
Follicular cell carcinoma, metastatic																											
C-cell carcinoma, metastatic																											
Pheochromocytoma, metastatic																											
Fibrosarcoma, metastatic																											
Osteosarcoma, metastatic																											
Trachea																											
Follicular cell carcinoma, invasive	+	+	+	+	+	+	+	+	+	+	+	+	+	+	+	+	+	+	+	+	+	+	+	+	+	+	
HEMATOPOIETIC SYSTEM																											
Bone marrow																											
Spleen	+	+	+	+	+	+	+	+	+	+	+	+	+	+	+	+	+	+	+	+	+	+	+	+	+	+	
Lymph nodes	+	+	+	+	+	+	+	+	+	+	+	+	+	+	+	+	+	+	+	+	+	+	+	+	+	+	
Carcinoma, NOS, metastatic																											
Neurofibrosarcoma, metastatic																											
Thymus	+	-	+	+	+	+	+	+	-	+	+	-	+	+	+	+	-	+	+	+	+	+	-	+	-		
Carcinoma, NOS																											
CIRCULATORY SYSTEM																											
Heart																											
+	+	+	+	+	+	+	+	+	+	+	+	+	+	+	+	+	+	+	+	+	+	+	+	+	+	+	
DIGESTIVE SYSTEM																											
Oral cavity																											
Squamous cell papilloma	N	N	N	N	N	N	N	N	N	N	N	N	N	N	N	N	N	N	N	N	N	N	N	N	N	N	
Squamous cell carcinoma																											
Squamous cell carcinoma, invasive																											
Salivary gland																											
Squamous cell carcinoma, invasive	+	+	+	+	+	+	+	+	+	+	+	+	+	+	+	+	+	+	+	+	+	+	+	+	+	+	
Sarcoma, NOS																											
Liver																											
Neoplastic nodule																											
Bile duct																											
Gallbladder & common bile duct	N	N	N	N	N	N	N	N	N	N	N	N	N	N	N	N	N	N	N	N	N	N	N	N	N	N	
Pancreas	+	+	+	+	+	+	+	+	+	+	+	+	+	+	+	+	+	+	+	+	+	+	+	+	+	+	
Acinar cell adenoma																											
Esophagus	+	+	+	+	+	+	+	+	+	+	+	+	+	+	+	+	+	+	+	+	+	+	+	+	+	+	
Follicular cell carcinoma, invasive																											
Stomach	+	+	+	+	+	+	+	+	+	+	+	+	+	+	+	+	+	+	+	+	+	+	+	+	+	+	
Small intestine	+	+	+	+	+	+	+	+	+	+	+	+	+	+	+	+	+	+	+	+	+	+	+	+	+	+	
Fibroma																											
Leiomyosarcoma																											
Large intestine	+	+	+	+	+	+	+	+	+	+	+	+	+	+	+	+	+	+	+	+	+	+	+	+	+	+	
Adenocarcinoma in adenomatous polyp																											
URINARY SYSTEM																											
Kidney																											
Tubular cell adenoma																											
Tubular cell adenocarcinoma																											
Mixed tumor, malignant																											
Urinary bladder	+	+	+	+	+	+	+	+	+	+	+	+	+	+	+	+	+	+	+	+	+	+	+	+	+	+	
Transitional cell papilloma																											

TABLE B2. INDIVIDUAL ANIMAL TUMOR PATHOLOGY OF FEMALE RATS: 1% TREMOLITE (Continued)

ANIMAL NUMBER	282	283	284	285	286	287	288	289	290	291	292	293	294	295	296	297	298	299	300	301	302	303	304	305	306		
WEEKS ON STUDY	109	118	106	114	103	112	102	111	100	109	118	107	116	105	114	104	113	103	112	101	110	100	109	118	107	116	
ENDOCRINE SYSTEM																											
Pituitary	+	+	+	+	+	+	+	+	+	+	+	+	+	+	+	+	+	+	+	+	+	+	+	+	+	+	
Carcinoma, NOS																											
Adenoma, NOS					X	X	X	X				X	X							X					X		
Adrenal	+	+	+	+	+	+	+	+	+	+	+	+	+	+	+	+	+	+	+	+	+	+	+	+	+	+	
Cortical adenoma																											
Pheochromocytoma																											
Pheochromocytoma, malignant					X				X																		
Ganglioneuroma																											
Thyroid	+	+	+	+	+	+	+	+	+	+	+	+	+	+	+	+	+	+	+	+	+	+	+	+	+	+	
Follicular cell adenoma																											
Follicular cell carcinoma	X					X	X				X												X				
C-cell adenoma																											
C-cell carcinoma					X					X												X					
Parathyroid	+	+	+	+	+	+	+	+	+	+	+	+	+	+	+	+	+	+	+	+	+	+	+	+	+	+	
Pancreatic islets	+	+	+	+	+	+	+	+	+	+	+	+	+	+	+	+	+	+	+	+	+	+	+	+	+	+	
Islet cell adenoma																											
Islet cell carcinoma																											
REPRODUCTIVE SYSTEM																											
Mammary gland	+	+	+	+	+	+	+	+	+	+	+	+	+	+	+	+	+	+	+	+	+	+	+	+	+	+	
Carcinoma, NOS																											
Adenoma, NOS																											
Adenocarcinoma, NOS																										X	
Papillary adenocarcinoma																											
Fibroadenoma					X	X	X				X	X	X	X	X	X			X		X	X	X				
Neurofibroma																											
Preputial/clitoral gland	N	N	N	N	N	N	N	N	N	N	N	N	N	N	N	N	N	N	N	N	N	N	N	N	N	N	
Carcinoma, NOS																											
Squamous cell papilloma																											
Squamous cell carcinoma													X										X				
Keratoacanthoma																											
Uterus	+	+	+	+	+	+	+	+	+	+	+	+	+	+	+	+	+	+	+	+	+	+	+	+	+	+	
Papillary carcinoma																											
Papillary adenocarcinoma																							X				
Fibrosarcoma																											
Endometrial stromal polyp	X			X				X						X												X	
Endometrial stromal sarcoma																											
Endometrial stromal sarcoma, invasive																											
Ovary	+	+	+	+	+	+	+	+	+	+	+	+	+	+	+	+	+	+	+	+	+	+	+	+	+	+	
Granulosa cell tumor																											
Granulosa cell carcinoma																											
NERVOUS SYSTEM																											
Brain	+	+	+	+	+	+	+	+	+	+	+	+	+	+	+	+	+	+	+	+	+	+	+	+	+	+	
Carcinoma, NOS, invasive																											
Glioma, NOS																											
Astrocytoma																											
Spinal cord	N	N	N	N	N	N	N	N	N	N	N	N	N	N	N	N	N	N	N	N	N	N	N	N	N	N	
Osteosarcoma, invasive																											
SPECIAL SENSE ORGANS																											
Zymbal gland	+	+	+	+	+	+	+	+	+	+	+	+	+	+	+	+	+	+	+	+	+	+	+	+	+	+	
Carcinoma in-situ, NOS																											
Squamous cell papilloma																											
Squamous cell carcinoma																											
MUSCULOSKELETAL SYSTEM																											
Bone	N	N	N	N	N	N	N	N	N	N	N	N	N	N	N	N	N	N	N	N	N	N	N	N	N	N	
Squamous cell carcinoma, invasive																											
Osteosarcoma																											
BODY CAVITIES																											
Mesentery	N	N	N	N	N	N	N	N	N	N	N	N	N	N	N	N	N	N	N	N	N	N	N	N	N	N	
Hemangiosarcoma																											
ALL OTHER SYSTEMS																											
Multiple organs, NOS	N	N	N	N	N	N	N	N	N	N	N	N	N	N	N	N	N	N	N	N	N	N	N	N	N	N	
Carcinoma, NOS, invasive																											
Adenocarcinoma, NOS, metastatic																											
C-cell carcinoma, metastatic																											
Granulosa cell carcinoma, metastatic																											
Hemangiosarcoma, invasive																											
Malignant lymphoma, NOS																											
Myelomonocytic leukemia																											
Monocytic leukemia	X						X								X	X	X	X	X	X				X	X		
Pituitary fossa																											
Carcinoma, NOS, invasive																											

**TABLE B2. INDIVIDUAL ANIMAL TUMOR PATHOLOGY OF FEMALE RATS: 1% TREMOLITE
(Continued)**

ANIMAL NUMBER	307	308	309	310	311	312	313	314	315	316	317	318	319	320	321	322	323	324	325	326	327	328	329	330			
WEEKS ON STUDY	1	2	1	4	2	1	4	9	4	3	4	3	1	2	3	0	2	1	3	1	0	9	4	1	3		
	3	3	2	5	9	4	8	1	8	3	8	7	9	8	6	0	8	4	2	1	5	5	8	3	3		
ENDOCRINE SYSTEM																											
Pituitary	+	+	+	+	+	+	+	+	+	+	+	+	+	+	+	+	+	+	+	+	+	+	+	+	+	+	
Carcinoma, NOS			X																	X							
Adenoma, NOS	X				X			X	X		X	X		X	X		X				X	X	X		X		
Adrenal	+	+	+	+	+	+	+	+	+	+	+	+	+	+	+	+	+	+	+	+	+	+	+	+	+	+	
Cortical adenoma				X																							
Pheochromocytoma				X					X																		
Pheochromocytoma, malignant															X												
Ganglioglioma																											
Thyroid	+	+	+	+	+	+	+	+	+	+	+	+	+	+	+	+	+	+	+	+	+	+	+	+	+	+	
Follicular cell adenoma																											
Follicular cell carcinoma				X																							
C-cell adenoma																							X				
C-cell carcinoma		X			X						X																
Parathyroid	+	+	+	+	+	+	+	+	+	+	+	+	+	+	+	+	+	+	+	+	+	+	+	+	+	+	
Pancreatic islets	+	+	+	+	+	+	+	+	+	+	+	+	+	+	+	+	+	+	+	+	+	+	+	+	+	+	
Islet cell adenoma											X																
Islet cell carcinoma												X															
REPRODUCTIVE SYSTEM																											
Mammary gland	+	+	+	+	+	+	+	+	+	+	+	+	+	+	+	+	+	+	+	+	+	+	+	+	+	+	
Carcinoma, NOS																											
Adenoma, NOS																											
Adenocarcinoma, NOS										X																	
Papillary adenocarcinoma																											
Fibroadenoma				X		X		X			X	X	X		X	X		X					X			X	
Neurofibroma																											
Preputial/clitoral gland	N	N	N	N	N	N	N	N	N	N	N	N	N	N	N	N	N	N	N	N	N	N	N	N	N	N	
Carcinoma, NOS																											
Squamous cell papilloma																											
Squamous cell carcinoma																											
Keratoacanthoma																											
Uterus	+	+	+	+	+	+	+	+	+	+	+	+	+	+	+	+	+	+	+	+	+	+	+	+	+	+	
Papillary carcinoma																											
Papillary adenocarcinoma															X												
Fibrosarcoma																											
Endometrial stromal polyp																											
Endometrial stromal sarcoma																						X			X		
Endometrial stromal sarcoma, invasive																											
Ovary	+	+	+	+	+	+	+	+	+	+	+	+	+	+	+	+	+	+	+	+	+	+	+	+	+	+	
Granulosa cell tumor																											
Granulosa cell carcinoma																											
NERVOUS SYSTEM																											
Brain	+	+	+	+	+	+	+	+	+	+	+	+	+	+	+	+	+	+	+	+	+	+	+	+	+	+	
Carcinoma, NOS, invasive																											
Glioma, NOS																											
Astrocytoma																											
Spinal cord	N	N	N	N	N	N	N	N	N	N	N	N	N	N	N	N	N	N	N	N	N	N	N	N	N	N	
Osteosarcoma, invasive																											
SPECIAL SENSE ORGANS																											
Zymbal gland	+	+	+	+	+	+	+	+	+	+	+	+	+	+	+	+	+	+	+	+	+	+	+	+	+	+	
Carcinoma in-situ, NOS																											
Squamous cell papilloma																											
Squamous cell carcinoma																											
MUSCULOSKELETAL SYSTEM																											
Bone	N	N	N	N	N	N	N	N	N	N	N	N	N	N	N	N	N	N	N	N	N	N	N	N	N	N	
Squamous cell carcinoma, invasive																											
Osteosarcoma																											
BODY CAVITIES																											
Mesentery	N	N	N	N	N	N	N	N	N	N	N	N	N	N	N	N	N	N	N	N	N	N	N	N	N	N	
Hemangiosarcoma																											
ALL OTHER SYSTEMS																											
Multiple organs, NOS	N	N	N	N	N	N	N	N	N	N	N	N	N	N	N	N	N	N	N	N	N	N	N	N	N	N	
Carcinoma, NOS, invasive																											
Adenocarcinoma, NOS, metastatic																											
C-cell carcinoma, metastatic																											
Granulosa cell carcinoma, metastatic																											
Hemangiosarcoma, invasive																											
Malignant lymphoma, NOS																											
Myelomonocytic leukemia																											
Monocytic leukemia	X			X		X	X				X	X	X				X		X					X		X	
Pituitary fossa																											
Carcinoma, NOS, invasive																											

**TABLE B2. INDIVIDUAL ANIMAL TUMOR PATHOLOGY OF FEMALE RATS: 1% TREMOLITE
(Continued)**

ANIMAL NUMBER	407	408	409	410	411	412	413	414	415	416	417	418	419	420	421	422	423	424	425	426	427	428	429	430	
WEEKS ON STUDY	148	141	143	142	144	145	146	147	148	149	150	151	152	153	154	155	156	157	158	159	160	161	162	163	
ENDOCRINE SYSTEM																									
Pituitary																									
Carcinoma, NOS	+	+	+	+	+	+	+	+	+	+	+	+	+	+	+	+	+	+	+	+	+	+	+	+	
Adenoma, NOS									X																
Adrenal																									
Cortical adenoma	+	+	+	+	+	+	+	+	+	+	+	+	+	+	+	+	+	+	+	+	+	+	+	+	
Pheochromocytoma										X															
Pheochromocytoma, malignant														X	X						X				
Ganglioneuroma																									
Thyroid																									
Follicular cell adenoma	+	+	+	+	+	+	+	+	+	+	+	+	+	+	+	+	+	+	+	+	+	+	+	+	
Follicular cell carcinoma											X														
C-cell adenoma																									
C-cell carcinoma	X					X				X												X			
Parathyroid																									
Islet cell adenoma	+	+	+	+	+	+	+	+	+	+	+	+	+	+	+	+	+	+	+	+	+	+	+	+	
Islet cell carcinoma							X																		
REPRODUCTIVE SYSTEM																									
Mammary gland																									
Carcinoma, NOS	+	+	+	+	+	+	+	+	+	+	+	+	+	+	+	+	+	+	+	+	+	+	+	+	
Adenoma, NOS																									
Adenocarcinoma, NOS										X	X				X			X	X						
Papillary adenocarcinoma																									
Fibroadenoma	X			X	X	X		X	X	X	X			X	X	X					X	X	X	X	
Neurofibroma																									
Preputial/clitoral gland																									
Carcinoma, NOS	N	N	N	N	N	N	N	N	N	N	N	N	N	N	N	N	N	N	N	N	N	N	N	N	
Squamous cell papilloma																									
Squamous cell carcinoma																								X	
Keratoacanthoma																									
Uterus																									
Papillary carcinoma	+	+	+	+	+	+	+	+	+	+	+	+	+	+	+	+	+	+	+	+	+	+	+	+	
Papillary adenocarcinoma																									
Fibrosarcoma																									
Endometrial stromal polyp										X	X														
Endometrial stromal sarcoma																									
Endometrial stromal sarcoma, invasive																									
Ovary																									
Granulosa cell tumor	+	+	+	+	+	+	+	+	+	+	+	+	+	+	+	+	+	+	+	+	+	+	+	+	
Granulosa cell carcinoma																							X		
NERVOUS SYSTEM																									
Brain																									
Carcinoma, NOS, invasive	+	+	+	+	+	+	+	+	+	+	+	+	+	+	+	+	+	+	+	+	+	+	+	+	
Glioma, NOS										X															
Astrocytoma																									
Spinal cord																									
Osteosarcoma, invasive	N	N	N	N	N	N	N	N	N	N	N	N	N	N	N	N	N	N	N	N	N	N	N	N	
SPECIAL SENSE ORGANS																									
Zymbal gland																									
Carcinoma in-situ, NOS	+	+	+	+	+	+	+	+	+	+	+	+	+	+	+	+	+	+	+	+	+	+	+	+	
Squamous cell papilloma	X																								
Squamous cell carcinoma										X															
MUSCULOSKELETAL SYSTEM																									
Bone																									
Squamous cell carcinoma, invasive	N	N	N	N	N	N	N	N	N	N	N	N	N	N	N	N	N	N	N	N	N	N	N	N	
Osteosarcoma																									
BODY CAVITIES																									
Mesentery																									
Hemangiosarcoma	N	N	N	N	N	N	N	N	N	N	N	N	N	N	N	N	N	N	N	N	N	N	N	N	
ALL OTHER SYSTEMS																									
Multiple organs, NOS																									
Carcinoma, NOS, invasive	N	N	N	N	N	N	N	N	N	N	N	N	N	N	N	N	N	N	N	N	N	N	N	N	
Adenocarcinoma, NOS, metastatic										X															
C-cell carcinoma, metastatic																									
Granulosa cell carcinoma, metastatic																									
Hemangiosarcoma, invasive																									
Malignant lymphoma, NOS																									
Myelomonocytic leukemia																									
Monocytic leukemia																									
Pituitary fossa																									
Carcinoma, NOS, invasive					X					X	X			X							X	X	X		

**TABLE B2. INDIVIDUAL ANIMAL TUMOR PATHOLOGY OF FEMALE RATS: 1% TREMOLITE
(Continued)**

ANIMAL NUMBER	4/2	4/3	4/4	4/5	4/6	4/7	4/8	4/9	4/0	4/1	4/2	4/3	4/4	4/5	4/6	4/7	4/8	4/9	4/0	4/1	4/2	4/3	4/4	4/5	4/6	4/7	4/8	4/9
WEEKS ON STUDY	1/9	1/3	1/2	1/9	1/2	1/8	1/1	1/9	1/0	1/9	1/7	1/8	1/8	1/0	1/8	1/6	1/9	1/9	1/1	1/1	1/3	1/2	1/6	1/9	1/0	1/7	1/3	1/8
ENDOCRINE SYSTEM																												
Pituitary	+	+	+	+	+	+	+	+	+	+	+	+	+	+	+	+	+	+	+	+	+	+	+	+	+	+	+	+
Carcinoma, NOS																												
Adenoma, NOS			X		X							X	X														X	
Adrenal	+	+	+	+	+	+	+	+	+	+	+	+	+	+	+	+	+	+	+	+	+	+	+	+	+	+	+	+
Cortical adenoma																												
Pheochromocytoma									X																			
Pheochromocytoma, malignant												X											X					
Ganglioneuroma																												
Thyroid	+	+	+	+	+	+	+	+	+	+	+	+	+	+	+	+	+	+	+	+	+	+	+	+	+	+	+	+
Follicular cell adenoma																												
Follicular cell carcinoma		X																										
C-cell adenoma										X																		
C-cell carcinoma																												
Parathyroid	+	+	+	+	+	+	+	+	+	+	+	+	+	+	+	+	+	+	+	+	+	+	+	+	+	+	+	+
Pancreatic islets	+	+	+	+	+	+	+	+	+	+	+	+	+	+	+	+	+	+	+	+	+	+	+	+	+	+	+	+
Islet cell adenoma																												
Islet cell carcinoma										X																		
REPRODUCTIVE SYSTEM																												
Mammary gland	+	+	+	+	+	+	+	+	+	+	+	+	+	+	+	+	+	+	+	+	+	+	+	+	+	+	+	+
Carcinoma, NOS																												
Adenoma, NOS																												
Adenocarcinoma, NOS				X							X		X															X
Papillary adenocarcinoma																												
Fibroadenoma	X	X			X		X		X	X		X		X	X	X							X	X	X			
Neurofibroma																												
Preputial/clitoral gland	N	N	N	N	N	N	N	N	N	N	N	N	N	N	N	N	N	N	N	N	N	N	N	N	N	N	N	N
Carcinoma, NOS																												
Squamous cell papilloma																												
Squamous cell carcinoma																									X		X	
Keratocanthoma																												
Uterus	+	+	+	+	+	+	+	+	+	+	+	+	+	+	+	+	+	+	+	+	+	+	+	+	+	+	+	+
Papillary carcinoma																												
Papillary adenocarcinoma	X																											
Fibrosarcoma																												
Endometrial stromal polyp																												
Endometrial stromal sarcoma																												
Endometrial stromal sarcoma, invasive																												
Ovary	+	+	+	+	+	+	+	+	+	+	+	+	+	+	+	+	+	+	+	+	+	+	+	+	+	+	+	+
Granulosa cell tumor																												
Granulosa cell carcinoma																												
NERVOUS SYSTEM																												
Brain	+	+	+	+	+	+	+	+	+	+	+	+	+	+	+	+	+	+	+	+	+	+	+	+	+	+	+	+
Carcinoma, NOS, invasive																												
Glioma, NOS																												
Astrocytoma																												
Spinal cord	N	N	N	N	N	N	N	N	N	N	N	N	N	N	N	N	N	N	N	N	N	N	N	N	N	N	N	N
Osteosarcoma, invasive																												
SPECIAL SENSE ORGANS																												
Zymbal gland	+	+	+	+	+	+	+	+	+	+	+	+	+	+	+	+	+	+	+	+	+	+	+	+	+	+	+	+
Carcinoma in-situ, NOS																												
Squamous cell papilloma																												
Squamous cell carcinoma																												
MUSCULOSKELETAL SYSTEM																												
Bone	N	N	N	N	N	N	N	N	N	N	N	N	N	N	N	N	N	N	N	N	N	N	N	N	N	N	N	N
Squamous cell carcinoma, invasive																												
Osteosarcoma																												
BODY CAVITIES																												
Mesentery	N	N	N	N	N	N	N	N	N	N	N	N	N	N	N	N	N	N	N	N	N	N	N	N	N	N	N	N
Hemangiosarcoma																												
ALL OTHER SYSTEMS																												
Multiple organs, NOS	N	N	N	N	N	N	N	N	N	N	N	N	N	N	N	N	N	N	N	N	N	N	N	N	N	N	N	N
Carcinoma, NOS, invasive																												
Adenocarcinoma, NOS, metastatic																												
C-cell carcinoma, metastatic																												
Granulosa cell carcinoma, metastatic																												
Hemangiosarcoma, invasive																												
Malignant lymphoma, NOS																												
Myelomonocytic leukemia																												
Monocytic leukemia																												
Pituitary fossa																												
Carcinoma, NOS, invasive																												

**TABLE B2. INDIVIDUAL ANIMAL TUMOR PATHOLOGY OF FEMALE RATS: 1% TREMOLITE
(Continued)**

ANIMAL NUMBER	457	458	459	460	461	462	463	464	465	466	467	468	469	470	471	472	473	474	475	476	477	478	479	480	481		
WEEKS ON STUDY	37	42	45	19	01	12	02	11	13	04	44	48	48	88	73	12	22	22	33	33	22	22	33	11	33	01	
ENDOCRINE SYSTEM																											
Pituitary	+	+	+	+	+	+	+	+	+	+	+	+	+	+	+	+	+	+	+	+	+	+	+	+	+	+	
Carcinoma, NOS																									X	+	
Adenoma, NOS				X	X	X	X	X	X	X	X	X	X	X	X	X	X	X	X	X	X	X	X	X	X	X	
Adrenal	+	+	+	+	+	+	+	+	+	+	+	+	+	+	+	+	+	+	+	+	+	+	+	+	+	+	
Cortical adenoma																											
Pheochromocytoma			X																								
Pheochromocytoma, malignant																											
Ganglioneuroma																											
Thyroid	+	+	+	+	+	+	+	+	+	+	+	+	+	+	+	+	+	+	+	+	+	+	+	+	+	+	
Follicular cell adenoma																											
Follicular cell carcinoma																											
C-cell adenoma																											
C-cell carcinoma																											
Parathyroid	+	+	+	+	+	+	+	+	+	+	+	+	+	+	+	+	+	+	+	+	+	+	+	+	+	+	
Pituitary			X	X				X						X										X		X	
Pancreatic islets	+	+	+	+	+	+	+	+	+	+	+	+	+	+	+	+	+	+	+	+	+	+	+	+	+	+	
Islet cell adenoma																											
Islet cell carcinoma			X																								
REPRODUCTIVE SYSTEM																											
Mammary gland	+	+	+	+	+	+	+	+	+	+	+	+	+	+	+	+	+	+	+	+	+	+	+	+	+	+	
Carcinoma, NOS																											
Adenoma, NOS																											
Adenocarcinoma, NOS																											
Papillary adenocarcinoma																											
Fibroadenoma																											
Neurofibroma	X	X				X		X				X	X		X	X	X	X	X	X	X	X	X	X	X		
Preputial/clitoral gland	N	N	N	N	N	N	N	N	N	N	N	N	N	N	N	N	N	N	N	N	N	N	N	N	N	N	
Carcinoma, NOS																											
Squamous cell papilloma																											
Squamous cell carcinoma																											
Keratoacanthoma																											
Uterus	+	+	+	+	+	+	+	+	+	+	+	+	+	+	+	+	+	+	+	+	+	+	+	+	+	+	
Papillary carcinoma																											
Papillary adenocarcinoma																											
Fibrosarcoma																											
Endometrial stromal polyp																											
Endometrial stromal sarcoma																											
Endometrial stromal sarcoma, invasive																											
Ovary	+	+	+	+	+	+	+	+	+	+	+	+	+	+	+	+	+	+	+	+	+	+	+	+	+	+	
Granulosa cell tumor																											
Granulosa cell carcinoma																											
NERVOUS SYSTEM																											
Brain	+	+	+	+	+	+	+	+	+	+	+	+	+	+	+	+	+	+	+	+	+	+	+	+	+	+	
Carcinoma, NOS, invasive																											
Glioma, NOS																											
Astrocytoma																											
Spinal cord	+	N	N	N	N	N	N	N	N	N	N	N	N	N	N	N	N	N	N	N	N	N	N	N	N	N	
Osteosarcoma, invasive																											
SPECIAL SENSE ORGANS																											
Zymbal gland	+	+	+	+	+	+	+	+	+	+	+	+	+	+	+	+	+	+	+	+	+	+	+	+	+	+	
Carcinoma in-situ, NOS																											
Squamous cell papilloma																											
Squamous cell carcinoma																											
MUSCULOSKELETAL SYSTEM																											
Bone	N	N	N	N	N	N	N	N	N	N	N	N	N	N	N	N	N	N	N	N	N	N	N	N	N	N	
Squamous cell carcinoma, invasive																											
Osteosarcoma																											
BODY CAVITIES																											
Mesentery	N	N	N	N	N	N	N	N	N	N	N	N	N	N	N	N	N	N	N	N	N	N	N	N	N	N	
Hemangiosarcoma																											
ALL OTHER SYSTEMS																											
Multiple organs, NOS	N	N	N	N	N	N	N	N	N	N	N	N	N	N	N	N	N	N	N	N	N	N	N	N	N	N	
Carcinoma, NOS, invasive																											
Adenocarcinoma, NOS, metastatic																											
C-cell carcinoma, metastatic																											
Granulosa cell carcinoma, metastatic																											
Hemangiosarcoma, invasive																											
Malignant lymphoma, NOS																											
Myelomonocytic leukemia																											
Monocytic leukemia																											
Pituitary fossa																											
Carcinoma, NOS, invasive				X			X		X	X			X	X						X				X	X	X	

**TABLE B2. INDIVIDUAL ANIMAL TUMOR PATHOLOGY OF FEMALE RATS: 1% TREMOLITE
(Continued)**

ANIMAL NUMBER	4		4		4		4		4		4		4		4		4		5		5		5		5		5		5		
	8	8	8	8	8	8	8	8	9	9	9	9	9	9	9	9	9	9	0	0	0	0	0	0	0	0	0	0	0	0	
WEEKS ON STUDY	1		1		1		1		1		1		1		1		1		1		1		1		1		1		1		
	3	4	2	3	0	9	8	2	0	0	9	1	3	1	1	3	4	2	3	4	3	4	2	0	4	0	4	0	4	0	
ENDOCRINE SYSTEM																															
Pituitary	+	+	+	+	+	+	+	+	+	+	+	+	+	+	+	+	+	+	+	+	+	+	+	+	+	+	+	+	+	+	
Carcinoma, NOS								X			X																				
Adenoma, NOS		X	X		X			X					X	X	X		X	X												X	
Adrenal	+	+	+	+	+	+	+	+	+	+	+	+	+	+	+	+	+	+	+	+	+	+	+	+	+	+	+	+	+	+	
Cortical adenoma																															
Pheochromocytoma																															
Pheochromocytoma, malignant			X	X																											
Ganglioneuroma																															
Thyroid	+	+	+	+	+	+	+	+	+	+	+	+	+	+	+	+	+	+	+	+	+	+	+	+	+	+	+	+	+	+	
Follicular cell adenoma																															
Follicular cell carcinoma																															
C-cell adenoma				X																											
C-cell carcinoma	X	X		X				X	X																						
Parathyroid	+	+	+	+	+	+	+	+	+	+	+	+	+	+	+	+	+	+	+	+	+	+	+	+	+	+	+	+	+	+	
Pancreatic islets	+	+	+	+	+	+	+	+	+	+	+	+	+	+	+	+	+	+	+	+	+	+	+	+	+	+	+	+	+	+	
Islet cell adenoma	X			X				X																							
Islet cell carcinoma																															
REPRODUCTIVE SYSTEM																															
Mammary gland	+	+	+	+	+	+	+	+	+	+	+	+	+	+	+	+	+	+	+	+	+	+	+	+	+	+	+	+	+	+	
Carcinoma, NOS																															
Adenoma, NOS	X																														
Adenocarcinoma, NOS																															
Papillary adenocarcinoma																															
Fibroadenoma			X																												
Neurofibroma								X	X				X	X																	
Preputial/clitoral gland	N	N	N	N	N	N	N	N	N	N	N	N	N	N	N	N	N	N	N	N	N	N	N	N	N	N	N	N	N	N	
Carcinoma, NOS																															
Squamous cell papilloma																															
Squamous cell carcinoma																															
Keratoacanthoma																															
Uterus	+	+	+	+	+	+	+	+	+	+	+	+	+	+	+	+	+	+	+	+	+	+	+	+	+	+	+	+	+	+	
Papillary carcinoma																															
Papillary adenocarcinoma																															
Fibrosarcoma																															
Endometrial stromal polyp																															
Endometrial stromal sarcoma																															
Endometrial stromal sarcoma, invasive																															
Ovary	+	+	+	+	+	+	+	+	+	+	+	+	+	+	+	+	+	+	+	+	+	+	+	+	+	+	+	+	+	+	
Granulosa cell tumor																															
Granulosa cell carcinoma																															
NERVOUS SYSTEM																															
Brain	+	+	+	+	+	+	+	+	+	+	+	+	+	+	+	+	+	+	+	+	+	+	+	+	+	+	+	+	+	+	
Carcinoma, NOS, invasive																															
Glioma, NOS																															
Astrocytoma																															
Spinal cord	N	N	N	N	N	N	N	N	N	N	N	N	N	N	N	N	N	N	N	N	N	N	N	N	N	N	N	N	N	N	
Osteosarcoma, invasive																															
SPECIAL SENSE ORGANS																															
Zymbal gland	+	+	+	+	+	+	+	+	+	+	+	+	+	+	+	+	+	+	+	+	+	+	+	+	+	+	+	+	+	+	
Carcinoma in-situ, NOS																															
Squamous cell papilloma																															
Squamous cell carcinoma																															
MUSCULOSKELETAL SYSTEM																															
Bone	N	N	N	N	N	N	N	N	N	N	N	N	N	N	N	N	N	N	N	N	N	N	N	N	N	N	N	N	N	N	
Squamous cell carcinoma, invasive																															
Osteosarcoma																															
BODY CAVITIES																															
Mesentery	N	N	N	N	N	N	N	N	N	N	N	N	N	N	N	N	N	N	N	N	N	N	N	N	N	N	N	N	N	N	
Hemangiosarcoma																															
ALL OTHER SYSTEMS																															
Multiple organs, NOS	N	N	N	N	N	N	N	N	N	N	N	N	N	N	N	N	N	N	N	N	N	N	N	N	N	N	N	N	N	N	
Carcinoma, NOS, invasive																															
Adenocarcinoma, NOS, metastatic																															
C-cell carcinoma, metastatic																															
Granulosa cell carcinoma, metastatic																															
Hemangiosarcoma, invasive																															
Malignant lymphoma, NOS																															
Myelomonocytic leukemia																															
Monocytic leukemia	X																														
Pituitary fossa																															
Carcinoma, NOS, invasive																															

TABLE B2. INDIVIDUAL ANIMAL TUMOR PATHOLOGY OF FEMALE RATS: 1% TREMOLITE (Continued)

ANIMAL NUMBER	WEEKS ON STUDY																				TOTAL TISSUES TUMORS
	1	0	1	1	1	1	0	0	0	1	1	1	1	1	1	1	1	1	1	1	
ENDOCRINE SYSTEM																					
Pituitary	+	+	+	+	+	+	+	+	+	+	+	+	+	+	+	+	+	+	+	+	
Carcinoma, NOS				X																	
Adenoma, NOS	X			X	X					X	X								X	X	
Adrenal	+	+	+	+	+	+	+	+	+	+	+	+	+	+	+	+	+	+	+	+	
Cortical adenoma						X															
Pheochromocytoma	X									X									X	X	
Pheochromocytoma, malignant																					
Ganglioneuroma																	X				
Thyroid	+	+	+	+	+	+	+	+	+	+	+	+	+	+	+	+	+	+	+	+	
Follicular cell adenoma																					
Follicular cell carcinoma	X		X																		
C-cell adenoma																					
C-cell carcinoma																					
Parathyroid	+	+	+	+	+	+	+	+	+	+	+	+	+	+	+	+	+	+	+	+	
Pancreatic islets	+	+	+	+	+	+	+	+	+	+	+	+	+	+	+	+	+	+	+	+	
Islet cell adenoma																					
Islet cell carcinoma																					
REPRODUCTIVE SYSTEM																					
Mammary gland	+	+	+	+	+	+	+	+	+	+	+	+	+	+	+	+	+	+	+	+	
Carcinoma, NOS																					
Adenoma, NOS																					
Adenocarcinoma, NOS																			X		
Papillary adenocarcinoma																					
Fibroadenoma	X		X	X	X							X	X	X				X	X	X	
Neurofibroma																					
Preputial/clitoral gland	N	N	N	N	N	N	N	N	N	N	N	N	N	N	N	N	N	N	N	N	
Carcinoma, NOS																					
Squamous cell papilloma																					
Squamous cell carcinoma																					
Keratoacanthoma																					
Uterus	+	+	+	+	+	+	+	+	+	+	+	+	+	+	+	+	+	+	+	+	
Papillary carcinoma																					
Papillary adenocarcinoma																					
Fibrosarcoma																					
Endometrial stromal polyp																					
Endometrial stromal sarcoma																					
Endometrial stromal sarcoma, invasive																					
Ovary	+	+	+	+	+	+	+	+	+	+	+	+	+	+	+	+	+	+	+	+	
Granulosa cell tumor																					
Granulosa cell carcinoma																					
NERVOUS SYSTEM																					
Brain	+	+	+	+	+	+	+	+	+	+	+	+	+	+	+	+	+	+	+	+	
Carcinoma, NOS, invasive																					
Glioma, NOS																					
Astrocytoma																					
Spinal cord	N	N	N	N	N	N	N	N	N	N	N	N	N	N	N	N	N	N	N	N	
Osteosarcoma, invasive																					
SPECIAL SENSE ORGANS																					
Zymbal gland	+	+	+	+	+	+	+	+	+	+	+	+	+	+	+	+	+	+	+	+	
Carcinoma in-situ, NOS																					
Squamous cell papilloma																					
Squamous cell carcinoma																					
MUSCULOSKELETAL SYSTEM																					
Bone	N	N	N	N	N	N	N	N	N	N	N	N	N	N	N	N	N	N	N	N	
Squamous cell carcinoma, invasive																					
Osteosarcoma																					
BODY CAVITIES																					
Mesentery	N	N	N	N	N	N	N	N	N	N	N	N	N	N	N	N	N	N	N	N	
Hemangiosarcoma																					
ALL OTHER SYSTEMS																					
Multiple organs, NOS	N	N	N	N	N	N	N	N	N	N	N	N	N	N	N	N	N	N	N	N	
Carcinoma, NOS, invasive																					
Adenocarcinoma, NOS, metastatic																					
C-cell carcinoma, metastatic																					
Granulosa cell carcinoma, metastatic																					
Hemangiosarcoma, invasive																					
Malignant lymphoma, NOS																					
Myselomonocytic leukemia																					
Monocytic leukemia																					
Pituitary fossa	X																				
Carcinoma, NOS, invasive																					

* Animals necropsied

TABLE B3. ANALYSIS OF PRIMARY TUMORS IN FEMALE RATS IN THE LIFETIME FEED STUDY OF TREMOLITE

	Untreated Control	1% Tremolite
Skin: Squamous Cell Papilloma		
Overall Rates (a)	1/118 (1%)	7/250 (3%)
Adjusted Rates (b)	2.9%	15.7%
Terminal Rates (c)	0/13 (0%)	2/22 (9%)
Week of First Observation	138	111
Life Table Test (d)		P=0.151
Incidental Tumor Test (d)		P=0.220
Fisher Exact Test (d)		P=0.214
Skin: Squamous Cell Papilloma or Carcinoma		
Overall Rates (a)	1/118 (1%)	8/250 (3%)
Adjusted Rates (b)	2.9%	16.8%
Terminal Rates (c)	0/13 (0%)	2/22 (9%)
Week of First Observation	138	111
Life Table Test (d)		P=0.111
Incidental Tumor Test (d)		P=0.168
Fisher Exact Test (d)		P=0.158
Integumentary System: Fibroma		
Overall Rates (a)	6/118 (5%)	10/250 (4%)
Adjusted Rates (b)	20.2%	24.6%
Terminal Rates (c)	2/13 (15%)	3/22 (14%)
Week of First Observation	93	109
Life Table Tests (d)		P=0.524N
Incidental Tumor Tests (d)		P=0.385N
Fisher Exact Test (d)		P=0.409N
Integumentary System: Neurofibroma		
Overall Rates (a)	3/118 (3%)	2/250 (1%)
Adjusted Rates (b)	12.8%	2.4%
Terminal Rates (c)	1/13 (8%)	0/22 (0%)
Week of First Observation	137	130
Life Table Tests (d)		P=0.270N
Incidental Tumor Tests (d)		P=0.183N
Fisher Exact Test (d)		P=0.190N
Integumentary System: Fibroma or Neurofibroma		
Overall Rates (a)	9/118 (8%)	12/250 (5%)
Adjusted Rates (b)	31.4%	26.4%
Terminal Rates (c)	3/13 (23%)	3/22 (14%)
Week of First Observation	93	109
Life Table Tests (d)		P=0.312N
Incidental Tumor Tests (d)		P=0.168N
Fisher Exact Test (d)		P=0.196N
Integumentary System: Fibrosarcoma		
Overall Rates (a)	2/118 (2%)	5/250 (2%)
Adjusted Rates (b)	2.3%	3.8%
Terminal Rates (c)	0/13 (0%)	0/22 (0%)
Week of First Observation	87	95
Life Table Tests (d)		P=0.553
Incidental Tumor Tests (d)		P=0.573
Fisher Exact Test (d)		P=0.600
Integumentary System: Fibroma or Fibrosarcoma		
Overall Rates (a)	8/118 (7%)	15/250 (6%)
Adjusted Rates (b)	22.0%	27.5%
Terminal Rates (c)	2/13 (15%)	3/22 (14%)
Week of First Observation	87	95
Life Table Tests (d)		P=0.579N
Incidental Tumor Tests (d)		P=0.454N
Fisher Exact Test (d)		P=0.467N

TABLE B3. ANALYSIS OF PRIMARY TUMORS IN FEMALE RATS IN THE LIFETIME FEED STUDY OF TREMOLITE (Continued)

	Untreated Control	1% Tremolite
Integumentary System: Neurofibroma or Neurofibrosarcoma		
Overall Rates (a)	4/118 (3%)	5/250 (2%)
Adjusted Rates (b)	13.8%	6.7%
Terminal Rates (c)	1/13 (8%)	0/22 (0%)
Week of First Observation	116	83
Life Table Tests (d)		P=0.424N
Incidental Tumor Tests (d)		P=0.330N
Fisher Exact Test (d)		P=0.317N
Integumentary System: Fibrosarcoma or Neurofibrosarcoma		
Overall Rates (a)	3/118 (3%)	8/250 (3%)
Adjusted Rates (b)	3.5%	8.1%
Terminal Rates (c)	0/13 (0%)	0/22 (0%)
Week of First Observation	87	83
Life Table Tests (d)		P=0.445
Incidental Tumor Tests (d)		P=0.475
Fisher Exact Test (d)		P=0.508
Integumentary System: Fibroma, Neurofibroma, Fibrosarcoma, or Neurofibrosarcoma		
Overall Rates (a)	12/118 (10%)	20/250 (8%)
Adjusted Rates (b)	33.8%	32.3%
Terminal Rates (c)	3/13 (23%)	3/22 (14%)
Week of First Observation	87	83
Life Table Tests (d)		P=0.450N
Incidental Tumor Tests (d)		P=0.295N
Fisher Exact Test (d)		P=0.307N
Integumentary System or Salivary Gland: Sarcoma, Fibrosarcoma, or Neurofibrosarcoma		
Overall Rates (a)	4/118 (3%)	9/250 (4%)
Adjusted Rates (b)	6.0%	12.2%
Terminal Rates (c)	0/13 (0%)	1/22 (5%)
Week of First Observation	87	83
Life Table Tests (d)		P=0.511
Incidental Tumor Tests (d)		P=0.566
Fisher Exact Test (d)		P=0.592
Integumentary System or Salivary Gland: Fibroma, Neurofibroma, Sarcoma, Fibrosarcoma, or Neurofibrosarcoma		
Overall Rates (a)	13/118 (11%)	21/250 (8%)
Adjusted Rates (b)	35.5%	35.9%
Terminal Rates (c)	3/13 (23%)	4/22 (18%)
Week of First Observation	87	83
Life Table Tests (d)		P=0.413N
Incidental Tumor Tests (d)		P=0.251N
Fisher Exact Test (d)		P=0.265N
Lung: Alveolar/Bronchiolar Carcinoma		
Overall Rates (e)	3/118 (3%)	2/250 (1%)
Adjusted Rates (b)	6.0%	1.6%
Terminal Rates (c)	0/13 (0%)	0/22 (0%)
Week of First Observation	104	109
Life Table Test (d)		P=0.225N
Incidental Tumor Test (d)		P=0.186N
Fisher Exact Test (d)		P=0.190N
Lung: Alveolar/Bronchiolar Adenoma or Carcinoma		
Overall Rates (e)	3/118 (3%)	3/250 (1%)
Adjusted Rates (b)	6.0%	4.2%
Terminal Rates (c)	0/13 (0%)	0/22 (0%)
Week of First Observation	104	109
Life Table Test (d)		P=0.350N
Incidental Tumor Test (d)		P=0.296N
Fisher Exact Test (d)		P=0.294N

TABLE B3. ANALYSIS OF PRIMARY TUMORS IN FEMALE RATS IN THE LIFETIME FEED STUDY OF TREMOLITE (Continued)

	Untreated Control	1% Tremolite
Hematopoietic System: Leukemia		
Overall Rates (a)	56/118 (47%)	101/250 (40%)
Adjusted Rates (b)	86.1%	76.5%
Terminal Rates (c)	7/13 (54%)	7/22 (32%)
Week of First Observation	79	81
Life Table Test (d)		P=0.408N
Incidental Tumor Test (d)		P=0.113N
Fisher Exact Test (d)		P=0.122N
Liver: Neoplastic Nodule		
Overall Rates (e)	2/118 (2%)	10/250 (4%)
Adjusted Rates (b)	5.0%	20.6%
Terminal Rates (c)	0/13 (0%)	2/22 (9%)
Week of First Observation	116	105
Life Table Test (d)		P=0.149
Incidental Tumor Test (d)		P=0.199
Fisher Exact Test (d)		P=0.202
Kidney: Tubular Cell Adenoma or Adenocarcinoma		
Overall Rates (e)	0/118 (0%)	4/250 (2%)
Adjusted Rates (b)	0.0%	4.2%
Terminal Rates (c)	0/13 (0%)	0/22 (0%)
Week of First Observation		128
Life Table Test (d)		P=0.189
Incidental Tumor Test (d)		P=0.205
Fisher Exact Test (d)		P=0.211
Pituitary Gland: Adenoma		
Overall Rates (e)	51/117 (44%)	93/248 (38%)
Adjusted Rates (b)	82.2%	76.6%
Terminal Rates (c)	6/13 (46%)	7/22 (32%)
Week of First Observation	85	81
Life Table Test (d)		P=0.451N
Incidental Tumor Test (d)		P=0.166N
Fisher Exact Test (d)		P=0.160N
Pituitary Gland: Carcinoma		
Overall Rates (e)	5/117 (4%)	11/248 (4%)
Adjusted Rates (b)	16.1%	7.6%
Terminal Rates (c)	1/13 (8%)	0/22 (0%)
Week of First Observation	116	91
Life Table Test (d)		P=0.516
Incidental Tumor Test (d)		P=0.558
Fisher Exact Test (d)		P=0.592
Pituitary Gland: Adenoma or Carcinoma		
Overall Rates (e)	56/117 (48%)	104/248 (42%)
Adjusted Rates (b)	86.2%	78.4%
Terminal Rates (c)	7/13 (54%)	7/22 (32%)
Week of First Observation	85	81
Life Table Test (d)		P=0.483N
Incidental Tumor Test (d)		P=0.183N
Fisher Exact Test (d)		P=0.170N
Adrenal Cortex: Cortical Adenoma		
Overall Rates (e)	9/118 (8%)	13/250 (5%)
Adjusted Rates (b)	31.6%	24.3%
Terminal Rates (c)	2/13 (15%)	2/22 (9%)
Week of First Observation	96	81
Life Table Test (d)		P=0.390N
Incidental Tumor Test (d)		P=0.234N
Fisher Exact Test (d)		P=0.244N

TABLE B3. ANALYSIS OF PRIMARY TUMORS IN FEMALE RATS IN THE LIFETIME FEED STUDY OF TREMOLITE (Continued)

	Untreated Control	1% Tremolite
Adrenal Medulla: Pheochromocytoma		
Overall Rates (e)	22/118 (19%)	32/250 (13%)
Adjusted Rates (b)	58.2%	48.0%
Terminal Rates (c)	4/13 (31%)	5/22 (23%)
Week of First Observation	85	109
Life Table Test (d)		P=0.249N
Incidental Tumor Test (d)		P=0.088N
Fisher Exact Test (d)		P=0.095N
Adrenal Medulla: Pheochromocytoma or Malignant Pheochromocytoma		
Overall Rates (e)	23/118 (19%)	36/250 (14%)
Adjusted Rates (b)	62.9%	54.8%
Terminal Rates (c)	5/13 (38%)	6/22 (27%)
Week of First Observation	85	109
Life Table Test (d)		P=0.343N
Incidental Tumor Test (d)		P=0.128N
Fisher Exact Test (d)		P=0.138N
Thyroid Gland: Follicular Cell Adenoma		
Overall Rates (e)	3/118 (3%)	7/250 (3%)
Adjusted Rates (b)	6.2%	11.2%
Terminal Rates (c)	0/13 (0%)	1/22 (5%)
Week of First Observation	117	111
Life Table Test (d)		P=0.510
Incidental Tumor Test (d)		P=0.566
Fisher Exact Test (d)		P=0.594
Thyroid Gland: Follicular Cell Carcinoma		
Overall Rates (e)	5/118 (4%)	15/250 (6%)
Adjusted Rates (b)	14.3%	22.6%
Terminal Rates (c)	1/13 (8%)	2/22 (9%)
Week of First Observation	96	109
Life Table Test (d)		P=0.260
Incidental Tumor Test (d)		P=0.334
Fisher Exact Test (d)		P=0.335
Thyroid Gland: Follicular Cell Adenoma or Carcinoma		
Overall Rates (e)	7/118 (6%)	22/250 (9%)
Adjusted Rates (b)	18.5%	31.6%
Terminal Rates (c)	1/13 (8%)	3/22 (14%)
Week of First Observation	96	109
Life Table Test (d)		P=0.163
Incidental Tumor Test (d)		P=0.231
Fisher Exact Test (d)		P=0.231
Thyroid Gland: C-Cell Adenoma		
Overall Rates (e)	7/118 (6%)	8/250 (3%)
Adjusted Rates (b)	10.3%	9.8%
Terminal Rates (c)	0/13 (0%)	0/22 (0%)
Week of First Observation	102	88
Life Table Test (d)		P=0.211N
Incidental Tumor Test (d)		P=0.165N
Fisher Exact Test (d)		P=0.169N
Thyroid Gland: C-Cell Carcinoma		
Overall Rates (e)	18/118 (15%)	41/250 (16%)
Adjusted Rates (b)	51.5%	62.7%
Terminal Rates (c)	3/13 (23%)	9/22 (41%)
Week of First Observation	113	92
Life Table Test (d)		P=0.259
Incidental Tumor Test (d)		P=0.440
Fisher Exact Test (d)		P=0.454

TABLE B3. ANALYSIS OF PRIMARY TUMORS IN FEMALE RATS IN THE LIFETIME FEED STUDY OF TREMOLITE (Continued)

	Untreated Control	1% Tremolite
Thyroid Gland: C-Cell Adenoma or Carcinoma		
Overall Rates (e)	25/118 (21%)	49/250 (20%)
Adjusted Rates (b)	56.6%	66.4%
Terminal Rates (c)	3/13 (23%)	9/22 (41%)
Week of First Observation	102	88
Life Table Test (d)		P=0.470
Incidental Tumor Test (d)		P=0.417N
Fisher Exact Test (d)		P=0.411N
Pancreatic Islets: Islet Cell Adenoma		
Overall Rates (e)	5/118 (4%)	8/250 (3%)
Adjusted Rates (b)	28.5%	10.9%
Terminal Rates (c)	3/13 (23%)	0/22 (0%)
Week of First Observation	117	94
Life Table Test (d)		P=0.535N
Incidental Tumor Test (d)		P=0.407N
Fisher Exact Test (d)		P=0.408N
Pancreatic Islets: Islet Cell Carcinoma		
Overall Rates (e)	3/118 (3%)	6/250 (2%)
Adjusted Rates (b)	15.7%	11.4%
Terminal Rates (c)	1/13 (8%)	1/22 (5%)
Week of First Observation	143	110
Life Table Test (d)		P=0.568
Incidental Tumor Test (d)		P=0.590N
Fisher Exact Test (d)		P=0.593N
Pancreatic Islets: Islet Cell Adenoma or Carcinoma		
Overall Rates (e)	8/118 (7%)	13/250 (5%)
Adjusted Rates (b)	41.3%	19.3%
Terminal Rates (c)	4/13 (31%)	1/22 (5%)
Week of First Observation	117	94
Life Table Test (d)		P=0.504N
Incidental Tumor Test (d)		P=0.331N
Fisher Exact Test (d)		P=0.348N
Mammary Gland: Fibroadenoma		
Overall Rates (a)	62/118 (53%)	127/250 (51%)
Adjusted Rates (b)	90.4%	92.7%
Terminal Rates (c)	8/13 (62%)	16/22 (73%)
Week of First Observation	74	76
Life Table Test (d)		P=0.310
Incidental Tumor Test (d)		P=0.422N
Fisher Exact Test (d)		P=0.421N
Mammary Gland: Adenocarcinoma		
Overall Rates (a)	24/118 (20%)	21/250 (8%)
Adjusted Rates (b)	53.3%	36.7%
Terminal Rates (c)	2/13 (15%)	4/22 (18%)
Week of First Observation	79	95
Life Table Test (d)		P=0.008N
Incidental Tumor Test (d)		P<0.001N
Fisher Exact Test (d)		P=0.001N
Clitoral Gland: Squamous Cell Carcinoma		
Overall Rates (e)	6/118 (5%)	15/250 (6%)
Adjusted Rates (b)	19.6%	27.4%
Terminal Rates (c)	2/13 (15%)	4/22 (18%)
Week of First Observation	105	109
Life Table Tests (d)		P=0.369
Incidental Tumor Tests (d)		P=0.468
Fisher Exact Test (d)		P=0.466

TABLE B3. ANALYSIS OF PRIMARY TUMORS IN FEMALE RATS IN THE LIFETIME FEED STUDY OF TREMOLITE (Continued)

	Untreated Control	1% Tremolite
Clitoral Gland: Squamous Cell Papilloma or Carcinoma		
Overall Rates (e)	6/118 (5%)	16/250 (6%)
Adjusted Rates (b)	19.6%	29.3%
Terminal Rates (c)	2/13 (15%)	4/22 (18%)
Week of First Observation	105	109
Life Table Tests (d)		P=0.311
Incidental Tumor Tests (d)		P=0.410
Fisher Exact Test (d)		P=0.407
Clitoral Gland: Carcinoma, Squamous Cell Papilloma, or Squamous Cell Carcinoma		
Overall Rates (e)	6/118 (5%)	17/250 (7%)
Adjusted Rates (b)	19.6%	30.2%
Terminal Rates (c)	2/13 (15%)	4/22 (18%)
Week of First Observation	105	109
Life Table Tests (d)		P=0.258
Incidental Tumor Tests (d)		P=0.357
Fisher Exact Test (d)		P=0.351
Uterus: Endometrial Stromal Polyp		
Overall Rates (e)	15/118 (13%)	28/249 (11%)
Adjusted Rates (b)	36.9%	34.1%
Terminal Rates (c)	1/13 (8%)	4/22 (18%)
Week of First Observation	99	84
Life Table Test (d)		P=0.551N
Incidental Tumor Test (d)		P=0.406N
Fisher Exact Test (d)		P=0.402N
Ovary: Granulosa Cell Tumor		
Overall Rates (e)	3/118 (3%)	3/249 (1%)
Adjusted Rates (b)	9.2%	6.6%
Terminal Rates (c)	0/13 (0%)	0/22 (0%)
Week of First Observation	124	119
Life Table Tests (d)		P=0.366N
Incidental Tumor Tests (d)		P=0.326N
Fisher Exact Test (d)		P=0.295N
Ovary: Granulosa Cell Tumor or Carcinoma		
Overall Rates (e)	3/118 (3%)	4/249 (2%)
Adjusted Rates (b)	9.2%	6.9%
Terminal Rates (c)	0/13 (0%)	0/22 (0%)
Week of First Observation	124	88
Life Table Tests (d)		P=0.475N
Incidental Tumor Tests (d)		P=0.429N
Fisher Exact Test (d)		P=0.402N
Zymbal Gland: Squamous Cell Carcinoma		
Overall Rates (e)	3/118 (3%)	6/250 (2%)
Adjusted Rates (b)	5.9%	9.3%
Terminal Rates (c)	0/13 (0%)	1/22 (5%)
Week of First Observation	113	91
Life Table Tests (d)		P=0.595
Incidental Tumor Tests (d)		P=0.608N
Fisher Exact Test (d)		P=0.593N
Zymbal Gland: Squamous Cell Papilloma or Carcinoma		
Overall Rates (e)	3/118 (3%)	7/250 (3%)
Adjusted Rates (b)	5.9%	13.6%
Terminal Rates (c)	0/13 (0%)	2/22 (9%)
Week of First Observation	113	91
Life Table Tests (d)		P=0.492
Incidental Tumor Tests (d)		P=0.583
Fisher Exact Test (d)		P=0.594

TABLE B3. ANALYSIS OF PRIMARY TUMORS IN FEMALE RATS IN THE LIFETIME FEED STUDY OF TREMOLITE (Continued)

	Untreated Control	1% Tremolite
All Sites: Benign Tumors		
Overall Rates (a)	100/118 (85%)	201/250 (80%)
Adjusted Rates (b)	100.0%	98.9%
Terminal Rates (c)	13/13 (100%)	20/22 (91%)
Week of First Observation	74	76
Life Table Test (d)		P=0.338
Incidental Tumor Test (d)		P=0.176N
Fisher Exact Test (d)		P=0.195N
All Sites: Malignant Tumors		
Overall Rates (a)	96/118 (81%)	188/250 (75%)
Adjusted Rates (b)	96.6%	100.0%
Terminal Rates (c)	10/13 (77%)	22/22 (100%)
Week of First Observation	48	49
Life Table Test (d)		P=0.442
Incidental Tumor Test (d)		P=0.113N
Fisher Exact Test (d)		P=0.118N
All Sites: All Tumors		
Overall Rates (a)	115/118 (97%)	243/250 (97%)
Adjusted Rates (b)	100.0%	100.0%
Terminal Rates (c)	13/13 (100%)	22/22 (100%)
Week of First Observation	48	49
Life Table Test (d)		P=0.201
Incidental Tumor Test (d)		P=0.605N
Fisher Exact Test (d)		P=0.594N

(a) Number of tumor-bearing animals/number of animals examined grossly at the site

(b) Kaplan-Meier estimated tumor incidences at the end of the study after adjusting for intercurrent mortality

(c) Observed tumor incidence in animals killed at the end of the study

(d) Beneath the dosed group incidence are the P values corresponding to pairwise comparisons between the dosed group and the controls. The life table analysis regards tumors in animals dying prior to terminal kill as being (directly or indirectly) the cause of death. The incidental tumor test regards these lesions as nonfatal. The Fisher exact test compares directly the overall incidence rates. A lower incidence in the dosed group than in controls is indicated by (N).

(e) Number of tumor-bearing animals/number of animals examined microscopically at the site

TABLE B4. SUMMARY OF THE INCIDENCE OF NONNEOPLASTIC LESIONS IN FEMALE RATS IN THE LIFETIME FEED STUDY OF TREMOLITE

	Untreated Control	1% Tremolite
Animals initially in study	18	250
Animals necropsied	18	250
Animals examined histopathologically	18	250
INTEGUMENTARY SYSTEM		
*Skin	(118)	(250)
Epidermal inclusion cyst		1 (0.4%)
Abscess, NOS	1 (1%)	
Inflammation, chronic focal	1 (1%)	2 (1%)
Necrosis, focal		2 (1%)
Alopecia		1 (0.4%)
Hyperkeratosis	1 (1%)	2 (1%)
Acanthosis		3 (1%)
*Subcutaneous tissue	(118)	(250)
Abscess, NOS	1 (1%)	1 (0.4%)
Fibrosis, focal		1 (0.4%)
RESPIRATORY SYSTEM		
*Nasal turbinate	(118)	(250)
Abscess, NOS		1 (0.4%)
Inflammation, chronic diffuse		1 (0.4%)
Hyperkeratosis		1 (0.4%)
#Lung	(118)	(250)
Congestion, NOS	4 (3%)	4 (2%)
Hemorrhage	8 (7%)	12 (5%)
Inflammation, interstitial	7 (6%)	11 (4%)
Inflammation, acute focal		1 (0.4%)
Inflammation, chronic	105 (89%)	220 (88%)
Inflammation, chronic diffuse		1 (0.4%)
Granuloma, NOS	1 (1%)	3 (1%)
Fibrosis, diffuse	1 (1%)	1 (0.4%)
Necrosis, focal		1 (0.4%)
Necrosis, diffuse	1 (1%)	
Pigmentation, NOS	3 (3%)	11 (4%)
Hyperplasia, alveolar epithelium	2 (2%)	4 (2%)
Histiocytosis		1 (0.4%)
#Lung/alveoli	(118)	(250)
Edema, NOS		1 (0.4%)
Histiocytosis	12 (10%)	17 (7%)
HEMATOPOIETIC SYSTEM		
*Multiple organs	(118)	(250)
Erythrophagocytosis		1 (0.4%)
Hyperplasia, lymphoid	1 (1%)	
*Mammary gland	(118)	(250)
Hyperplasia, reticulum cell		1 (0.4%)
#Bone marrow	(118)	(248)
Hypoplasia, NOS	7 (6%)	5 (2%)
Hyperplasia, NOS	1 (1%)	5 (2%)
Myelofibrosis	1 (1%)	2 (1%)
#Spleen	(118)	(250)
Hemorrhage	3 (3%)	2 (1%)
Hematoma, NOS	1 (1%)	
Fibrosis, focal	6 (5%)	6 (2%)
Fibrosis, multifocal	1 (1%)	
Fibrosis, diffuse	1 (1%)	3 (1%)
Necrosis, NOS		1 (0.4%)
Necrosis, focal	1 (1%)	3 (1%)
Hemosiderosis	18 (15%)	43 (17%)
Hematopoiesis	38 (32%)	59 (24%)

TABLE B4. SUMMARY OF THE INCIDENCE OF NONNEOPLASTIC LESIONS IN FEMALE RATS IN THE LIFETIME FEED STUDY OF TREMOLITE (Continued)

	Untreated Control	1% Tremolite
HEMATOPOIETIC SYSTEM (Continued)		
#Splenic capsule	(118)	(250)
Hemorrhage	1 (1%)	
Fibrosis, focal		1 (0.4%)
Fibrosis, diffuse	1 (1%)	
#Splenic follicles	(118)	(250)
Atrophy, NOS	2 (2%)	4 (2%)
#Mandibular lymph node	(118)	(250)
Hemorrhage	1 (1%)	
Pigmentation, NOS	1 (1%)	1 (0.4%)
Erythrophagocytosis		4 (2%)
Hyperplasia, reticulum cell	1 (1%)	
Hyperplasia, lymphoid	18 (15%)	35 (14%)
#Cervical lymph node	(118)	(250)
Hemorrhage	1 (1%)	
#Mediastinal lymph node	(118)	(250)
Congestion, NOS		2 (1%)
Hemorrhage	4 (3%)	3 (1%)
Necrosis, focal		1 (0.4%)
Pigmentation, NOS	13 (11%)	40 (16%)
Hyperplasia, NOS	1 (1%)	
Erythrophagocytosis	6 (5%)	15 (6%)
Hyperplasia, reticulum cell	1 (1%)	4 (2%)
Hyperplasia, lymphoid	3 (3%)	5 (2%)
#Pancreatic lymph node	(118)	(250)
Pigmentation, NOS	3 (3%)	12 (5%)
Hyperplasia, reticulum cell	2 (2%)	13 (5%)
#Mesenteric lymph node	(118)	(250)
Necrosis, focal		1 (0.4%)
Pigmentation, NOS	3 (3%)	16 (6%)
Atrophy, NOS	2 (2%)	1 (0.4%)
Erythrophagocytosis	1 (1%)	10 (4%)
Hyperplasia, reticulum cell	41 (35%)	121 (48%)
Hyperplasia, lymphoid	2 (2%)	15 (6%)
Hematopoiesis		1 (0.4%)
#Ileocolic lymph node	(118)	(250)
Hyperplasia, reticulum cell		1 (0.4%)
Hyperplasia, lymphoid		1 (0.4%)
#Renal lymph node	(118)	(250)
Pigmentation, NOS	1 (1%)	
Erythrophagocytosis		1 (0.4%)
Hyperplasia, reticulum cell	3 (3%)	
#Iliac lymph node	(118)	(250)
Hyperplasia, lymphoid		1 (0.4%)
*Sternum	(118)	(250)
Myelofibrosis	2 (2%)	
#Liver	(118)	(250)
Leukocytosis, NOS	4 (3%)	6 (2%)
Hematopoiesis	2 (2%)	2 (1%)
#Kidney	(118)	(250)
Hematopoiesis		1 (0.4%)
#Thymus	(83)	(221)
Ectopia	1 (1%)	
Congestion, NOS	1 (1%)	1 (0.5%)
CIRCULATORY SYSTEM		
#Spleen	(118)	(250)
Thrombosis, NOS	1 (1%)	1 (0.4%)
#Mediastinal lymph node	(118)	(250)
Lymphangiectasis	1 (1%)	

TABLE B4. SUMMARY OF THE INCIDENCE OF NONNEOPLASTIC LESIONS IN FEMALE RATS IN THE LIFETIME FEED STUDY OF TREMOLITE (Continued)

	Untreated Control	1% Tremolite
CIRCULATORY SYSTEM (Continued)		
#Celiac lymph node	(118)	(250)
Lymphangiectasis		1 (0.4%)
#Mesenteric lymph node	(118)	(250)
Lymphangiectasis	4 (3%)	4 (2%)
#Ileocolic lymph node	(118)	(250)
Lymphangiectasis	3 (3%)	3 (1%)
#Renal lymph node	(118)	(250)
Lymphangiectasis		2 (1%)
#Iliac lymph node	(118)	(250)
Lymphangiectasis		1 (0.4%)
#Lung	(118)	(250)
Thrombosis, NOS		1 (0.4%)
#Heart/atrium	(118)	(250)
Thrombosis, NOS	4 (3%)	
#Myocardium	(118)	(250)
Mineralization		1 (0.4%)
Inflammation, chronic		2 (1%)
Inflammation, chronic focal	37 (31%)	86 (34%)
Inflammation, chronic diffuse	42 (36%)	90 (36%)
*Aorta	(118)	(250)
Mineralization		1 (0.4%)
*Coronary artery	(118)	(250)
Thrombus, organized	1 (1%)	
*Mesenteric artery	(118)	(250)
Inflammation, chronic		1 (0.4%)
#Liver	(118)	(250)
Thrombosis, NOS	1 (1%)	1 (0.4%)
*Mesentery	(118)	(250)
Periarteritis	1 (1%)	
#Adrenal	(118)	(250)
Thrombosis, NOS	1 (1%)	1 (0.4%)
DIGESTIVE SYSTEM		
*Oral mucous membrane	(118)	(250)
Inflammation, chronic focal		1 (0.4%)
Necrosis, focal		1 (0.4%)
*Lip	(118)	(250)
Abscess, NOS		1 (0.4%)
*Tongue	(118)	(250)
Edema, NOS		1 (0.4%)
Inflammation, acute/chronic		1 (0.4%)
Inflammation, chronic focal		1 (0.4%)
Inflammation, chronic diffuse		1 (0.4%)
Hyperkeratosis		2 (1%)
Acanthosis	1 (1%)	1 (0.4%)
#Salivary gland	(118)	(249)
Calculus, unknown gross or microscopic observation		1 (0.4%)
Cystic ducts	1 (1%)	
Inflammation, acute focal		1 (0.4%)
Inflammation, acute/chronic		1 (0.4%)
Inflammation, chronic		1 (0.4%)
Inflammation, chronic diffuse		1 (0.4%)
Atrophy, NOS		2 (1%)
Atrophy, diffuse		1 (0.4%)
#Parotid gland	(118)	(249)
Atrophy, NOS	1 (1%)	
#Liver	(118)	(250)
Hemorrhage	4 (3%)	4 (2%)
Inflammation, chronic	1 (1%)	1 (0.4%)
Granuloma, NOS	29 (25%)	61 (24%)
Hepatitis, toxic	22 (19%)	50 (20%)

TABLE B4. SUMMARY OF THE INCIDENCE OF NONNEOPLASTIC LESIONS IN FEMALE RATS IN THE LIFETIME FEED STUDY OF TREMOLITE (Continued)

	Untreated Control	1% Tremolite
DIGESTIVE SYSTEM		
#Liver (Continued)	(118)	(250)
Degeneration, NOS	2 (2%)	3 (1%)
Necrosis, focal	20 (17%)	31 (12%)
Metamorphosis fatty	29 (25%)	60 (24%)
Pigmentation, NOS	16 (14%)	45 (18%)
Mitotic alteration		1 (0.4%)
Focal cellular change	68 (58%)	139 (56%)
Angiectasis	2 (2%)	10 (4%)
#Bile duct	(118)	(250)
Cyst, NOS	1 (1%)	2 (1%)
Inflammation, chronic	5 (4%)	18 (7%)
Fibrosis		1 (0.4%)
Hyperplasia, NOS	2 (2%)	14 (6%)
#Pancreas	(118)	(250)
Ectopia	2 (2%)	10 (4%)
Embryonal rest		1 (0.4%)
Fibrosis, focal		1 (0.4%)
Atrophy, focal	7 (6%)	21 (8%)
Atrophy, diffuse	3 (3%)	4 (2%)
Hyperplasia, focal		2 (1%)
#Pancreatic acinus	(118)	(250)
Hyperplasia, focal	3 (3%)	6 (2%)
#Esophagus	(118)	(248)
Inflammation, chronic diffuse		1 (0.4%)
Hyperkeratosis	3 (3%)	4 (2%)
Acanthosis		1 (0.4%)
#Stomach	(118)	(250)
Embryonal rest	1 (1%)	
Mineralization	4 (3%)	2 (1%)
Cyst, NOS		1 (0.4%)
Hemorrhage		1 (0.4%)
Inflammation, acute focal	1 (1%)	
Inflammation, acute diffuse		1 (0.4%)
Abscess, NOS	1 (1%)	
Inflammation, chronic focal	10 (8%)	11 (4%)
Inflammation, chronic diffuse	15 (13%)	27 (11%)
Ulcer, perforated	9 (8%)	11 (4%)
Necrosis, focal	16 (14%)	31 (12%)
Necrosis, fibrinoid	1 (1%)	
Hyperplasia, epithelial		2 (1%)
Hyperkeratosis	15 (13%)	29 (12%)
Acanthosis	23 (19%)	45 (18%)
#Gastric submucosa	(118)	(250)
Edema, NOS		1 (0.4%)
#Gastric fundus	(118)	(250)
Hyperplasia, focal	2 (2%)	
Hyperplasia, diffuse	1 (1%)	
#Duodenum	(118)	(250)
Diverticulum		1 (0.4%)
Fibrosis, focal		2 (1%)
Necrosis, focal	1 (1%)	2 (1%)
#Jejunum	(118)	(250)
Fibrosis, focal		1 (0.4%)
#Ileum	(118)	(250)
Inflammation, chronic focal		1 (0.4%)
Necrosis, focal		1 (0.4%)
#Large intestine	(118)	(250)
Parasitism		12 (5%)
#Colon	(118)	(250)
Hemorrhage		1 (0.4%)
Inflammation, acute focal	1 (1%)	

TABLE B4. SUMMARY OF THE INCIDENCE OF NONNEOPLASTIC LESIONS IN FEMALE RATS IN THE LIFETIME FEED STUDY OF TREMOLITE (Continued)

	Untreated Control	1% Tremolite
DIGESTIVE SYSTEM		
#Colon (Continued)	(118)	(250)
Inflammation, chronic focal	1 (1%)	
Inflammation, chronic diffuse	1 (1%)	
Fibrosis, focal		1 (0.4%)
Parasitism	5 (4%)	2 (1%)
Necrosis, focal	1 (1%)	
Necrosis, diffuse		1 (0.4%)
Hyperplasia, epithelial		1 (0.4%)
#Cecum	(118)	(250)
Dilatation, NOS		1 (0.4%)
Hemorrhage		1 (0.4%)
Hematoma, NOS		1 (0.4%)
Inflammation, acute focal	1 (1%)	
Inflammation, chronic focal		1 (0.4%)
Inflammation, chronic diffuse	3 (3%)	
Ulcer, perforated		1 (0.4%)
Parasitism	2 (2%)	1 (0.4%)
Necrosis, focal	1 (1%)	2 (1%)
Necrosis, diffuse		1 (0.4%)
Hyperplasia, epithelial		1 (0.4%)
URINARY SYSTEM		
#Kidney	(118)	(250)
Mineralization	107 (91%)	215 (86%)
Inflammation, acute focal		1 (0.4%)
Inflammation, chronic	112 (95%)	227 (91%)
Fibrosis, diffuse	1 (1%)	
Metamorphosis fatty	1 (1%)	1 (0.4%)
Pigmentation, NOS	2 (2%)	
Hyperplasia, tubular cell	1 (1%)	1 (0.4%)
#Kidney/cortex	(118)	(250)
Cyst, NOS	3 (3%)	3 (1%)
#Renal papilla	(118)	(250)
Necrosis, focal	1 (1%)	
#Kidney/tubule	(118)	(250)
Pigmentation, NOS	71 (60%)	175 (70%)
#Urinary bladder	(118)	(246)
Congestion, NOS	1 (1%)	
Inflammation, chronic focal	1 (1%)	
Inflammation, chronic diffuse	1 (1%)	
Hyperplasia, epithelial	1 (1%)	1 (0.4%)
Hyperplasia, diffuse	2 (2%)	
ENDOCRINE SYSTEM		
#Pituitary	(117)	(248)
Cyst, NOS	5 (4%)	13 (5%)
Hemorrhagic cyst	8 (7%)	4 (2%)
Hyperplasia, focal	14 (12%)	31 (13%)
Hyperplasia, diffuse	1 (1%)	
Angiectasis	29 (25%)	41 (17%)
Metaplasia, osseous		1 (0.4%)
#Adrenal	(118)	(250)
Congestion, NOS		1 (0.4%)
Hemorrhage	1 (1%)	1 (0.4%)
Degeneration, hyaline		1 (0.4%)
Degeneration, lipoid		1 (0.4%)
Necrosis, focal	1 (1%)	
Infarct, NOS		1 (0.4%)
Amyloidosis		1 (0.4%)
Metamorphosis fatty	1 (1%)	3 (1%)

TABLE B4. SUMMARY OF THE INCIDENCE OF NONNEOPLASTIC LESIONS IN FEMALE RATS IN THE LIFETIME FEED STUDY OF TREMOLITE (Continued)

	Untreated Control	1% Tremolite
ENDOCRINE SYSTEM		
#Adrenal (Continued)	(118)	(250)
Metamorphosis fatty	1 (1%)	3 (1%)
Angiectasis		2 (1%)
#Adrenal cortex	(118)	(250)
Congestion, NOS	1 (1%)	1 (0.4%)
Hemorrhage	1 (1%)	
Inflammation, chronic		1 (0.4%)
Degeneration, NOS	1 (1%)	6 (2%)
Necrosis, focal		1 (0.4%)
Metamorphosis fatty	59 (50%)	105 (42%)
Atrophy, NOS	1 (1%)	
Hypertrophy, NOS		1 (0.4%)
Hypertrophy, focal		3 (1%)
Hyperplasia, NOS		1 (0.4%)
Hyperplasia, focal	21 (18%)	47 (19%)
Angiectasis		1 (0.4%)
#Adrenal medulla	(118)	(250)
Hyperplasia, focal	29 (25%)	40 (16%)
#Thyroid	(118)	(250)
Cystic follicles	1 (1%)	
Follicular cyst, NOS	6 (5%)	25 (10%)
Hyperplasia, C-cell	18 (15%)	72 (29%)
#Parathyroid	(113)	(238)
Hyperplasia, NOS	10 (9%)	20 (8%)
#Pancreatic islets	(118)	(250)
Hyperplasia, focal		1 (0.4%)
REPRODUCTIVE SYSTEM		
*Mammary gland	(118)	(250)
Galactocele	16 (14%)	52 (21%)
Cystic ducts	38 (32%)	115 (46%)
Inflammation, acute diffuse		1 (0.4%)
Abscess, NOS	2 (2%)	1 (0.4%)
Inflammation, acute/chronic		1 (0.4%)
Inflammation, chronic focal	1 (1%)	
Necrosis, focal		1 (0.4%)
Hyperplasia, NOS	4 (3%)	36 (14%)
Hyperplasia, focal	1 (1%)	1 (0.4%)
Hyperplasia, diffuse	10 (8%)	2 (1%)
*Preputial gland	(118)	(250)
Cystic ducts	1 (1%)	6 (2%)
Inflammation, acute diffuse		1 (0.4%)
Abscess, NOS	1 (1%)	2 (1%)
Inflammation, chronic diffuse		1 (0.4%)
Necrosis, focal		2 (1%)
Necrosis, diffuse		1 (0.4%)
Hyperplasia, NOS		1 (0.4%)
Hyperplasia, diffuse	1 (1%)	3 (1%)
Hyperkeratosis		1 (0.4%)
Acanthosis		1 (0.4%)
*Vagina	(118)	(250)
Acanthosis	1 (1%)	
#Uterus	(118)	(249)
Hydrometra	4 (3%)	15 (6%)
Hemorrhage	2 (2%)	1 (0.4%)
Inflammation, acute	1 (1%)	1 (0.4%)
Abscess, NOS		2 (1%)
Inflammation, chronic focal		1 (0.4%)
Inflammation, chronic diffuse	1 (1%)	
Fibrosis, focal		1 (0.4%)

TABLE B4. SUMMARY OF THE INCIDENCE OF NONNEOPLASTIC LESIONS IN FEMALE RATS IN THE LIFETIME FEED STUDY OF TREMOLITE (Continued)

	Untreated Control	1% Tremolite
REPRODUCTIVE SYSTEM		
#Uterus (Continued)	(118)	(249)
Hyperplasia, papillary	1 (1%)	
Metaplasia, squamous		1 (0.4%)
#Cervix uteri	(118)	(249)
Cyst, NOS		3 (1%)
Inflammation, acute diffuse		1 (0.4%)
Fibrosis	2 (2%)	2 (1%)
Fibrosis, diffuse	2 (2%)	
Hyperkeratosis		1 (0.4%)
Acanthosis		1 (0.4%)
#Uterus/endometrium	(118)	(249)
Cyst, NOS	6 (5%)	6 (2%)
Hyperplasia, NOS		1 (0.4%)
Hyperplasia, papillary	1 (1%)	2 (1%)
Hyperplasia, cystic		1 (0.4%)
#Endometrial gland	(118)	(249)
Cyst, NOS	1 (1%)	
#Ovary	(118)	(249)
Cyst, NOS	8 (7%)	17 (7%)
Parovarian cyst		1 (0.4%)
Degeneration, hyaline		1 (0.4%)
Pigmentation, NOS	1 (1%)	1 (0.4%)
Atrophy, NOS	1 (1%)	
Hyperplasia, focal	1 (1%)	
NERVOUS SYSTEM		
#Cerebrum	(118)	(250)
Hydrocephalus, NOS	1 (1%)	
Hemorrhage	2 (2%)	3 (1%)
Abscess, NOS		1 (0.4%)
Gliosis	1 (1%)	
Necrosis, focal		1 (0.4%)
#Brain	(118)	(250)
Hemorrhage	1 (1%)	
Necrosis, focal	1 (1%)	
#Cerebellum	(118)	(250)
Hemorrhage	5 (4%)	2 (1%)
Abscess, NOS		1 (0.4%)
Necrosis, focal		1 (0.4%)
*Spinal cord	(118)	(250)
Hemorrhage	1 (1%)	
Degeneration, NOS		1 (0.4%)
SPECIAL SENSE ORGANS		
*Eye	(118)	(250)
Hemorrhage	3 (3%)	8 (3%)
Inflammation, chronic		1 (0.4%)
Synechia, anterior		1 (0.4%)
Synechia, posterior	2 (2%)	8 (3%)
Cataract	17 (14%)	42 (17%)
*Eye anterior chamber	(118)	(250)
Empyema		3 (1%)
*Vitreous body	(118)	(250)
Vascularization		1 (0.4%)
*Eye/cornea	(118)	(250)
Inflammation, necrotizing		2 (1%)
Inflammation, chronic focal	8 (7%)	5 (2%)
Inflammation, chronic diffuse	5 (4%)	7 (3%)
Inflammation, chronic necrotizing		1 (0.4%)

TABLE B4. SUMMARY OF THE INCIDENCE OF NONNEOPLASTIC LESIONS IN FEMALE RATS IN THE LIFETIME FEED STUDY OF TREMOLITE (Continued)

	Untreated Control	1% Tremolite
SPECIAL SENSE ORGANS (Continued)		
*Eye/retina	(118)	(250)
Degeneration, NOS	46 (39%)	86 (34%)
*Eye/crystalline lens	(118)	(250)
Rupture		1 (0.4%)
*Eyelid	(118)	(250)
Fibrosis, focal	1 (1%)	
*Harderian gland	(118)	(250)
Inflammation, chronic		1 (0.4%)
Atrophy, NOS	1 (1%)	1 (0.4%)
*Zymbal gland	(118)	(250)
Cystic ducts	8 (7%)	17 (7%)
Hyperplasia, focal		1 (0.4%)
Hyperkeratosis	1 (1%)	3 (1%)
MUSCULOSKELETAL SYSTEM		
*Skull	(118)	(250)
Osteopetrosis	8 (7%)	15 (6%)
*Sternum	(118)	(250)
Osteopetrosis	8 (7%)	19 (8%)
*Rib	(118)	(250)
Degeneration, NOS		1 (0.4%)
BODY CAVITIES		
*Mediastinum	(118)	(250)
Edema, NOS	1 (1%)	
Inflammation, chronic	1 (1%)	
*Abdominal cavity	(118)	(250)
Hemorrhage		1 (0.4%)
Necrosis, fat	7 (6%)	15 (6%)
*Mesentery	(118)	(250)
Inflammation, chronic focal	2 (2%)	
ALL OTHER SYSTEMS		
*Multiple organs	(118)	(250)
Mineralization	1 (1%)	
Inflammation, chronic	3 (3%)	6 (2%)
Degeneration, NOS	1 (1%)	
Metamorphosis fatty	1 (1%)	1 (0.4%)
Fibrous osteodystrophy	1 (1%)	
Pigmentation, NOS		3 (1%)
Diaphragm		
Hernia, NOS	1	2
Adipose tissue		
Hemorrhage	1	
Mesentery of colon		
Inflammation, chronic focal	1	
SPECIAL MORPHOLOGY SUMMARY		
Autolysis/necropsy/histology performed	1	

* Number of animals receiving complete necropsy examination; all gross lesions including masses examined microscopically.

Number of animals examined microscopically at this site

APPENDIX C

PATHOGEN BURDEN SURVEY

	PAGE	
TABLE C1	INITIAL MICROSCOPIC EXAMINATION FOR ENDOPARASITES AND BACTERIA IN F ₀ RATS IN THE LIFETIME FEED STUDIES OF TREMOLITE	160
TABLE C2	MURINE VIRUS ANTIBODY DETERMINATION IN F ₀ RATS IN THE LIFETIME FEED STUDIES OF TREMOLITE	160
TABLE C3	INITIAL INDIVIDUAL HISTOPATHOLOGIC FINDINGS IN F ₀ RATS IN THE LIFETIME FEED STUDIES OF TREMOLITE	161
	PATHOGEN BURDEN SUMMARY (F ₀ Repeated)	162
TABLE C4	REPEATED MICROSCOPIC EXAMINATION FOR ENDOPARASITES AND BACTERIA IN F ₀ RATS IN THE LIFETIME FEED STUDIES OF TREMOLITE	163
TABLE C5	REPEATED MURINE VIRUS ANTIBODY DETERMINATION IN F ₀ RATS IN THE LIFETIME FEED STUDIES OF TREMOLITE	163
TABLE C6	REPEATED INDIVIDUAL HISTOPATHOLOGIC FINDINGS IN F ₀ RATS IN THE LIFETIME FEED STUDIES OF TREMOLITE	164
	PATHOGEN BURDEN SUMMARY (F ₁)	165
TABLE C7	MICROSCOPIC EXAMINATION FOR ENDOPARASITES AND BACTERIA IN F ₁ RATS IN THE LIFETIME FEED STUDIES OF TREMOLITE	166
TABLE C8	MURINE VIRUS ANTIBODY DETERMINATION IN F ₁ RATS IN THE LIFETIME FEED STUDIES OF TREMOLITE	167
TABLE C9	INDIVIDUAL HISTOPATHOLOGIC FINDINGS IN F ₁ RATS IN THE LIFETIME FEED STUDIES OF TREMOLITE	168

TABLE C1. INITIAL MICROSCOPIC EXAMINATION FOR ENDOPARASITES AND BACTERIA IN F₀ RATS IN THE LIFETIME FEED STUDIES OF TREMOLITE

Animal/Specimen Number (a)	Micro-organisms Identified (b)
149/3756	1 + Coliform; 1 + <i>Proteus vulgaris</i>
150/3757	3 + Coliform; 1 + <i>Proteus vulgaris</i>
151/3758	3 + Coliform; 1 + <i>Proteus vulgaris</i>
152/3759	3 + Coliform; 1 + <i>Proteus vulgaris</i>
153/3760	1 + Coliform (two types); 1 + <i>Proteus vulgaris</i>
154/3761	1 + Coliform; 1 + <i>Proteus vulgaris</i>
155/3762	2 + Coliform; 1 + <i>Proteus vulgaris</i>
156/3763	2 + Coliform; 1 + <i>Proteus vulgaris</i>
157/3764	3 + Coliform; 1 + <i>Proteus vulgaris</i>
158/3765	3 + Coliform; 1 + <i>Proteus vulgaris</i>
159/3766	3 + Coliform; 1 + <i>Proteus vulgaris</i>
160/3767	1 + Coliform; 1 + <i>Proteus vulgaris</i>
161/3768	1 + Coliform; 1 + <i>Proteus vulgaris</i>
162/3769	2 + Coliform; 1 + <i>Proteus vulgaris</i>
163/3770	1 + Coliform; 1 + <i>Proteus vulgaris</i>
164/3771	1 + Coliform; 1 + <i>Proteus vulgaris</i>

(a) Date of specimen: 11/2/77

(b) Lung, spleen, feces, and tracheal wash were examined for each specimen; no growth observed in the spleen or lungs; no mycoplasma isolated from tracheal washings.

TABLE C2. MURINE VIRUS ANTIBODY DETERMINATION IN F₀ RATS IN THE LIFETIME FEED STUDIES OF TREMOLITE

Sample Number	Complement Fixation	
	Sendai	LCM
3756	—	—
3757	—	—
3758	—	—
3759	—	—
3760	—	—
3761	—	—
3762	—	—
3763	—	—
3764	—	—
3765	—	—
3766	—	—
3768	—	—
3769	—	—
3770	—	—
3771	—	—
Significant titer	10	10

TABLE C3. INITIAL INDIVIDUAL HISTOPATHOLOGIC FINDINGS IN F₀ RATS IN THE LIFETIME FEED STUDIES OF TREMOLITE

Site/Lesion	Animal Number:	Male								Female								
		1	1	1	1	1	1	1	1	1	1	1	1	1	1	1	1	
		4	5	5	5	5	5	5	5	5	5	5	6	6	6	6	6	
		9	0	1	2	3	4	5	6	7	8	9	0	1	2	3	4	
Brain		X	X	X	X	X	X	X	X	X	X	X	X	X	X	X	X	X
Heart		X	X	X	X	X	X	X	X	X	X	X	X	X	X	X	X	X
Lung																		
Peribronchial lymphoid hyperplasia		1	1		1	1	2		2	1	1	2	1	2	1	1	1	3
Foci of mononuclear cells				P					P									
Perivascular lymphoid hyperplasia					1				1									
Artifactual collapse										P								P
Aspirated blood													P					
Spleen		X	X	X	X	X	X	X	X	X	X	X	X	X	X	X	X	O
Liver		X	X	X	X	X	X	X		X		X	X					X
Nonsuppurative pericholangitis									1		1			1	1	1		
Kidney		X	X	X		X		X		X	X	X	X		X			
Focal interstitial nephritis					1				1					2			1	2
Regenerative tubular epithelium					P		P										P	
Early fibrosis					P													
Mononuclear cells					P				P					P		P	P	
Small intestine		X	X	X	X	X	X	X	X	X	X	X	X	X	X	X	X	X
Large intestine		X	X	X	X	X	X	X	X	X	X	X	X	X	X	X	X	X
Salivary gland		X	X	X	X	X	X	X	X	X	X	X	X	O	X	O	X	
Urinary bladder		X	X	X	X	O	X	X	X	X	X	O	X	X	X	O	X	
Harderian gland		X	X	X	X	X	O	O	X	X	X	X	X	X	X	X	X	X
Skin		X	X	X	X	X	X	X	X	X	X	X	X	X	X	X	X	X
Anus		X	O	X	X	X	X	X	X	O	X	X	O	X	X	X	X	X
Trachea		X	X	X	X	X	X	X	X	X	X	X	X	O	X	X	X	O
Mesenteric lymph node																		
Lymphoid hyperplasia													P					

Type of Finding:

- O = Tissue absent
- X = Tissue examined and not remarkable
- P = Finding present

Degree of Finding:

- 1 = Minimal
- 2 = Slight
- 3 = Moderate
- 4 = Moderately severe
- 5 = Severe

Pathogen Burden Summary (F₀ Repeated)

Sections of brain, heart, lung, spleen, liver, kidney, small intestine, large intestine, salivary gland, urinary bladder, harderian gland, skin, anus, and cecum were examined from four male and six female rats (parental generation) killed for pathology burden. A subcutaneous tissue mass in one female was also examined.

Evidence of respiratory disease was noted in all rats. This was characterized by minimal-to-moderate peribronchial lymphoid hyperplasia in all 10 rats and a bronchial exudate in 3 males. These lesions were slightly more pronounced than those observed at a prior kill.

Minimal focal nonsuppurative myocarditis was noted in one male. Minimal-to-moderate pigment deposition of yellowish-brown granular pigment (presumably hemosiderin) was noted in sections of spleen from three male and four female rats.

In sections of liver, scattered microgranulomas were observed in one male and foci of mononuclear cells occurred in two other males.

In the kidney, minimal chronic interstitial nephritis occurred in three males and foci of intratubular mineralization was noted at the corticomedullary junction in two males and three females.

Cross-sections of a nematode parasite, presumably *Syphacea obvelata*, were noted in the colon of one male rat.

The subcutaneous tissue mass occurring in the vicinity of the salivary glands in female no. 286 was diagnosed as a mammary fibroadenoma.

The remaining tissues examined were not remarkable.

TABLE C4. REPEATED MICROSCOPIC EXAMINATION FOR ENDOPARASITES AND BACTERIA IN F₀ RATS IN THE LIFETIME FEED STUDIES OF TREMOLITE

Animal/Specimen Number (a)	Micro-organisms Identified (b)
277/4008	4+ Group D Streptococcus; 2+ <i>Staphylococcus epidermidis</i> ; 3+ Coliform; 2+ <i>Pseudomonas aeruginosa</i> ; 3+ <i>Proteus rettgeri</i>
278/4009	4+ Group D Streptococcus; 2+ <i>Staphylococcus epidermidis</i> ; 2+ Coliform; 1+ <i>Pseudomonas aeruginosa</i> ; 1+ <i>Proteus morgani</i>
279/4010	4+ Group D Streptococcus; 3+ Diphtheroids; 4+ Coliform; 4+ <i>Pseudomonas aeruginosa</i> ; 4+ <i>Citrobacter freundii</i>
280/4011	3+ Group D Streptococcus
281/4012	4+ Group D Streptococcus; 1+ <i>Staphylococcus epidermidis</i> ; 3+ Coliform
282/4013	4+ Group D Streptococcus; 3+ Bacillus sp.; 4+ Coliform; 1+ <i>Pseudomonas aeruginosa</i>
283/4014	4+ Group D Streptococcus; 3+ Bacillus sp.; 4+ Coliform; 1+ <i>Pseudomonas aeruginosa</i>
284/4015	4+ Group D Streptococcus; 4+ Micrococcus sp.; 4+ Coliform; 3+ <i>Pseudomonas aeruginosa</i>
285/4016	4+ Group D Streptococcus; 3+ Micrococcus sp.; 4+ Coliform; 4+ <i>Candida brumptii</i>
286/4017	4+ Group D Streptococcus; 4+ Micrococcus sp.; 4+ Coliform; 1+ <i>Proteus vulgaris</i> ; 1+ <i>Pseudomonas aeruginosa</i> ; 4+ <i>Candida brumptii</i>

(a) Date of specimen: 5/30/78

(b) Lung, spleen, feces, and tracheal wash were examined for each specimen; no growth observed in the spleen or lung; no mycoplasma isolated from tracheal washings.

TABLE C5. REPEATED MURINE VIRUS ANTIBODY DETERMINATION IN F₀ RATS IN THE LIFETIME FEED STUDIES OF TREMOLITE

Sample Number	Complement Fixation	
	Sendai	LCM
3934	--	--
3935	--	--
3936	--	--
3937	--	--
3938	--	--
3940	--	--
3941	--	--
3942	--	--
3943	--	--
3944	--	--
3945	--	--
3946	--	--
3947	--	--
3948	--	--
Significant titer	10	10

TABLE C6. REPEATED INDIVIDUAL HISTOPATHOLOGIC FINDINGS IN F₀ RATS IN THE LIFETIME FEED STUDIES OF TREMOLITE

Site/Lesion	Animal Number:	Control					1% Tremolite				
		Male		Female			Male		Female		
		2	2	2	2	2	2	2	2	2	2
		7	7	7	8	8	8	8	8	8	8
		7	8	9	0	1	2	3	4	5	6
Brain		X	X	X	X	X	X	X	X	X	O
Heart		X	X	X		X	X	X	X	X	X
Focal nonsuppurative myocarditis					1						
Lung											
Peribronchial lymphoid hyperplasia		2	3	2	2	2	2	3	2	1	2
Bronchial exudate			P	P		P					
Spleen				X	X						X
Pigment deposition		2	2			2	2	3	2	1	
Liver				X	X		X	X	X	X	O
Microgranulomas		P									
Foci of mononuclear cells			P			P					
Kidney						X		X		O	
Chronic interstitial nephritis		1	1	1							
Foci of mineralization		P			P		P		P		P
Small intestine		X	X	X	X	X	X	X	O	X	X
Large intestine		X	X	X		X	X	X	O	X	X
Nematodiasis					P						
Salivary gland		O	O	O	O	O	X	X	X	X	X
Urinary bladder		X	X	X	X	O	X	X	X	O	X
Harderian gland		O	O	O	X	X	X	O	X	O	X
Skin		O	O	O	X	X	X	X	O	X	O
Anus		X	X	X	X	X	X	X	O	X	X
Cecum		X	X	X	X	X	X	X	O	X	X
Tissue mass											
Mammary fibroadenoma											P

Type of Finding:

- O = Tissue absent
- X = Tissue examined and not remarkable
- P = Finding present

Degree of Finding:

- 1 = Minimal
- 2 = Slight
- 3 = Moderate
- 4 = Moderately severe
- 5 = Severe

Pathogen Burden Summary (F₁)

Sections of brain, heart, lung, spleen, liver, kidney, small intestine, large intestine, salivary gland, urinary bladder, harderian gland, skin, anus, and cecum were examined from eight male and eight female rats killed for pathology burden.

Evidence of early spontaneous respiratory disease was present in the lungs of all rats examined. This was characterized by minimal-to-slight peribronchial lymphoid hyperplasia.

In sections of kidney, focal intratubular mineralization was noted at the corticomedullary junction in all but one female.

In the skin section of one female, a focus of dermatitis was noted with a microabscess in the epidermis.

The remaining tissues examined were not remarkable.

TABLE C7. MICROSCOPIC EXAMINATION FOR ENDOPARASITES AND BACTERIA IN F₁ RATS IN THE LIFETIME FEED STUDIES OF TREMOLITE

Animal/Specimen Number (a)	Micro-organisms Identified (b)
229/3933	4+ Group D Streptococcus; 3+ <i>Staphylococcus epidermidis</i> ; 1+ Coliform; 1+ <i>Proteus vulgaris</i>
230/3934	4+ Group D Streptococcus; 3+ Coliform; 3+ Micrococcus sp.; 1+ <i>Staphylococcus epidermidis</i>
231/3935	4+ Group D Streptococcus; 1+ <i>Staphylococcus epidermidis</i> ; 3+ Coliform; 2+ Bacillus sp.; 2+ <i>Pseudomonas aeruginosa</i>
237/3936	4+ Group D Streptococcus; 3+ Micrococcus sp.; 3+ Coliform
238/3937	4+ Group D Streptococcus; 3+ Micrococcus sp.; 3+ Coliform
239/3938	4+ Group D Streptococcus; 3+ Micrococcus sp.; 3+ Gamma Streptococcus; 3+ <i>Candida albicans</i> ; 3+ Coliform
232/3939	4+ Group D Streptococcus; 1+ Coliform; 2+ Micrococcus sp.; 3+ <i>Staphylococcus epidermidis</i>
233/3940	4+ Group D Streptococcus; 4+ Micrococcus sp.; 4+ Diphtheroids; 1+ <i>Pseudomonas aeruginosa</i>
234/3941	4+ Group D Streptococcus; 4+ Coliform; 4+ Micrococcus sp.; 4+ Diphtheroids; 3+ <i>Proteus vulgaris</i>
235/3942	4+ Group D Streptococcus; 1+ Coliform
236/3943	4+ Group D Streptococcus; 4+ Coliform; 1+ Micrococcus sp.; 1+ <i>Proteus morgani</i>
240/3944	4+ Group D Streptococcus; 4+ Coliform; 1+ Micrococcus sp.; 1+ <i>Proteus vulgaris</i>
241/3945	4+ Group D Streptococcus; 4+ Coliform; 1+ <i>Pseudomonas aeruginosa</i>
242/3946	4+ Group D Streptococcus; 1+ Coliform; 1+ Micrococcus sp.; 1+ <i>Proteus morgani</i>
243/3947	4+ Group D Streptococcus; 3+ Coliform; 1+ <i>Proteus vulgaris</i>
244/3948	4+ Group D Streptococcus; 3+ Coliform

(a) Date of specimen: 4/13/78

(b) Lung, spleen, feces, and tracheal wash were examined for each specimen; no growth observed in the spleen or lung; no mycoplasma isolated from tracheal washings.

TABLE C8. MURINE VIRUS ANTIBODY DETERMINATION IN F₁ RATS IN THE LIFETIME FEED STUDIES OF TREMOLITE

Sample Number	Complement Fixation	
	Sendai	LCM
4008	—	—
4009	—	—
4010	—	—
4011	—	—
4012	—	—
4013	—	—
4014	—	—
4015	—	—
4016	—	—
4017	—	—
Significant titer	10	10

TABLE C9. INDIVIDUAL HISTOPATHOLOGIC FINDINGS IN F₁ RATS IN THE LIFETIME FEED STUDIES OF TREMOLITE

Site/Lesion	Animal Number:	Control						1% Tremolite									
		Male			Female			Male					Female				
		2	2	2	2	2	2	2	2	2	2	2	2	2	2	2	2
		2	3	3	3	3	3	3	3	3	3	3	4	4	4	4	4
		9	0	1	7	8	9	2	3	4	5	6	0	1	2	3	4
Brain		X	X	X	X	X	X	X	X	X	X	X	X	X	X	X	X
Heart		X	X	X	X	X	X	X	X	X	X	X	X	X	X	X	X
Lung																	
Peribronchial lymphoid hyperplasia		1	2	1	1	2	1	1	2	2	2	2	2	1	2	2	1
Liver		X	X	X	X	X	X	X	X	X	X	X	X	X	X	X	X
Kidney		X	X	X				X	X	X	X	X					X
Focal mineralization					P	P	P						P	P	P	P	
Small intestine		X	X	X	X	X	X	X	X	X	X	X	X	X	X	X	X
Large intestine		X	X	X	X	X	X	X	X	X	X	X	X	X	X	X	X
Salivary gland		X	X	X	X	X	X	X	O	X	X	X	X	X	X	X	X
Urinary bladder		X	X	X	X	X	O	X	X	X	X	X	O	X	X	X	O
Harderian gland		X	X	X	X	X	X	X	X	X	O	X	X	X	O	O	X
Skin		X	X	X	X	O	X	X	X	X	X	X	X	X		X	X
Microabscess															P		
Focal dermatitis															P		
Anus		X	X	X	X	X	O	X	X	X	X	X	X	X	X	X	X
Cecum		X	X	X	X	X	X	O	X	X	X	X	X	X	X	X	X

Type of Finding:

- O = Tissue absent
- X = Tissue examined and not remarkable
- P = Finding present

Degree of Finding:

- 1 = Minimal
- 2 = Slight
- 3 = Moderate
- 4 = Moderately severe
- 5 = Severe

APPENDIX D

ANALYSIS OF BEDDING SAMPLES IN THE LIFETIME FEED STUDIES OF TREMOLITE

		PAGE
TABLE D1	ANALYSIS OF BEDDING SAMPLES AT HAZLETON LABORATORIES	170
TABLE D2	ANALYSIS OF BEDDING SAMPLES AT ILLINOIS INSTITUTE OF TECHNOLOGY RESEARCH INSTITUTE	170

TABLE D1. ANALYSIS OF BEDDING SAMPLES AT HAZLETON LABORATORIES

Collection Date	Desired Level (ppm)	Determined Level of Pentachlorophenol (ppm)	Determined Level of Polychlorinated Biphenyls (ppm)
07/78	<1.0	6.0	<0.5
08/78	<1.0	<0.5	<0.5
08/79	<1.0	<0.2	<0.5
01/80	<1.0	<0.2	<0.5
08/80	<1.0	<0.2	<0.5

TABLE D2. ANALYSIS OF BEDDING SAMPLES AT ILLINOIS INSTITUTE OF TECHNOLOGY RESEARCH INSTITUTE

Collection Date	Fiber Concentration	
	Total (a)	Asbestos (a)
03/77	110/g	ND
03/79	90/g	ND
02/80	130/g	ND
08/80	40/g	ND

(a) ND = less than detection limit (~ 25,000 fibers per liter or 25 fibers per gram)

APPENDIX E

WATER ANALYSIS IN THE LIFETIME FEED STUDIES OF TREMOLITE

APPENDIX E. WATER ANALYSIS

Samples of drinking water were submitted to the Water Supply Research Laboratory, U.S. Environmental Protection Agency, Cincinnati, OH, for baseline asbestos determinations. The samples were collected on November 8, 1976, and November 11, 1980.

The results of the first analysis determined the concentration of chrysotile asbestos and amphibole asbestos to be below detectable limits of 10,000 fibers per liter.

The second analysis detected one chrysotile asbestos fiber, equivalent to 50,000 fibers per liter, but a count based on a single fiber is not statistically significant. The chrysotile asbestos fiber was probably a contaminant from the study diet.

APPENDIX F

AIR ANALYSIS IN THE LIFETIME FEED STUDIES OF TREMOLITE

	PAGE
TABLE F1 RESULTS OF ANALYSES OF AIR SAMPLES IN LIFETIME FEED STUDIES OF TREMOLITE IN RATS	175

APPENDIX F. ANALYSIS OF AIR SAMPLES

Initially, 6-hour samplings of air were taken for baseline asbestos determinations from clean and dirty corridors and from one room. Samples were sent for analysis to the Illinois Institute of Technology Research Institute (IITRI). Additional 6-hour air samplings of rooms and corridors were taken when each asbestos diet was introduced into a room and approximately every 6 months thereafter.

Air samples were obtained with a portable pump Model G (part no. 456058) from Mining Safety Appliances Co. (Pittsburgh, PA), which was connected by Tygon tubing to a Millipore Filter Field Monitor (pore size, 5 μ). Results of air sample analyses are presented in Table F1.

TABLE F1. RESULTS OF ANALYSES OF AIR SAMPLES IN LIFETIME FEED STUDIES OF TREMOLITE IN RATS (a)

Date	Room No. 32 (next to return hall door)	Service Hall (outside room no. 30)	Room No. 35 (next to service hall door)	Return Hall Intersection of Nos. 45 and 44	Room No. 36 (next to return hall door)
Total Fiber Concentration (no./cc of air)					
6/78	0.06	0	0	0	0
1/79	0.17	0.04	0.04		0.30
2/80	0.095		0.048		
7/80	0.11	0.09	0.03		0
Asbestos Fiber Concentration (no./cc of air)					
6/78	0.06	0	0	0	0
1/79	0.13	0.04	0		0.17
2/80	0.095		0		
7/80	0.03	0.03	0.03		0
>5 μm (no./cc of air)					
6/78	0	0		0	0
1/79	0	0	0		0
2/80	0		0		
7/80	0	0	0		0
>1 μm (no./cc of air)					
6/78	0	0		0	0
1/79	0.13	0	0		0.14
2/80	0		0		
7/80	0	0	0.03		0

Date	Service Hall Intersection of Nos. 29 and 55	Room No. 33 (next to return hall door)	Return Hall (No. 20) Outside of Women's Locker Room	Room No. 30 (next to return hall door)	Service Hall
Total Fiber Concentration (no./cc of air)					
6/78	0.12	(b)0	0	0	
1/79		0.11		0.04	0.04
2/80		0.00			
7/80		0.11		0.34	
Asbestos Fiber Concentration (no./cc of air)					
6/78	0.06	(b)0	0	0	
1/79		0.04		0.04	0
2/80		0.00			
7/80		0.03		0.23	
>5 μm (no./cc of air)					
6/78	0	(b)0	0	0	
1/79		0		0	0
2/80		0			
7/80		0		0	
>1 μm (no./cc of air)					
6/78	0	(b)0	0	0	
1/79		0		0	0
2/80		0			
7/80		0.03		0.11	

TABLE F1. RESULTS OF ANALYSES OF AIR SAMPLES IN LIFETIME FEED STUDIES OF TREMOLITE IN RATS (Continued)

Date	Return Hall	Service Hall (halls 55 and 56)	Room 31	Room 34	Blank
Total Fiber Concentration (no./cc of air)					
6/78					
1/79	0.07		0.13	0.17	0.04
2/80	0.048	0.048	0.048	0.24	
7/80		0.26	0.03	0.20	0.03
Asbestos Fiber Concentration (no./cc of air)					
6/78					
1/79	0.04		0.04	0.04	0
2/80	0.048	0.048	0	0.14	
7/80		0.20	0.03	0.09	0
>5 μm (no./cc of air)					
6/78					
1/79	0		0	0	0
2/80	0	0	0	0	
7/80		0.06	0	0	0
>1 μm (no./cc of air)					
6/78					
1/79	0		0	0.04	0
2/80	0	0	0	0.05	
7/80		0.14	0	0.06	0

Date	Service Hall	Wash Area Room 48	Change Area	Room 56
Total Fiber Concentration (no./cc of air)				
6/78				
1/79	0			
2/80				
7/80		0.06	0.11	0.09
Asbestos Fiber Concentration (no./cc of air)				
6/78				
1/79	0			
2/80				
7/80		0	0.03	0.09
>5 μm (no./cc of air)				
6/78				
1/79	0			
2/80				
7/80		0	0	0
>1 μm (no./cc of air)				
6/78				
1/79	0			
2/80				
7/80		0	0.03	0.09

(a) Samples analyzed by IITRI; the computations are based on a 1 liter/min sample rate and a 6-h sample period = 360 min.
 (b) Sample holder was damaged.

APPENDIX G

SUMMARY OF CLINICAL SIGNS OBSERVED PRIOR TO MORIBUND KILL IN THE LIFETIME FEED STUDIES OF TREMOLITE

		PAGE
TABLE G1	SUMMARY OF CLINICAL SIGNS OBSERVED IN RATS BEFORE MORIBUND KILL IN THE LIFETIME FEED STUDIES OF TREMOLITE: CONTROL	178
TABLE G2	SUMMARY OF CLINICAL SIGNS OBSERVED IN RATS BEFORE MORIBUND KILL IN THE LIFETIME FEED STUDIES OF TREMOLITE: 1%	179

TABLE G1. SUMMARY OF CLINICAL SIGNS OBSERVED IN RATS BEFORE MORIBUND KILL IN THE LIFETIME FEED STUDIES OF TREMOLITE: CONTROL (a)

	<u>Weeks 83-87</u>		<u>Weeks 88-92</u>		<u>Weeks 93-97</u>		<u>Weeks 98-102</u>	
	Male	Female	Male	Female	Male	Female	Male	Female
Number of animals killed in moribund condition	2	2	1	1	4	2	2	1
Pale				1	1	1		
Thin		2			1	2		1
Hunched		1						
Bloody crust around nose						1		
Pale eyes					1			
Bloody crust around eye(s)		1				1		
Head tilt		1						
Depressed		1			2	2		1
Circling		1						
Loss of equilibrium						1		
Loss of righting reflex								1
Ataxia		1						
Palpable mass in abdomen		1			1	1		
Tissue mass (abscessed)--lower midline, chest, side of back, forelimb, head, neck, or side of body	2		1		1	1		
Abdomen distended and/or dark					2		1	
Abdomen firm							1	
Paralysis (flaccid) in hind legs							1	
Extremities yellow		1						
Discharge (red) from anus				1				
Urine stains						1		
			<u>Weeks 103-107</u>		<u>Weeks 108-112</u>			
			Male	Female	Male	Female		
Number of animals killed in moribund condition			7	7	9	4		
Pale			4	4	4	3		
Thin			4	1	7	2		
Hunched					2			
Pale eyes					1			
Head tilt					1			
Depressed			3	4	3	2		
Labored respiration					1			
Loss of equilibrium			1	1	2			
Loss of righting reflex				1				
Nodule--neck, head					1			
Palpable mass in abdomen			3	4	2	1		
Tissue mass (abscessed)--lower midline, chest, side of back, forelimb, head, neck, or side of body			2	2	2	1		
Abscessed area--perineal region						1		
Abdomen distended and/or dark			1					
Dark wet stains entire ventral surface						1		
Animal prostrate in cage						1		
Swelling around neck				1				
Cyanotic			1					
Unkempt			1			1	1	
Inactive						1		
Discharge (red) from penis						1		
Discharge (brown) from vagina				1				
Discharge (red) from anus				1				

(a) The intervals were arbitrarily selected based on weeks when a large percentage of moribund kills occurred. Clinical signs observed after the last interval selected were believed not to be readily discernible from signs of aging.

TABLE G2. SUMMARY OF CLINICAL SIGNS OBSERVED IN RATS BEFORE MORIBUND KILL IN THE LIFETIME FEED STUDIES OF TREMOLITE: 1% (a)

	<u>Weeks 83-87</u>		<u>Weeks 88-92</u>		<u>Weeks 93-97</u>		<u>Weeks 98-102</u>	
	Male	Female	Male	Female	Male	Female	Male	Female
Number of animals killed in moribund condition	6	3	5	5	3	8	6	7
Pale			1	1	2	3	2	4
Thin	2	1	2	1	2	5	3	3
Hunched	1		1					
Lacrimating eyes	1							
Bloody crust or red stains around eyes				1				
Pale eyes	1		2			2	1	
Head tilt		1			1		1	2
Malocclusion						1		1
Rapid respiration	1			1				
Labored respiration	1				1	1		1
Wheezing	1					1		1
Cyanotic								1
Depressed			1	3	3	2	2	4
Inactive							1	
Abdomen distended and/or dark					2			
Palpable mass in abdomen	2	1	3	1	2	4	4	3
Tissue mass (abscessed)--axilla, thoracic region, sacral region, hind leg, mouth, ear, chest, head, midline, flank, or shoulder	1	2	3		1	5	4	2
Rough hair coat	1		1					
Alopecia	1							1
Prostrate in cage	1			2		1		
Loss of pain perception				1				
Flaccid muscle tone	1			1		1		
Circling					1			
Ataxia				1				
Loss of coordination or equilibrium							1	2
Paralysis (flaccid) in hind legs	1							
Swollen and stiff leg				1				
Yellow tinge			2				1	
Cold to touch	1			1	1	2		
Unkempt							1	
Aggressive behavior								1
Urine stains					1	1		
Weight loss							1	

	<u>Weeks 103-107</u>		<u>Weeks 108-112</u>	
	Male	Female	Male	Female
Number of animals killed in moribund condition	9	10	12	15
Pale	2	2	4	7
Thin	4	7	4	3
Hunched			2	1
Bloody crust or red stains around eyes		1		
Pale eyes				1
Dark eyes	1			
Head tilt	1	1		
Malocclusion			1	
Salivating				1
Depressed	2	4	2	3
Inactive	1			
Nodule(s)		1	1	1
Protruding anal nodule				1
Abdomen distended or dark			1	
Palpable mass in abdomen	5	3	6	11
Tissue mass (abscessed)--axilla, thoracic region, sacral region, hind leg, mouth, chest, head, midline, flank, or shoulder	1	3	3	5
Circling	1			
Loss of coordination or equilibrium	3	2		
Paralysis (flaccid) in hind legs	1		2	
Unkempt	1			1
Urine stains		1		
Weight loss		1		
Enlarged testes	1			
Vaginal discharge		1		

(a) The intervals were arbitrarily selected based on weeks when a large percentage of moribund kills occurred. Clinical signs observed after the last interval selected were believed not to be readily discernible from signs of aging.

APPENDIX H

FEED AND COMPOUND CONSUMPTION BY RATS IN THE LIFETIME FEED STUDIES OF TREMOLITE

		PAGE
TABLE H1	FEED AND COMPOUND CONSUMPTION BY MALE RATS FOR REPRESENTATIVE WEEKS IN THE LIFETIME FEED STUDY OF TREMOLITE	182
TABLE H2	FEED AND COMPOUND CONSUMPTION BY FEMALE RATS FOR REPRESENTATIVE WEEKS IN THE LIFETIME FEED STUDY OF TREMOLITE	183

**TABLE H1. FEED AND COMPOUND CONSUMPTION BY MALE RATS FOR REPRESENTATIVE WEEKS
IN THE LIFETIME FEED STUDY OF TREMOLITE**

Week	Control		1% Tremolite		
	Grams Feed/ Day (a)	Body Weight (grams)	Grams Feed/ Day (a)	Body Weight (grams)	Dose/Day (c)
17	17	350	16	252	635
27	17	348	17	307	554
37	17	395	17	341	499
47	17	390	17	357	476
57	17	429	16	386	415
67	19	463	18	416	433
77	17	469	17	426	399
87	17	466	15	432	347
97	18	461	14	427	328
107	17	444	16	418	383
117	16	420	16	396	404
127	15	398	16	368	435
137	16	367	17	348	489
Mean	16.9	415	16.3	375	446
SD (d)	1.0		1.0		84.6
CV(e)	5.6		6.3		19.0

(a) Grams of feed removed from the feeder per animal per day; not corrected for scatter.

(b) Grams of feed per day for the dosed group divided by that for the controls

(c) Estimated milligrams of tremolite consumed per day per kilogram of body weight

(d) Standard deviation

(e) Coefficient of variation = (standard deviation/mean) × 100

TABLE H2. FEED AND COMPOUND CONSUMPTION BY FEMALE RATS FOR REPRESENTATIVE WEEKS IN THE LIFETIME FEED STUDY OF TREMOLITE

Week	Control		1% Tremolite		Dose/Day (c)
	Grams Feed/ Day (a)	Body Weight (grams)	Grams Feed/ Day (a)	Body Weight (grams)	
17	12	182	11	166	663
27	13	199	12	185	649
37	12	220	12	199	603
47	12	224	13	214	607
57	13	251	13	233	558
67	14	281	13	265	491
77	14	303	14	277	505
87	15	323	12	298	403
97	14	323	12	295	407
107	14	330	14	303	462
117	13	320	14	293	478
127	13	316	(d) 29	286	(e) 1,014
137	14	299	14	264	530
147	13	283	13	255	510
Mean	13.3	275	14.0	252	563
SD (f)	0.9		4.4		153.0
CV(g)	6.9		31.6		27.2

(a) Grams of feed removed from the feeder per animal per day; not corrected for scatter.

(b) Grams of feed per day for the dosed group divided by that for the controls

(c) Estimated milligrams of tremolite consumed per day per kilogram of body weight

(d) If this value is excluded, the mean and standard deviation are 12.8 and 1.0.

(e) If this value is excluded, the mean and standard deviation are 528 and 84.2.

(f) Standard deviation

(g) Coefficient of variation = (standard deviation/mean) × 100