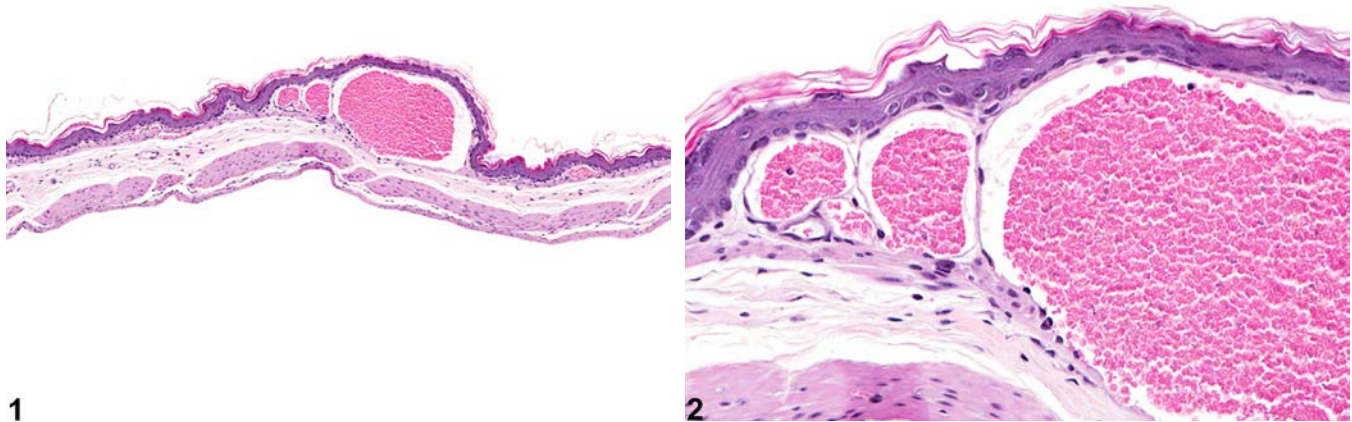


NTP Nonneoplastic Lesion Atlas

Stomach, Forestomach – Angiectasis



1

2

Figure Legend: **Figure 1** Stomach, Forestomach - Angiectasis in a male B6C3F1 mouse from a chronic study. There are several cross sections of dilated blood vessels in the lamina propria. **Figure 2** Stomach, Forestomach - Angiectasis in a male B6C3F1 mouse from a chronic study (higher magnification of Figure 1). The endothelial cells lining the dilated vessel are unremarkable.

Comment: Angiectasis (vascular ectasia) is primarily a spontaneous, age-related lesion. The cause is generally not known but occasionally can be a response to chemical injury. Angiectasis consists of widely dilated vascular spaces, especially capillaries (or sinusoids) and venules, that are lined by unremarkable endothelial cells. There is no apparent increase in numbers of vessels, and the stroma of the organ is unaltered. A differentiation between angiectasis and hemangioma should be attempted, although the difference between angiectasis and hemangioma often is not clear. Hemangiomas tend to be well-circumscribed unencapsulated masses composed of tightly packed dilated vascular spaces. Each vascular space is enclosed and lined by a single layer of normal-appearing endothelial cells aligned on collagenous septa, which are usually thin, although some have broad collagenous stromata. Angiectasis does not usually present as a well-circumscribed mass because the dilated vascular channels are often irregularly coursing through connective.

Recommendation: Angiectasis should be diagnosed and given a severity grade based on the extent of the lesion.



NTP Nonneoplastic Lesion Atlas

Stomach, Forestomach – Angiectasis

References:

Boorman GA, Everitt JI. 2006. Neoplastic diseases. In: The Laboratory Rat, 2nd ed (Suckow MA, Weisbroth SH, Franklin CL, eds). Elsevier Academic Press, Burlington, MA, 479-511.

Abstract: <http://www.sciencedirect.com/science/book/9780120749034>

Gad S. 2007. The mouse. In: Animal Models of Toxicology, 2nd ed (Gad S, ed). CRC Press, Boca Raton, FL, 19-146.

Abstract: <http://www.crcnetbase.com/isbn/9781420014204>

Gross TL, Ihrke PJ, Walder EJ, Affolter VK. 2005. Vascular tumors. In: Veterinary Dermatopathology, 2nd ed. Blackwell, Oxford, UK, 735-758.

Mitsumori K. 1990. Blood and lymphatic vessels. In: Pathology of the Fischer Rat (Boorman GA, Montgomery CA, MacKenzie WF, eds). Academic, San Diego, CA, 473-484.

Abstract: <http://www.ncbi.nlm.nih.gov/nlmcatalog/9002563>

Authors:

Linda H. Kooistra, DVM, PhD, DACVP
Pathologist
Charles River Laboratories, Inc.
Research Triangle Park, NC

Abraham Nyska, DVM, Diplomate ECVP, Fellow IATP
Expert in Toxicologic Pathology
Visiting Full Professor of Pathology
Sackler School of Medicine, Tel Aviv University
Timrat Israel