

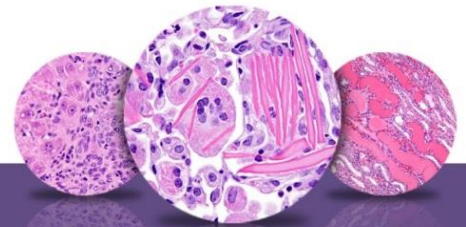
NTP Nonneoplastic Lesion Atlas

Stomach, Forestomach – Introduction

Information on the following lesions is available in this section:

- Stomach, Forestomach - Angiectasis
- Stomach, Forestomach - Cyst
- Stomach, Forestomach - Diverticulum
- Stomach, Forestomach - Ectopic Tissue
- Stomach, Forestomach - Edema
- Stomach, Forestomach, Epithelium - Degeneration
- Stomach, Forestomach, Epithelium - Hyperplasia, Atypical
- Stomach, Forestomach, Epithelium - Hyperplasia, Focal, Diffuse
- Stomach, Forestomach - Erosion
- Stomach, Forestomach - Fibrosis
- Stomach, Forestomach - Foreign Body
- Stomach, Forestomach - Hemorrhage
- Stomach, Forestomach - Hyperkeratosis
- Stomach, Forestomach - Inflammation
- Stomach, Forestomach - Mineralization
- Stomach, Forestomach - Necrosis
- Stomach, Forestomach - Parasite, Metazoan
- Stomach, Forestomach - Perforation
- Stomach, Forestomach - Ulcer

Click the tabs in the left-hand column.



NTP Nonneoplastic Lesion Atlas

Stomach, Forestomach – Introduction

Authors:

Linda H. Kooistra, DVM, PhD, DACVP
Pathologist
Charles River Laboratories, Inc.
Research Triangle Park, NC

Abraham Nyska, DVM, Diplomate ECVP, Fellow IATP
Expert in Toxicologic Pathology
Visiting Full Professor of Pathology
Sackler School of Medicine, Tel Aviv University
Timrat Israel