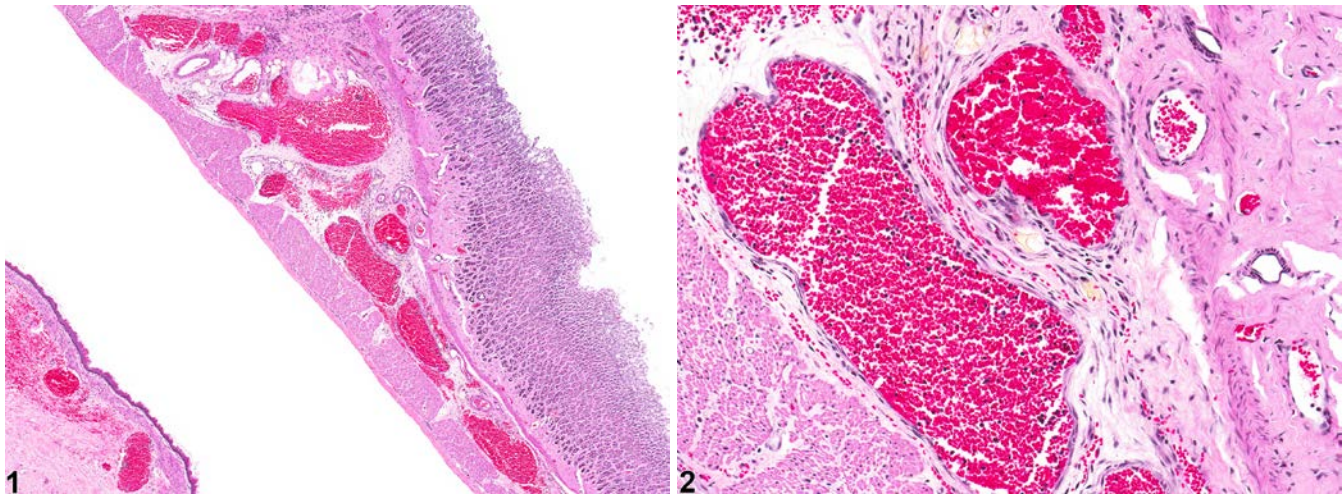


# NTP Nonneoplastic Lesion Atlas

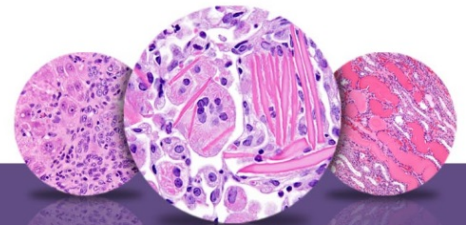
## Stomach, Glandular Stomach – Angiectasis



**Figure legend:** **Figure 1** Stomach, Glandular stomach - Angiectasis in a male F344/N rat from a chronic study. Dilated blood vessels are present in the submucosa of the glandular stomach. **Figure 2** Stomach, Glandular stomach - Angiectasis in a male F344/N rat from a chronic study (higher magnification of Figure 1). The endothelial cells in the dilated vessels have a normal appearance.

**Comment:** Angiectasis (vascular ectasia) is primarily a spontaneous age-related lesion. The cause is generally not known but occasionally can be a response to chemical injury. Angiectasis consists of widely dilated vascular spaces, especially capillaries (or sinusoids) and venules, that are lined by unremarkable endothelial cells. There is no apparent increase in numbers of vessels, and the stroma of the organ is unaltered. A distinction between angiectasis and hemangioma should be attempted, although the difference between angiectasis and hemangioma is sometimes not obvious. Hemangiomas tend to be well-circumscribed unencapsulated masses composed of tightly packed dilated vascular spaces. Each vascular space is enclosed and lined by a single layer of normal-appearing endothelial cells aligned on collagenous septa, which are usually thin, although some have broad collagenous stromata. Angiectasis does not usually present as a well-circumscribed mass as the dilated vascular channels are often irregularly coursing through connective tissue.

**Recommendation:** Angiectasis should be diagnosed and given a severity grade based on the extent of the lesion.



# NTP Nonneoplastic Lesion Atlas

## *Stomach, Glandular Stomach – Angiectasis*

### References:

Boorman GA, Everitt JI. 2006. Neoplastic diseases. In: The Laboratory Rat, 2nd ed (Suckow MA, Weisbroth SH, Franklin CL, eds). Elsevier Academic Press, Burlington, MA, 479-511.

Abstract: <http://www.sciencedirect.com/science/book/9780120749034>

Gad S. 2007. The mouse. In: Animal Models of Toxicology, 2nd ed (Gad S, ed). CRC Press, Boca Raton, FL, 19-146.

Abstract: <http://www.crcnetbase.com/isbn/9781420014204>

Gross TL, Ihrke PJ, Walder EJ, Affolter VK. 2005. Vascular tumors. In: Veterinary Dermatopathology, 2nd ed. Blackwell, Oxford, UK, 735-758.

Mitsumori K. 1990. Blood and lymphatic vessels. In: Pathology of the Fischer Rat (Boorman GA, Montgomery CA, MacKenzie WF, eds). Academic Press, San Diego, CA, 473-484.

Abstract: <http://www.ncbi.nlm.nih.gov/nlmcatalog/9002563>

Roe FJC, Rowson KEK, Salaman MH. 1961. Tumours of many sites induced by injection of chemical carcinogens into newborn mice. A sensitive test for carcinogenesis: The implications for certain immunological theories. Br J Cancer 15:515-530.

Abstract: [www.ncbi.nlm.nih.gov/pmc/articles/PMC2071152/](http://www.ncbi.nlm.nih.gov/pmc/articles/PMC2071152/)

### Authors:

Linda H. Kooistra, DVM, PhD, DACVP  
Pathologist  
Charles River Laboratories, Inc.  
Research Triangle Park, NC

Abraham Nyska, DVM, Diplomate ECVP, Fellow IATP  
Expert in Toxicologic Pathology  
Visiting Full Professor of Pathology  
Sackler School of Medicine, Tel Aviv University  
Timrat Israel