

NTP Nonneoplastic Lesion Atlas

Thyroid Gland, Follicle – Mineralization

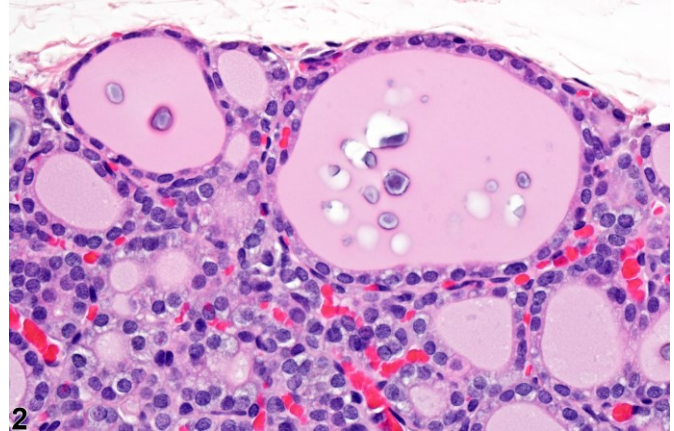
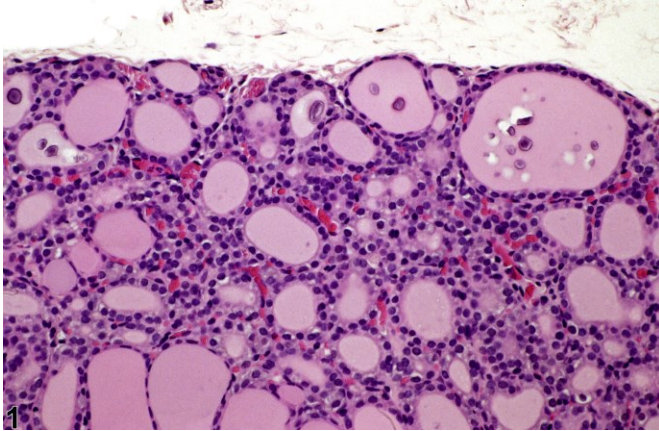


Figure Legend: **Figure 1** Thyroid gland, Follicle - Mineralization in a male F344/N rat from a chronic study. There is focal mineralization within the colloid of two follicles. **Figure 2** Thyroid gland, Follicle - Mineralization in a male F344/N rat from a chronic study. Higher magnification of Figure 1 Shows the focal mineral deposits in more detail.

Comment: Mineralization within solitary thyroid follicles is occasionally seen in adults and may appear as granular basophilic deposits not associated with inflammation.

Recommendation: Mineralization in the thyroid follicles is an incidental finding and should be documented and given a severity grade only when severe or suspected of being treatment related.

Authors:

Robert R. Maronpot, DVM, MS, MPH, DACVP, DABT, FIATP
Senior Pathologist
Experimental Pathology Laboratories, Inc.
Research Triangle Park, NC

Amy Brix, DVM, PhD, DACVP
Senior Pathologist
Experimental Pathology Laboratories, Inc.
Research Triangle Park, NC