

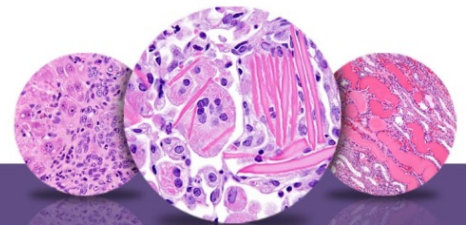
NTP Nonneoplastic Lesion Atlas

Ovary – Introduction

Information on the following lesions is available in this section:

- Ovary - Amyloid
- Ovary - Angiectasis
- Ovary - Atrophy
- Ovary, Bursa - Cyst
- Ovary, Corpus Luteum - Cyst
- Ovary - Cyst
- Ovary - Cyst, Epithelial
- Ovary, Epithelium - Hyperplasia
- Ovary - Fatty Change
- Ovary, Follicle - Cyst
- Ovary, Follicle - Polyovular
- Ovary - Hyperplasia, Sertoliform
- Ovary - Infiltration Cellular
- Ovary - Inflammation
- Ovary, Interstitial Cell - Hyperplasia
- Ovary - Mesonephric Duct Remnant
- Ovary - Metaplasia, Osseous
- Ovary - Mineral
- Ovary - Necrosis
- Ovary, Paraovarian Tissue - Cyst
- Ovary - Pigment
- Ovary - Thrombosis

Click the tabs in the left-hand column.



NTP Nonneoplastic Lesion Atlas

Ovary – Introduction

Authors:

Gabrielle Willson, BVMS, DipRCPath, FRCPath, MRCVS
Senior Pathologist
Experimental Pathology Laboratories, Inc.
Research Triangle Park, NC

Karen Y. Cimon, DVM, MS
Senior Pathologist
Experimental Pathology Laboratories, Inc.
Research Triangle Park, NC