

NTP Nonneoplastic Lesion Atlas

Liver, Hepatocyte – Increased mitosis

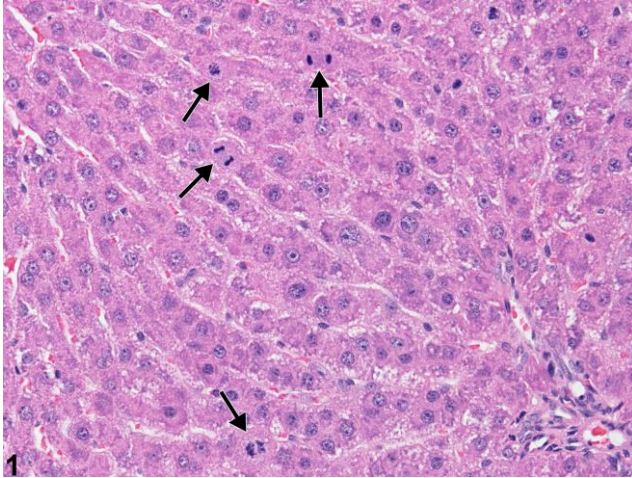
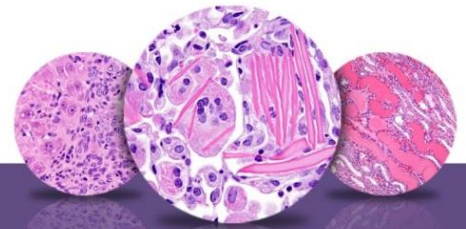


Figure Legend: **Figure 1** Increased mitosis (arrows) in a male F344/N rat from an acute repeated-dose study.

Comment: A high mitotic frequency can be seen during phases of early growth, during physiologic conditions such as pregnancy, or in rodents bearing tumors at other sites. While occasional mitoses can be seen in a normal liver, finding more than one or two mitoses per 10 high-power fields is not typical for adult rodents. In this example, the high frequency of mitosis (arrows) is a repair response following hepatocyte loss secondary to treatment with a hepatotoxicant.

Recommendation: An increased frequency of mitosis is unusual; it should be documented whenever present and given a qualitative severity grade.



NTP Nonneoplastic Lesion Atlas

Liver, Hepatocyte – Increased mitosis

References:

Echave Llanos JM, Aloisso MD, Souto M, Balduzzi R, Surur JM. 1971. Circadian variations of DNA synthesis, mitotic activity, and cell size of hepatocyte population in young immature male mouse growing liver. *Virchows Arch B Cell Pathol* 8:309–317.

Abstract: <http://www.ncbi.nlm.nih.gov/pubmed/4998660>

National Toxicology Program. 1993. NTP TR-394. Toxicology and Carcinogenesis Studies of Acetaminophen (CAS No. 103-90-2) in F344 Rats and B6C3F₁ Mice (Feed Studies). NTP, Research Triangle Park, NC.

Full-Text: http://ntp.niehs.nih.gov/ntp/htdocs/LT_rpts/tr394.pdf

Theologides A, Zaki GF. 1969. Mitotic index in the regenerating liver of tumor-bearing mice. *Cancer Res* 29:1913–1915.

Abstract: <http://www.ncbi.nlm.nih.gov/pubmed/5358208>

Thoolen B, Maronpot RR, Harada T, Nyska A, Rousseaux C, Nolte T, Malarkey D, Kaufmann W, Kutter K, Deschl U, Nakae D, Gregson R, Winlove M, Brix A, Singl B, Belpoggi F, Ward JM. 2010. Hepatobiliary lesion nomenclature and diagnostic criteria for lesions in rats and mice (INHAND). *Toxicol Pathol* 38:5S–81S.

Full-Text: http://tpx.sagepub.com/content/38/7_suppl/5S.full

Author:

Robert R. Maronpot, DVM, MS, MPH, DACVP, DABT, FIATP
Senior Pathologist
Experimental Pathology Laboratories, Inc.
Research Triangle Park, NC