



NTP Nonneoplastic Lesion Atlas

Spleen – Apoptosis, Lymphocyte

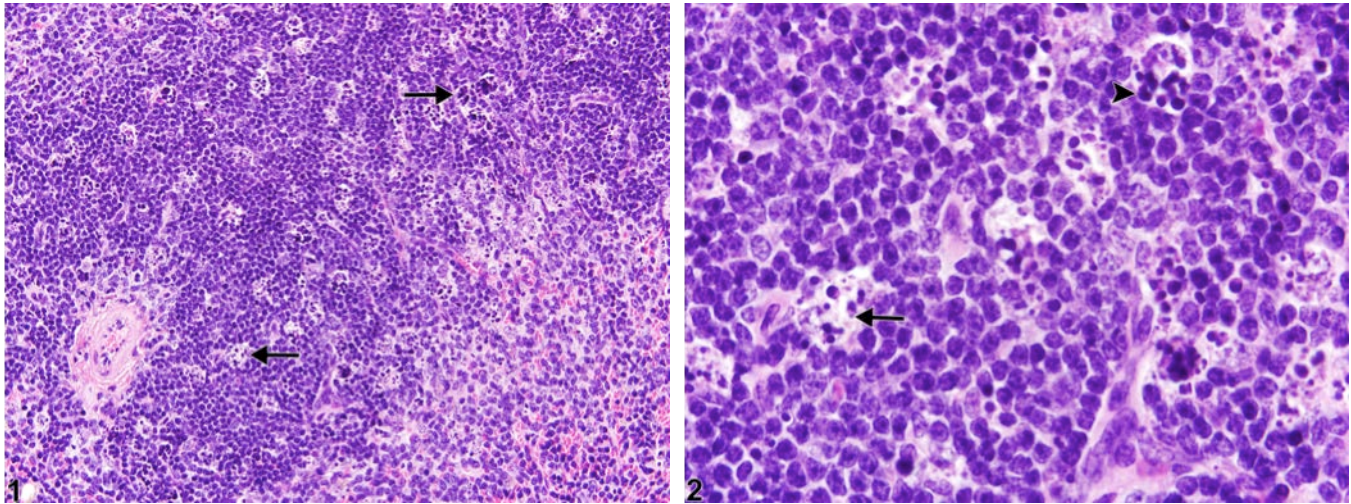


Figure Legend: **Figure 1** Spleen - Apoptosis, Lymphocyte in a female B6C3F1/N mouse from a subchronic study. Tingible body macrophages are scattered throughout the splenic white pulp (arrows).

Figure 2 Spleen - Apoptosis, Lymphocyte in a female B6C3F1/N mouse from a subchronic study (higher magnification of Figure 1). Tingible body macrophages (arrow) contain intracytoplasmic fragments of apoptotic lymphocytes (apoptotic bodies) (arrowhead).

Comment: Lymphocyte apoptosis normally occurs in the B-cell-rich follicular germinal centers of the spleen of rodents but may also be increased in B-cell and/or T-cell (periarteriolar lymphatic sheaths) compartments with experimental exposures to radiation, viruses, endotoxin, or chemicals. Apoptosis is characterized by shrinkage of individual lymphocytes, condensation of nuclear chromatin, and fragmentation of apoptotic cells into membrane-bound bodies (apoptotic bodies) (Figure 2, arrowhead), which are subsequently phagocytized by macrophages (tingible body macrophages) (Figure 1 and Figure 2, arrows). Significant lymphocyte apoptosis may lead to atrophy of one or more white pulp compartments. Historically, apoptosis of lymphocytes has been called “lymphocyte necrosis,” but the correct terminology for this lesion is “lymphocyte apoptosis.” A diagnosis of necrosis should be used when the predominant cytomorphology is consistent with the classic forms of necrosis (see Spleen - Necrosis). Necrosis is characterized by cell swelling, condensation, fragmentation and dissolution of the nucleus, cell lysis, and accumulation of abundant eosinophilic cytoplasmic and karyorrhectic nuclear debris. Inflammation is generally present with necrosis.



NTP Nonneoplastic Lesion Atlas

Spleen – Apoptosis, Lymphocyte

Recommendation: When increased above that seen in concurrent controls, lymphocyte apoptosis in the spleen should be diagnosed and assigned a severity grade. Lymphocyte apoptosis must be differentiated from splenic necrosis.

References:

Elmore SA. 2006. Enhanced histopathology of the spleen. *Toxicol Pathol* 34:648-655.
Full Text: <http://www.ncbi.nlm.nih.gov/pmc/articles/PMC1828535/>

National Toxicology Program. 2011. NTP TR-536. Bis(2-chloroethoxy)methane (CAS No. 111-91-1) in F344/N Rats and B6C3F1 Mice (Dermal Studies). NTP, Research Triangle Park, NC.
Abstract: <http://ntp.niehs.nih.gov/go/34791>

Stefanski SA, Elwell MR, Stromberg PC. 1990. Spleen, lymph nodes, and thymus. In: *Pathology of the Fischer Rat: Reference and Atlas* (Boorman GA, Eustis SL, Elwell MR, Montgomery CA, MacKenzie WF, eds). Academic Press, San Diego, 369-394.

Suttie AW. 2006. Histopathology of the spleen. *Toxicol Pathol* 34:466-503.
Full Text: <http://tpx.sagepub.com/content/34/5/466.full.pdf>

Ward JM, Mann PC, Morishima H, Frith CH. 1999. Thymus, spleen, and lymph nodes. In: *Pathology of the Mouse* (Maronpot RR, ed). Cache River Press, Vienna, IL, 333-360.

Authors:

Kristen Hobbie, DVM, PhD
Principal Pathologist
Huntingdon Life Sciences
Peterborough, UK

Susan A. Elmore, MS, DVM, DACVP, DABT, FIATP
Staff Scientist, NTP Pathologist
NTP Pathology Group
National Toxicology Program
National Institute of Environmental Health Sciences
Research Triangle Park, NC

Holly M. Kolenda-Roberts, DVM, PhD, DACVP
Veterinary Pathologist
SNBL USA
Everett, WA