

# NTP Nonneoplastic Lesion Atlas

## *Ductus deferens – Introduction*

Accessory sex organs in the male reproductive system, in addition to the prostate, include the seminal vesicles, preputial glands, ductus deferens, and penis. These tissues exhibit direct and indirect (often hormonal) pleiotropic pathological responses. A change in one reproductive tissue is often accompanied by changes in other reproductive tissues. The majority of the male reproductive tissues are paired, allowing identification of unilateral versus bilateral responses. Artifacts are rare.

Information on the following lesions is available in this section:

Ductus deferens - Inflammation

Ductus deferens - Mineralization

Click the tabs in the left-hand column.

### **References:**

Creasy DM, Foster P. 1991. Male reproductive system. In: Handbook of Toxicologic Pathology (Haschek E, Rousseaux C, eds). Academic Press, New York, 829-889.

Abstract: <http://www.sciencedirect.com/science/book/9780123302151>

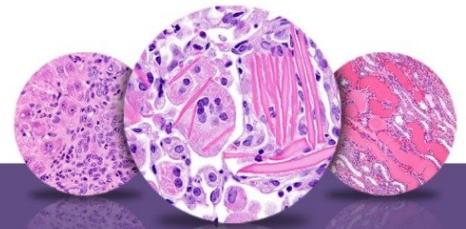
Creasy D, Bube A, de Rijk E, Kandori H, Kuwahara M, Masson R, Nolte T, Reams R, Regan K, Rehm S, Rogerson P, Whitney K. 2012. Proliferative and nonproliferative lesions of the rat and mouse male reproductive system. *Toxicol Pathol* 40:40S-121S.

Abstract: <http://www.ncbi.nlm.nih.gov/pubmed/22949412>

### **Authors:**

Dianne M. Creasy, PhD, Dip RCPATH, FRCPath  
Dianne Creasy Consulting LLC  
Pipersville, PA

Robert R. Maronpot, DVM, MS, MPH, DACVP, DABT, FIATP  
Senior Pathologist  
Experimental Pathology Laboratories, Inc.  
Research Triangle Park, NC



# NTP Nonneoplastic Lesion Atlas

## *Ductus deferens – Introduction*

### **Authors:**

Dipak K. Giri, DVM, PhD, DACVP  
Toxicologic Pathologist  
Integrated Laboratory Systems, Inc.  
Research Triangle Park, NC