

NTP Nonneoplastic Lesion Atlas

Penis – Introduction

Accessory sex organs in the male reproductive system, in addition to the prostate, include the seminal vesicles, preputial glands, ductus deferens, and penis. These tissues exhibit direct and indirect (often hormonal) pleiotropic pathologic responses. A change in one reproductive tissue is often accompanied by changes in other reproductive tissues. The majority of the male reproductive tissues are paired, allowing identification of unilateral versus bilateral responses. Artifacts are rare.

Information on the following lesions is available in this section:

Penis - Fibrosis

Penis, Epithelium - Hyperplasia

Penis - Inflammation

Penis, Prepuce - Inflammation

Click the tabs in the left-hand column.

References

Creasy DM, Foster P. 1991. Male reproductive system. In: Handbook of Toxicologic Pathology (Haschek E, Rousseaux C, eds). Academic Press, New York, 829-889.

Abstract: <http://www.sciencedirect.com/science/book/9780123302151>

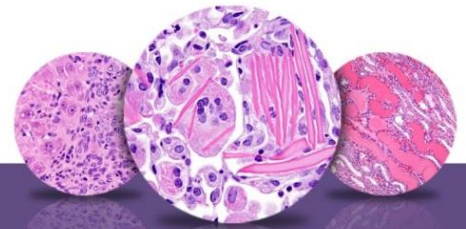
Creasy D, Bube A, de Rijk E, Kandori H, Kuwahara M, Masson R, Nolte T, Reams R, Regan K, Rehm S, Rogerson P, Whitney K. 2012. Proliferative and nonproliferative lesions of the rat and mouse male reproductive system. Toxicol Pathol 40:40S-121S.

Abstract: <http://www.ncbi.nlm.nih.gov/pubmed/22949412>

Authors:

Dianne M. Creasy, PhD, Dip RCPATH, FRCPath
Dianne Creasy Consulting LLC
Pipersville, PA

Robert R. Maronpot, DVM, MS, MPH, DACVP, DABT, FIATP
Senior Pathologist
Experimental Pathology Laboratories, Inc.
Research Triangle Park, NC



NTP Nonneoplastic Lesion Atlas

Penis – Introduction

Authors:

Dipak K. Giri, DVM, PhD, DACVP
Toxicologic Pathologist
Integrated Laboratory Systems, Inc.
Research Triangle Park, NC