Testis, Germinal epithelium – Atrophy

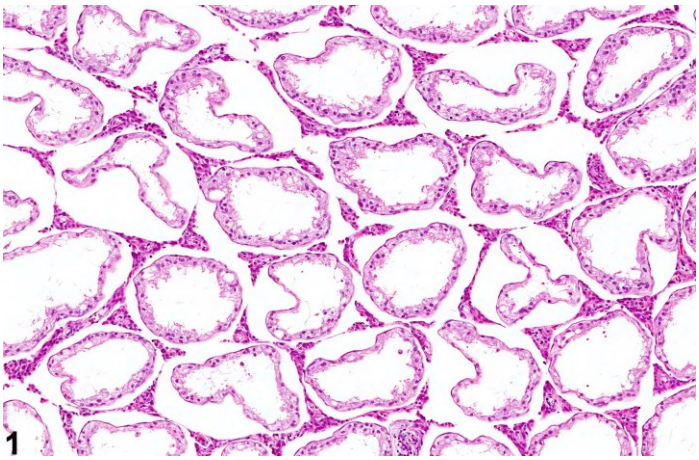

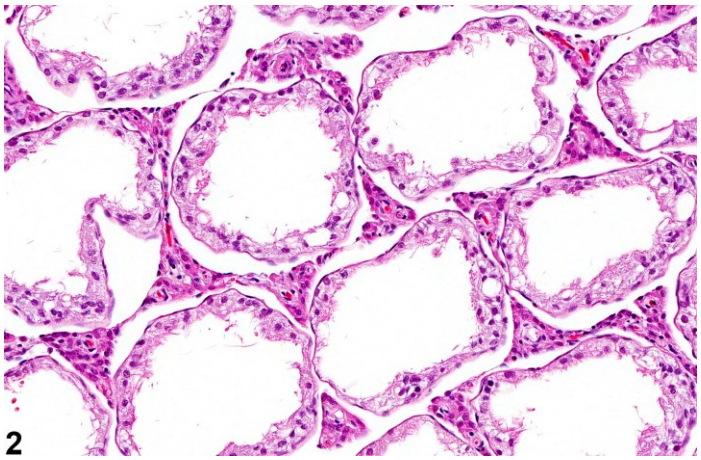

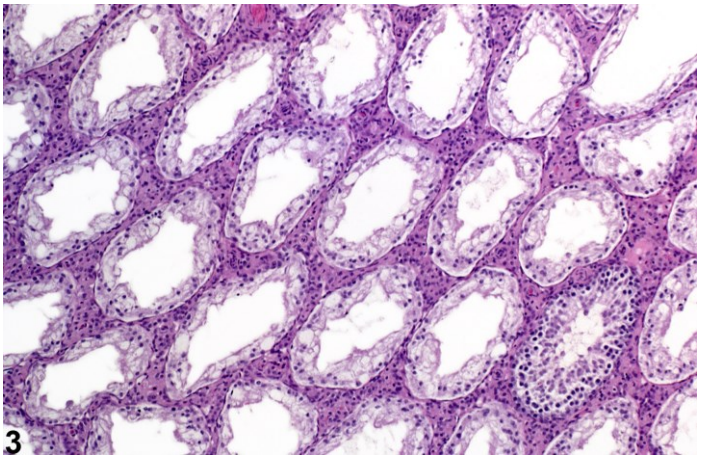

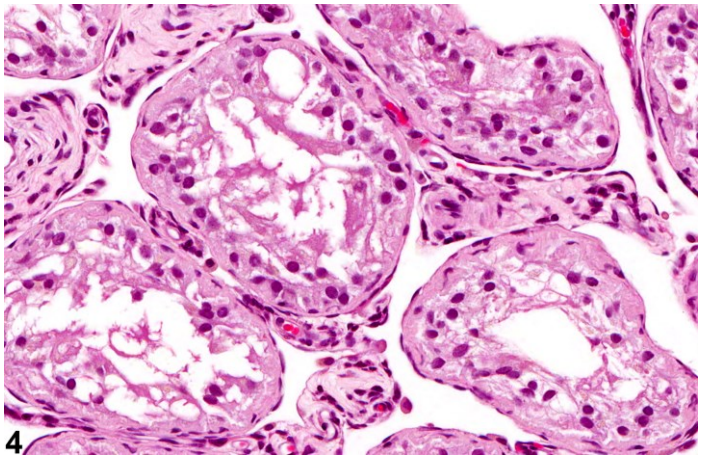

Figure Legend: Figure 1 Testis, Germinal epithelium - Atrophy in a male F344/N rat from a subchronic study. Seminiferous tubules are lined only by Sertoli cells. **Figure 2** Testis, Germinal epithelium - Atrophy in a male F344/N rat from a subchronic study. Higher magnification of Sertoli cell-lined seminiferous tubules in Figure 1. **Figure 3** Testis, Germinal epithelium - Atrophy in a male F344/N rat from a subchronic study. The majority of the seminiferous tubules are lined only by Sertoli cells. **Figure 4** Testis, Germinal epithelium - Atrophy in a male F344/N rat from a chronic study. Seminiferous tubules lack germ cells and are lined only by Sertoli cells.

Comment: Germinal epithelium atrophy (Figure 1, Figure 2, Figure 3, and Figure 4) consists of seminiferous tubules that are completely devoid of germ cells and lined only by Sertoli cells. The seminiferous tubules may have dilated lumens (Figure 1 and Figure 2) or contracted lumens (Figure 4).

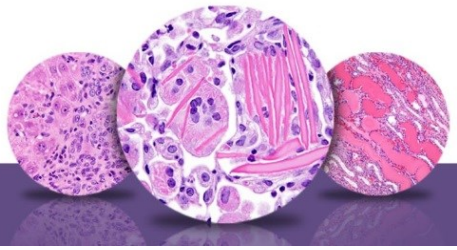

Testis, Germinal epithelium – Atrophy

If the tubular lumens are dilated, the atrophy is likely caused by pressure (i.e. pressure atrophy) from prolonged and severe tubular dilation (also see "Testis, Seminiferous tubule – Dilation") The change may be unilateral or bilateral and focal, multifocal, or diffuse and occurs as an occasional incidental finding in mice and rats at all ages, with the incidence increasing with age. Germinal epithelial atrophy is an end-stage lesion and is generally preceded, or accompanied by, seminiferous tubule degeneration. Depending on severity, the affected testes may be macroscopically flaccid and reduced in size and weight. Severe, diffuse germinal epithelial atrophy is often irreversible. Scattered seminiferous tubules with germinal cell atrophy can be seen as an aging change in rats.

Recommendation: Germinal epithelial atrophy should be diagnosed, graded and should be discussed in the pathology narrative if it is considered the primary change and if the incidence and/or severity appears to be related to chemical administration. Since germinal epithelial atrophy is considered the end stage of degeneration, the diagnosis of atrophy should be reserved for cases in which the majority of the affected tubules are devoid of germ cells, otherwise, degeneration is a more appropriate diagnosis (see "Testis, Germ cell - Degeneration"). If there is a mixture of effects (both atrophied and degenerative tubules), it can be described in the pathology narrative. If both terms are used in a single study, it is incumbent upon the pathologist to describe the relationship between the two lesions in the pathology narrative. If both testes are affected, the diagnosis should be indicated as bilateral and the severity grade based on the more severely affected testis.

References:

Creasy D, Bube A, de Rijk E, Kandori H, Kuwahara M, Masson R, Nolte T, Reams R, Regan K, Rehm S, Rogerson P, Whitney K. 2012. Proliferative and nonproliferative lesions of the rat and mouse male reproductive system. Toxicol Pathol 40:40S-121S.
Abstract: http://www.ncbi.nlm.nih.gov/pubmed/22949412

Dixon D, Heider K, Elwell MR. 1995.Incidence of nonneoplastic lesions in historical control male and female Fischer-344 rats from 90-day toxicity studies. Toxicol Pathol 23:338-348.
Abstract: http://www.ncbi.nlm.nih.gov/pubmed/7659956

Nolte T, Harleman JH, Jahn W. 1995. Histopathology of chemically induced testicular atrophy in rats. Exp Toxicol Pathol 47:267-286.
Abstract: http://www.ncbi.nlm.nih.gov/pubmed/8855122

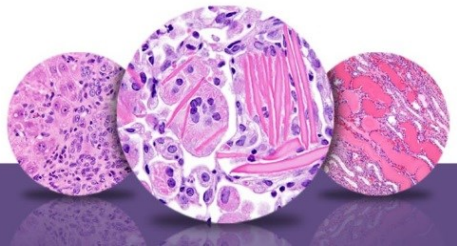

Testis, Germinal epithelium – Atrophy

References:

Radovsky A, Mitsumori K, Chapin RE. 1999. Male reproductive tract. In: Pathology of the Mouse: Reference and Atlas (Maronpot RR, Boorman GA, Gaul BW, eds). Cache River Press, Vienna, IL, 381-407.
Abstract: http://www.cacheriverpress.com/books/pathmouse.htm

Takano H, Kazuhiro ABE. 1987. Age-related histologic changes in the adult mouse: Testis. Arch Histol Jpn 50:533-544.
Abstract: http://www.ncbi.nlm.nih.gov/pubmed/3439850

Authors:

Dianne M. Creasy, PhD, Dip RCPath, FRCPath
Dianne Creasy Consulting LLC
Pipersville, PA

Robert R. Maronpot, DVM, MS, MPH, DACVP, DABT, FIATP
Senior Pathologist
Experimental Pathology Laboratories, Inc.
Research Triangle Park, NC

Dipak K. Giri, DVM, PhD, DACVP
Toxicologic Pathologist
Integrated Laboratory Systems, Inc.
Research Triangle Park, NC