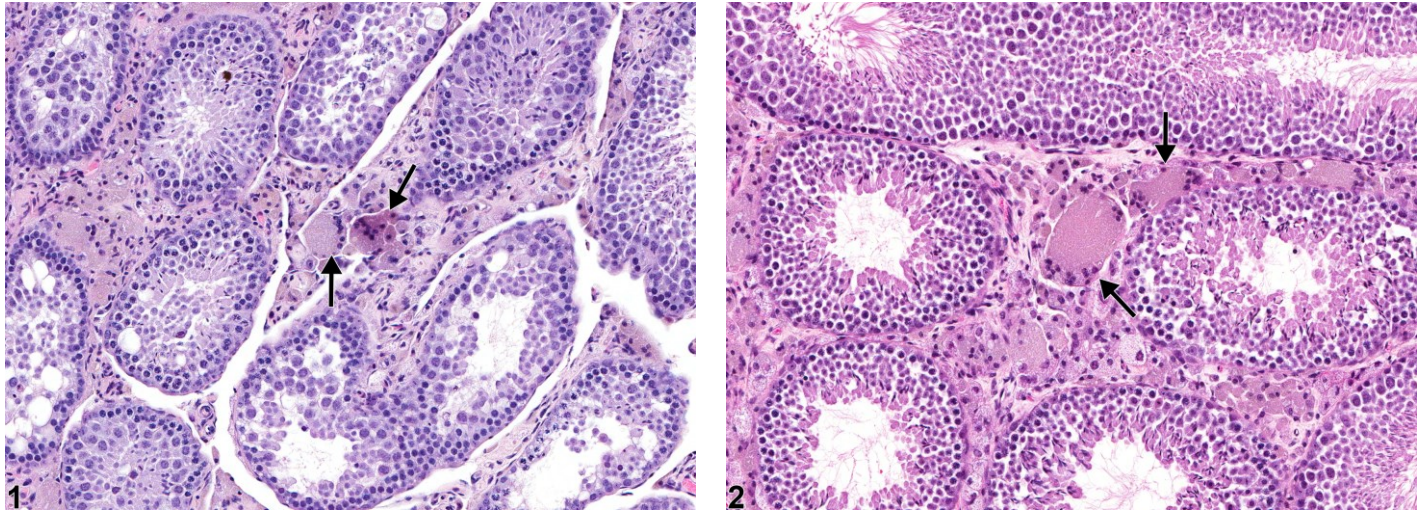




## NTP Nonneoplastic Lesion Atlas

### Testis, Interstitial cell – Syncytial cell



**Figure 1** Testis, Interstitial cell - Vacuolation in a male FVB/N transgenic mouse from a chronic study. There are interstitial syncytial cells (arrows). **Figure 2** Testis, Interstitial cell - Vacuolation in a male FVB/N transgenic mouse from a chronic study. There are interstitial syncytial cells (arrows) accompanied by vacuolation of Leydig cells.

**Comment:** The syncytial cell formation is unusual and has not been described in the literature. The interstitial syncytial cells may represent Leydig cells or macrophages. These can be distinguished using a Periodic acid-Schiff stain, which stains macrophages but not Leydig cells. The pathogenesis and significance of this lesion are unknown.

**Recommendation:** Interstitial syncytial cells should be diagnosed and graded when present and should be discussed in the pathology narrative if the incidence and/or severity appears to be related to chemical administration. Diagnosis should indicate bilaterality when present.

#### Reference:

Creasy D, Bube A, de Rijk E, Kandori H, Kuwahara M, Masson R, Nolte T, Reams R, Regan K, Rehm S, Rogerson P, Whitney K. 2012. Proliferative and nonproliferative lesions of the rat and mouse male reproductive system. *Toxicol Pathol* 40:40S-121S.

Abstract: <http://www.ncbi.nlm.nih.gov/pubmed/22949412>



National Toxicology Program  
U.S. Department of Health and Human Services



# NTP Nonneoplastic Lesion Atlas

## *Testis, Interstitial cell – Syncytial cell*

### **Authors:**

Dianne M. Creasy, PhD, Dip RCPATH, FRCPath  
Dianne Creasy Consulting LLC  
Pipersville, PA

Robert R. Maronpot, DVM, MS, MPH, DACVP, DABT, FIATP  
Senior Pathologist  
Experimental Pathology Laboratories, Inc.  
Research Triangle Park, NC

Dipak K. Giri, DVM, PhD, DACVP  
Toxicologic Pathologist  
Integrated Laboratory Systems, Inc.  
Research Triangle Park, NC