

NTP Nonneoplastic Lesion Atlas

Lung, Glands – Cyst

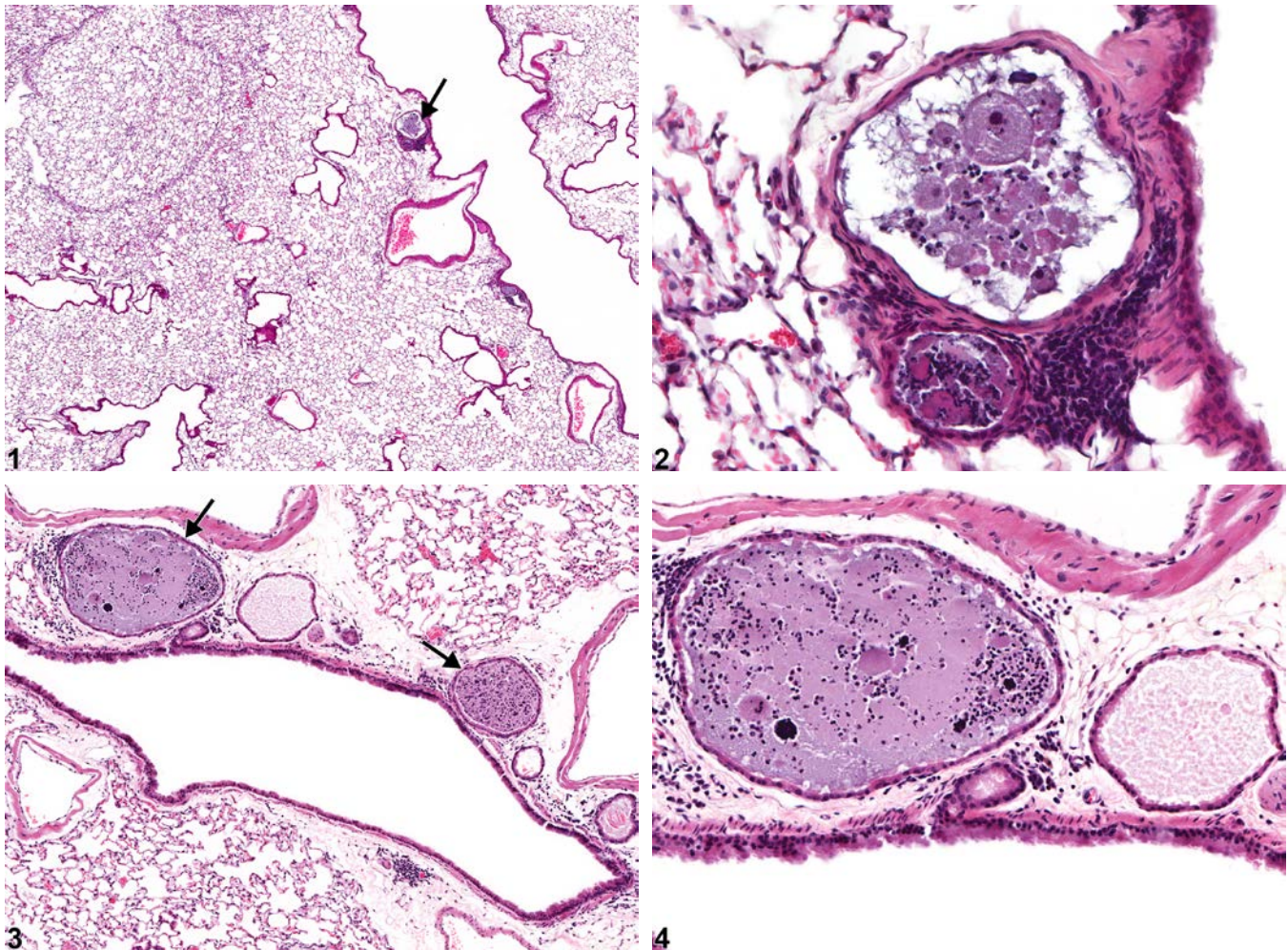
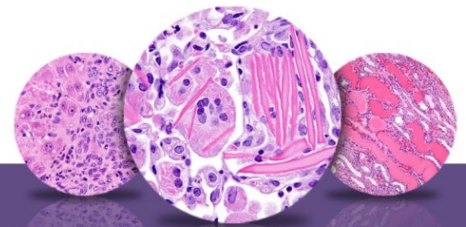


Figure Legend: **Figure 1** Lung, Glands - Cyst in a male B6C3F1/N mouse from a chronic study. There is a small cyst adjacent to a bronchus (arrow). **Figure 2** Lung, Glands - Cyst in a male B6C3F1/N mouse from a chronic study (higher magnification of Figure 1). The cyst contains cellular debris and a few inflammatory cells and is lined by flattened epithelial cells. **Figure 3** Lung, Glands - Cyst, Multiple in a male B6C3F1/N mouse from a chronic study. Multiple cysts are present in the submucosa of a bronchiole (arrows). **Figure 4** Lung, Glands - Cyst, Multiple in a male B6C3F1/N mouse from a chronic study (higher magnification of Figure 3). The cysts are lined by low cuboidal epithelial cells and contain cell debris and inflammatory cells.



NTP Nonneoplastic Lesion Atlas

Lung, Glands – Cyst

Comment: Cystically dilated submucosal glands lining the bronchi (Figure 1, Figure 2, Figure 3, and Figure 4) are occasionally seen in rodent toxicity studies. Single (Figure 1 and Figure 2) or multiple (Figure 3 and Figure 4) glands may be affected. The affected glands typically contain cellular debris, glandular secretions, and inflammatory cells. The lining epithelial cells are typically attenuated and may be low cuboidal or flattened. Submucosal gland cysts may be caused by obstruction of the secretory ducts, possibly due to squamous metaplasia of the overlying mucosal epithelium that results in trapped secretions and glandular dilatation. Typically, the glandular cyst is an incidental finding with no other airway lesions and is related to aging. Chemical agents inducing cysts in the bronchial and bronchiolar glands have not been reported.

Recommendation: Lung, Glands - Cyst should be diagnosed when treatment related but not graded.

Authors:

Mark F. Cesta, DVM, PhD, DACVP
Staff Scientist/NTP Pathologist
NTP Pathology Group
National Toxicology Program
National Institute of Environmental Health Sciences
Research Triangle Park, NC

Darlene Dixon, DVM, PhD, DACVP
Group Leader
Molecular Pathogenesis Group
National Toxicology Program
National Institute of Environmental Health Sciences
Research Triangle Park, NC

Ronald A. Herbert, DVM, PhD
Group Leader/NTP Pathologist
Pathology Support Group
National Toxicology Program
National Institute of Environmental Health Sciences
Research Triangle Park, NC

Lauren M. Staska, DVM, PhD, DACVP
Senior Pathologist
WIL Research
Hillsborough, NC