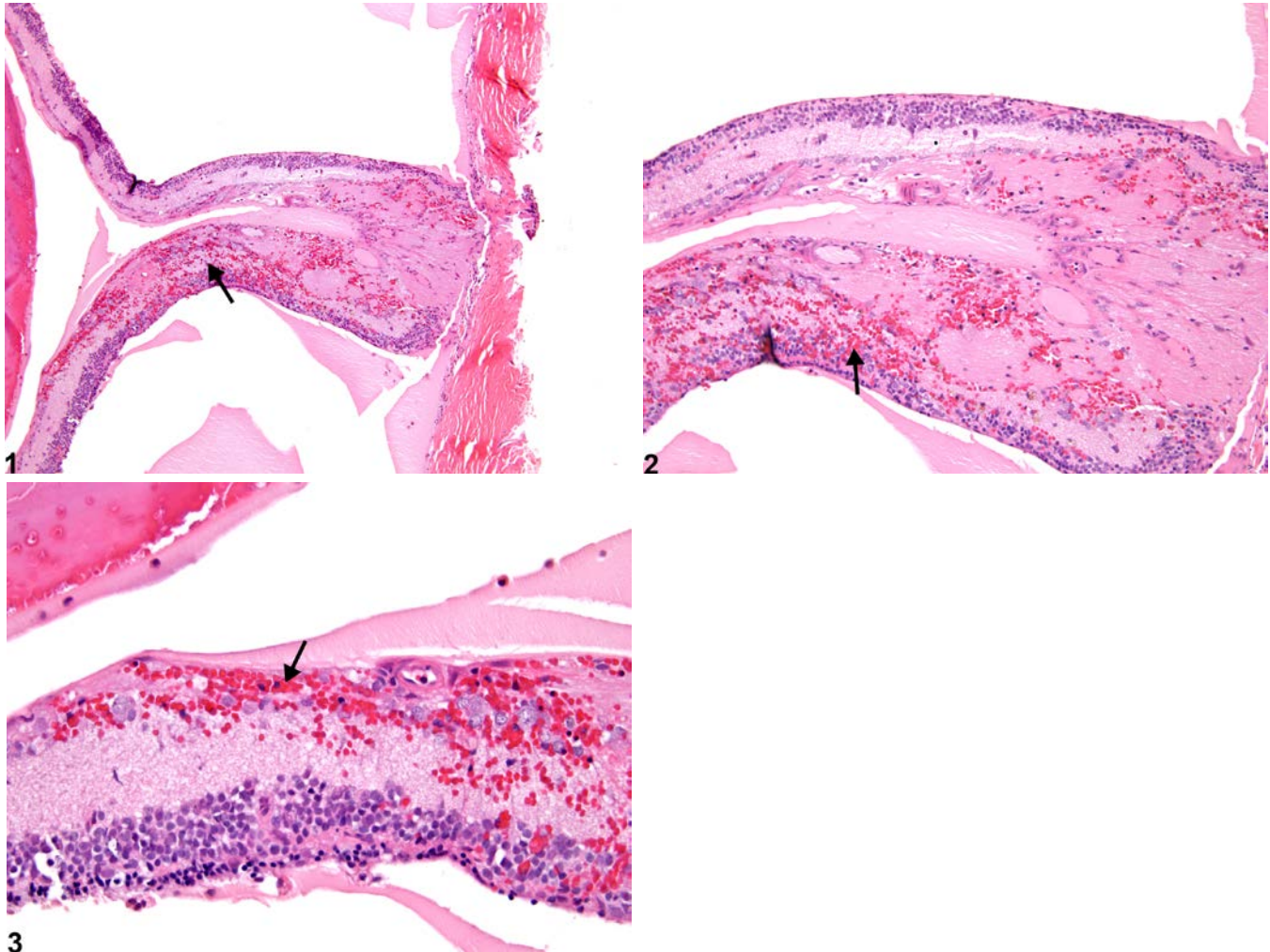




NTP Nonneoplastic Lesion Atlas

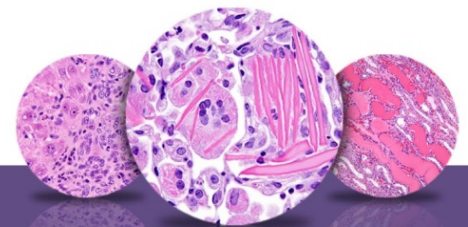
Eye, Retina – Hemorrhage



3

Figure Legend: **Figure 1** Eye, Retina - Hemorrhage in a female F344/N rat from a chronic study. There are extravasated blood cells (arrow) in a detached and degenerate retina. **Figure 2** Eye, Retina - Hemorrhage in a female F344/N rat from a chronic study (higher magnification of Figure 1). This detached and degenerate retina contains extravasated blood cells (arrow). **Figure 3** Eye, Retina - Hemorrhage in a female F344/N rat from a chronic study (higher magnification of Figure 1). The hemorrhage (arrow) in this detached and degenerate retina is mainly in the inner layers.

Comment: Hemorrhage (Figure 1, Figure 2, and Figure 3) is defined as extravasated blood cells (i.e., outside the blood vessels). In the retina, it is usually secondary to trauma, detachment, or inflammation, but can also result from pathology of the retinal vasculature due to metabolic disease or toxins.



NTP Nonneoplastic Lesion Atlas

Eye, Retina – Hemorrhage

Recommendation: Retinal hemorrhage should be diagnosed and assigned a severity grade when it is a primary finding. Retinal hemorrhage secondary to other lesions, such as detachment or inflammation, should not be diagnosed separately (unless warranted by severity) but should be described in the pathology narrative.

References:

Takehashi A, Saito Y, Mori K, Sugi N, Ono R, Yamagami H, Shinohara M, Tamemoto H, Ishikawa S, Kawakami M, Kanazawa Y. 2006. Characteristics of diabetic retinopathy in SDT rats. *Diabetes Metab Res Rev* 22:455-461.

Full-Text: <http://onlinelibrary.wiley.com/doi/10.1002/dmrr.638/full>

Kuno H, Usui T, Eydeloth RS, Wolf ED. 1991. Spontaneous ophthalmic lesions in young Sprague-Dawley rats. *J Vet Med Sci* 53:607-614.

Abstract: <http://www.ncbi.nlm.nih.gov/pubmed/10845604>

National Toxicology Program. 1997. NTP TR-450. Toxicology and Carcinogenesis Studies of Tetrafluoroethylene (CAS No. 116-14-3) in F344 Rats and B6C3F₁ Mice (Inhalation Studies). NTP, Research Triangle Park, NC.

Abstract: <http://ntp.niehs.nih.gov/go/6044>

Nyska A, Maronpot RR, Ghanayem BI. 1999. Ocular thrombosis and retinal degeneration induced in female F344 rats by 2-butoxyethanol. *Hum Exp Toxicol* 18:577-582.

Abstract: <http://het.sagepub.com/content/18/9/577.abstract>

Ramos M, Reilly CM, Bolon B. 2011. Toxicological pathology of the retina and optic nerve. In: *Fundamental Neuropathology for Pathologists and Toxicologists* (Bolon B, Butt MT, eds). Wiley, Hoboken, NJ, 385-412.

Abstract: <http://onlinelibrary.wiley.com/doi/10.1002/9780470939956.ch24/summary>

Silva-Araújo AL, Tavares MA, Patacao MH, Carolino RM. 1996. Retinal hemorrhages associated with in utero exposure to cocaine: Experimental and clinical findings. *Retina* 16:411-418.

Abstract: <http://www.ncbi.nlm.nih.gov/pubmed/8912968>

Author:

Margarita M. Gruebbel, DVM, PhD, DACVP
Senior Pathologist
Experimental Pathology Laboratories, Inc.
Research Triangle Park, NC