

NTP Nonneoplastic Lesion Atlas

Kidney, Renal Tubule – Cast

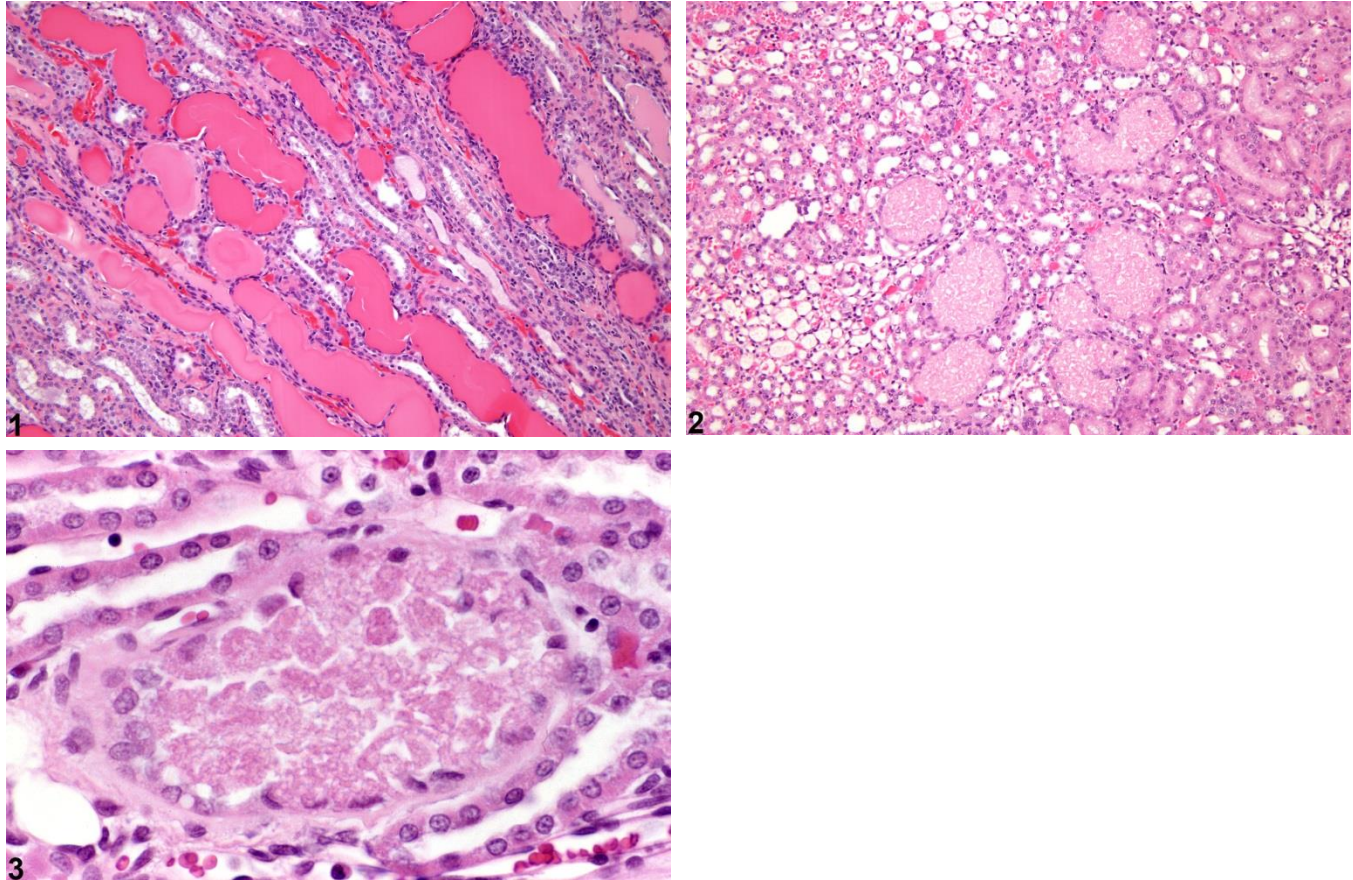
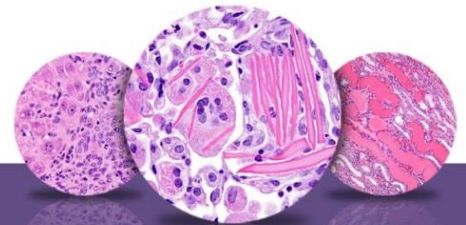


Figure Legend: **Figure 1** Kidney, Renal tubule - Cast in a male F344/N rat from a chronic study. Linear, hyaline (protein) casts are present in the medullary tubules. **Figure 2** Kidney, Renal tubule - Cast in a male F344/N rat from a subchronic study. Granular casts are present in the outer medulla. **Figure 3** Kidney, Renal tubule - Cast in a male F344/N rat from a subchronic study. Higher magnification of a granular cast containing necrotic cellular debris.

Comment: Intratubular casts may have various compositions with different morphologic and staining characteristics. Both hyaline and granular casts may be observed in a number of renal diseases. Commonly observed casts are hyaline (eosinophilic, homogeneous proteinaceous) casts associated with increased glomerular permeability such as with chronic progressive nephropathy (Figure 1) and granular (necrotic cellular debris) casts indicative of previous tubule cell necrosis associated with chemicals that induce α 2u-globulin nephropathy (Figure 2 and Figure 3).



NTP Nonneoplastic Lesion Atlas

Kidney, Renal Tubule – Cast

Recommendation: Tubule casts should be diagnosed according to their morphologic appearance (granular, hyaline, etc.) and given a severity grade. Hyaline casts observed as a component of chronic progressive nephropathy should not be diagnosed separately. Details of the casts, such as location within the kidney (e.g., the junction of the inner and outer stripes of the outer medulla, the typical location of casts associated with α 2u-globulin nephropathy) should be discussed in the pathology narrative.

References:

Alden CL. 1986. A review of unique male rat hydrocarbon nephropathy. *Toxicol Pathol* 14:109-111.
Abstract: <http://www.ncbi.nlm.nih.gov/pubmed/2424069>

Hard GC, Alden CL, Bruner RH, Frith CH, Lewis RM, Owen RA, Krieg K, Durchfeld-Meyer B. 1999. Non-proliferative lesions of the kidney and lower urinary tract in rats. In: *Guides for Toxicologic Pathology*. STP/ARP/AFIP, Washington, DC, 1-32.

Peter CP, Burek JD, Van Zwieten MJ. 1986. Spontaneous nephropathies in rats. *Toxicol Pathol* 14:91-100.
Abstract: <http://www.ncbi.nlm.nih.gov/pubmed/3715332>

Authors:

John Curtis Seely, DVM, DACVP
Senior Pathologist
Experimental Pathology Laboratories, Inc.
Research Triangle Park, NC

Amy Brix, DVM, PhD, DACVP
Senior Pathologist
Experimental Pathology Laboratories, Inc.
Research Triangle Park, NC