

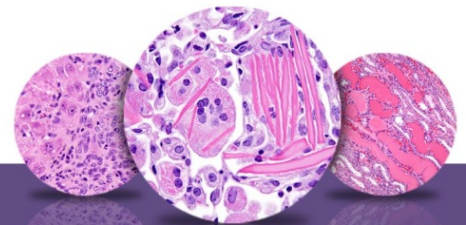
# NTP Nonneoplastic Lesion Atlas

## *Ovary – Introduction*

Information on the following lesions is available in this section:

- Ovary - Amyloid
- Ovary - Angiectasis
- Ovary - Atrophy
- Ovary, Bursa - Cyst
- Ovary, Corpus Luteum - Cyst
- Ovary - Cyst
- Ovary - Cyst, Epithelial
- Ovary, Epithelium - Hyperplasia
- Ovary - Fatty Change
- Ovary, Follicle - Cyst
- Ovary, Follicle - Polyovular
- Ovary - Hyperplasia, Sertoliform
- Ovary - Infiltration Cellular
- Ovary - Inflammation
- Ovary, Interstitial Cell - Hyperplasia
- Ovary - Mesonephric Duct Remnant
- Ovary - Metaplasia, Osseous
- Ovary - Mineral
- Ovary - Necrosis
- Ovary, Paraovarian Tissue - Cyst
- Ovary - Pigment
- Ovary - Thrombosis

Click the tabs in the left-hand column.



# NTP Nonneoplastic Lesion Atlas

## *Ovary – Introduction*

### **Authors:**

Gabrielle Willson, BVMS, DipRCPath, FRCPath, MRCVS  
Senior Pathologist  
Experimental Pathology Laboratories, Inc.  
Research Triangle Park, NC

Karen Y. Cimon, DVM, MS  
Senior Pathologist  
Experimental Pathology Laboratories, Inc.  
Research Triangle Park, NC