



NTP Nonneoplastic Lesion Atlas

Spleen – Pigment

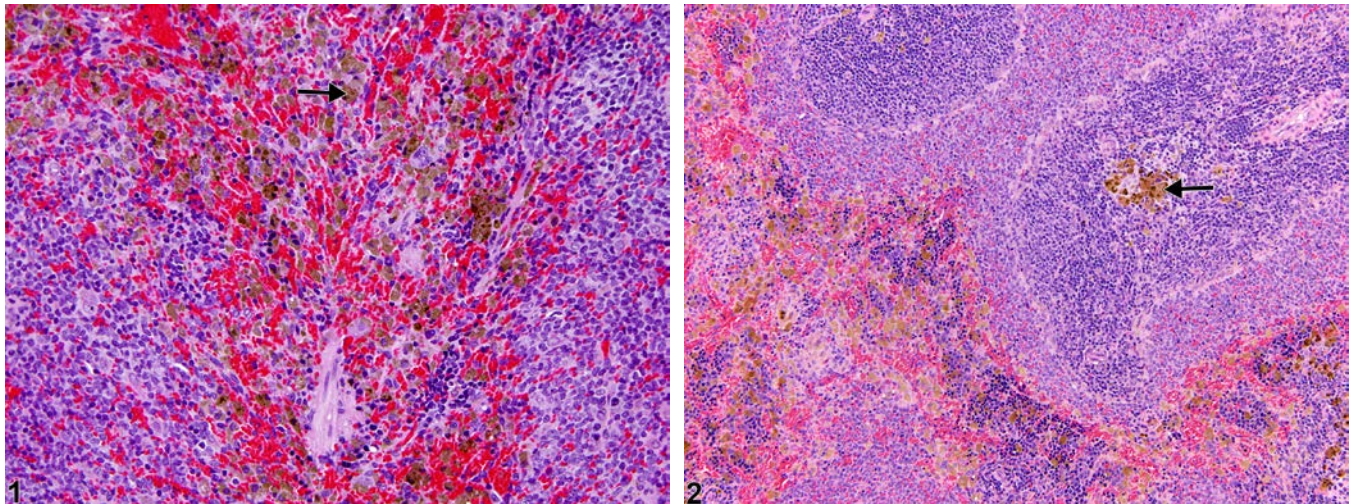
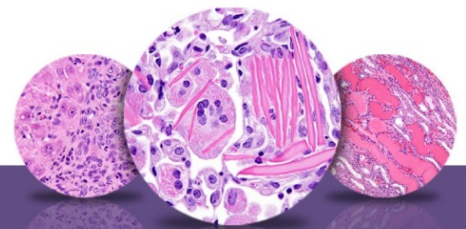


Figure Legend: **Figure 1** Spleen - Pigment in a male F344/N rat from a chronic study. Multifocal macrophages with intracytoplasmic dark-brown granular pigment (arrow) are present within the splenic red pulp. **Figure 2** Spleen - Pigment in a female Sprague-Dawley rat from a chronic study. Macrophages with intracytoplasmic golden-brown pigment (arrow) are focally present within the splenic white pulp.

Comment: The presence of a small amount of intracytoplasmic pigment within the splenic red pulp macrophages is a common background finding in rodents. Pigment can be hemosiderin, ceroid/lipofuscin, melanin, or test article related. It is typically found in the red pulp (Figure 1, arrow) but may also be present in the marginal zone and/or periarteriolar lymphatic sheaths of the white pulp (Figure 2, arrow), the capsule, or trabeculae. Hemosiderin pigment is the result of macrophage engulfment of red blood cells (usually effete or damaged) or free hemoglobin and may be increased in aging rodents and/or such conditions as treatment-induced hemolytic anemia or methemoglobinemia, chronic congestion, increased hematopoietic cell proliferation, and erythrophagocytosis. Hemosiderin deposits may also be observed with focal hemorrhage secondary to malignant neoplasms. The incidence of hemosiderin pigment in aging rodents is usually higher in females than in males for both rats and mice. Ceroid/lipofuscin, derived from oxidation and polymerization of unsaturated lipids, may also be present within splenic macrophages but occurs less commonly than hemosiderin. Hemosiderin can be identified with Perl's Prussian blue special stain, whereas ceroid/lipofuscin is acid-fast positive.



NTP Nonneoplastic Lesion Atlas

Spleen – Pigment

Melanin pigment can be seen in trabecular melanocytes or focally in the red pulp of black mice. Fontana-Masson or Schmorl's ferric-ferricyanide reduction stain can be used to identify melanin granules. Pigment may be subclassified by type (i.e., hemosiderin, ceroid/ lipofuscin, melanin) only when confirmed by special stains.

Recommendation: Pigment in the red and/or white pulp of the spleen should be diagnosed when increased or decreased due to treatment and assigned a severity grade. A diagnostic modifier (i.e., “increased” or “decreased”) should be included in the diagnosis to indicate whether the pigment is increased or decreased relative to concurrent controls. Definitive pigment identification is often difficult in histological sections, even with a battery of special stains. Therefore, a diagnosis of “pigment” (as opposed to diagnosing the type of pigment, e.g., hemosiderin or lipofuscin) is most appropriate. Morphological features of the pigment should be described in the pathology narrative. If the presence of pigment is secondary to age or not toxicologically meaningful, the pigment should not be diagnosed. The pathologist should use his or her judgment in deciding whether secondary deposits of pigment are prominent enough to warrant a separate diagnosis.

References:

National Toxicology Program. 2010. NTP TR-558. Toxicology and Carcinogenesis Studies of 3,3',4,4'-Tetrachloroazobenzene (TCAB) [CAS No. 14047-09-7] in Harlan Sprague-Dawley Rats and B6C3F1 Mice (Gavage Studies). NTP, Research Triangle Park, NC.

Abstract: <http://ntp.niehs.nih.gov/go/33564>

National Toxicology Program. 2011. NTP TR-570. Toxicology and Carcinogenesis Studies of α,β -Thujone (CAS No. 76231-76-0) in F344/N Rats and B6C3F1 Mice (Gavage Studies). NTP, Research Triangle Park, NC.

Abstract: <http://ntp.niehs.nih.gov/go/36137>

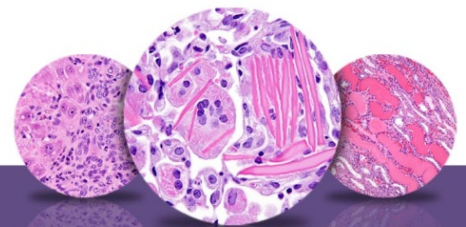
Stefanski SA, Elwell MR, Stromberg PC. 1990. Spleen, lymph nodes, and thymus. In: Pathology of the Fischer Rat: Reference and Atlas (Boorman GA, Eustis SL, Elwell MR, Montgomery CA, MacKenzie WF, eds). Academic Press, San Diego, 369-394.

Suttie AW. 2006. Histopathology of the spleen. *Toxicol Pathol* 34:466-503.

Full Text: <http://tpx.sagepub.com/content/34/5/466.full.pdf>

Ward JM, Rehg JE, Morse HC III. 2012. Differentiation of rodent immune and hematopoietic system reactive lesions from neoplasias. *Toxicol Pathol* 40:425-434.

Abstract: <http://www.ncbi.nlm.nih.gov/pubmed/22215512>



NTP Nonneoplastic Lesion Atlas

Spleen – Pigment

References:

Ward JM, Mann PC, Morishima H, Frith CH. 1999. Thymus, spleen, and lymph nodes. In: Pathology of the Mouse (Maronpot RR, ed). Cache River Press, Vienna, IL, 333-360.

Authors:

Kristen Hobbie, DVM, PhD
Principal Pathologist
Huntingdon Life Sciences
Peterborough, UK

Susan A. Elmore, MS, DVM, DACVP, DABT, FIATP
Staff Scientist, NTP Pathologist
NTP Pathology Group
National Toxicology Program
National Institute of Environmental Health Sciences
Research Triangle Park, NC

Holly M. Kolenda-Roberts, DVM, PhD, DACVP
Veterinary Pathologist
SNBL USA
Everett, WA