

NTP Nonneoplastic Lesion Atlas

Nose, Epithelium – Accumulation, Hyaline Droplet

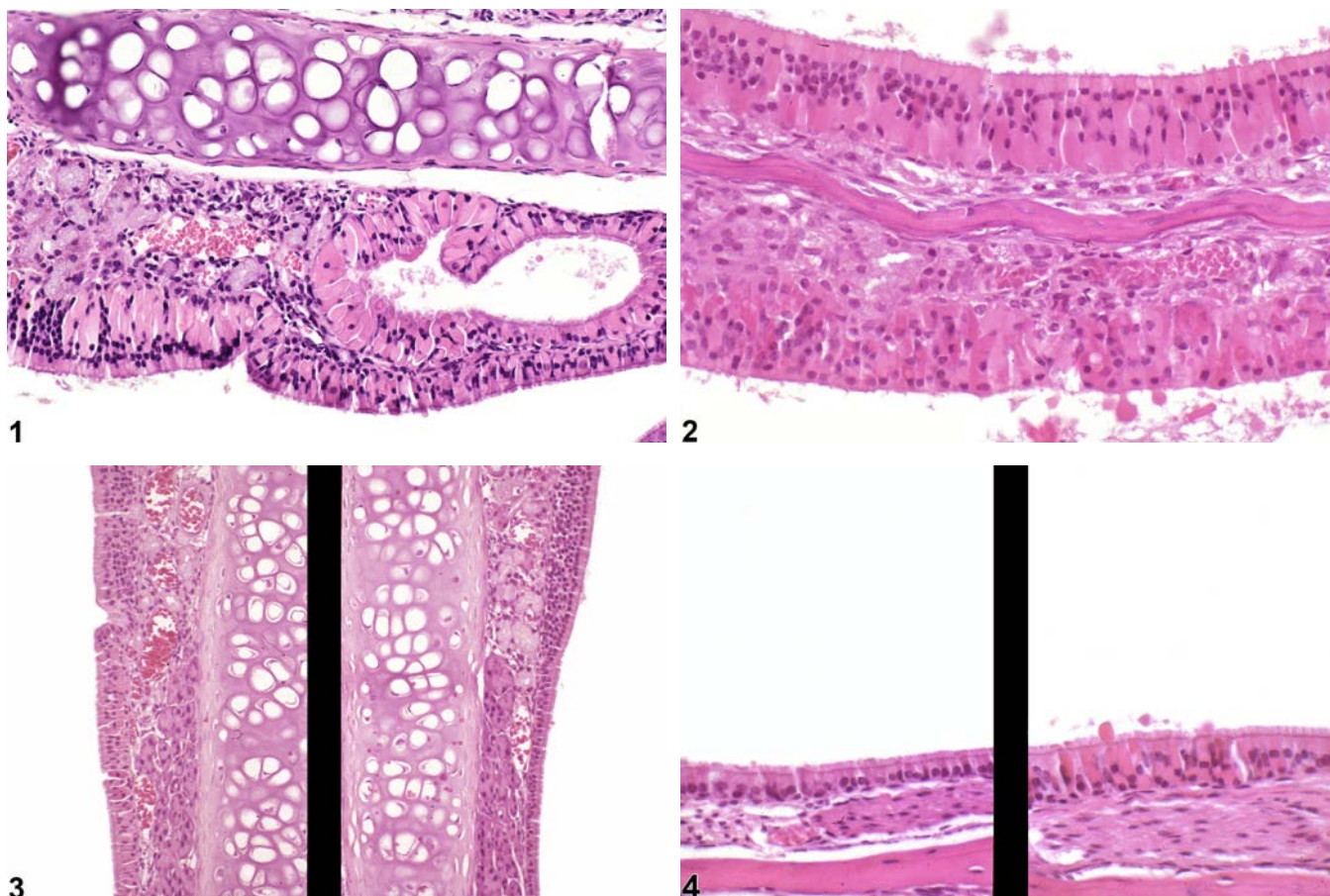


Figure Legend: **Figure 1** Nose, Respiratory epithelium - Accumulation, Hyaline droplet in a female B6C3F1/N mouse from a chronic study. The respiratory epithelium and cells of the mucosal gland contain eosinophilic globular material. **Figure 2** Nose, Olfactory epithelium - Accumulation, Hyaline droplet in a female B6C3F1/N mouse from a chronic study. The turbinate epithelial cells contain homogeneous hyaline material. Image provided courtesy of Dr. R. Miller. **Figure 3** Nose, Respiratory epithelium - Accumulation, Hyaline droplet in a female B6C3F1/N mouse from a subchronic study (left) and normal nasal respiratory epithelium from a control animal (right). Minimal accumulation of hyaline droplet material is present respiratory epithelium at the respiratory and olfactory epithelial junction of the septum in the treated animal (left), but not in the control mouse (right). Image provided courtesy of Dr. R. Miller. **Figure 4** Nose, Respiratory epithelium - Accumulation, Hyaline droplet in a treated female B6C3F1/N mouse (right) and a normal control female B6C3F1/N mouse from a subchronic study (left).



NTP Nonneoplastic Lesion Atlas

Nose, Epithelium – Accumulation, Hyaline Droplet

Hyaline droplet material is present in the respiratory epithelial cells lining the nasopharyngeal duct from the treated mouse (right) but not in the control mouse (left). Image provided courtesy of Dr. R. Miller.

Comment: The presence of hyaline droplets (Figure 1, Figure 2, Figure 3, and Figure 4), which is seen in both mice and rats, is characterized by the accumulation of eosinophilic, homogeneous, globular, hyaline material in the cytoplasm of cells of the respiratory epithelium, sustentacular cells of the olfactory epithelium, or epithelial cells of seromucous glands. The droplets may be subnuclear or supranuclear and can distort the cells. They are occasionally accompanied by intra- or extracellular eosinophilic crystals. The junction of the olfactory and respiratory epithelia is a very common site to see this change, particularly on the nasal septum of the level II section and in the dorsal meatus. The material has not been definitively identified, but it has been reported to react to antibodies for carboxylesterase and the Ym1 sequence of the Ym2 protein. The droplets are found in low numbers in control rats and mice and increase with age. The number and size of droplets can be exacerbated by treatment, but it is not considered a degenerative change.

Recommendation: Because the hyaline droplets can be found in control animals, diagnosis of this as a lesion (“Accumulation, Hyaline droplet”) should generally represent an increase in the size and/or number of droplets relative to controls. If there is no difference between the control and treated animals, this change need not be diagnosed. When diagnosed this lesion should be assigned a severity grade, and the epithelial type should be included in the diagnosis as the site modifier. Since this is not considered a degenerative change, any concurrent cellular degeneration should be diagnosed and graded separately.

References:

Boorman GA, Morgan KT, Uraih LC. 1990. Nose, larynx, and trachea. In: Pathology of the Fischer Rat: Reference and Atlas (Boorman GA, Eustis SL, Elwell MR, eds). Academic Press, San Diego, 315-337.

Herbert RA, Leninger JR. 1999. Nose, larynx, and trachea. In: Pathology of the Mouse: Reference and Atlas (Maronpot RR, ed). Cache River Press, Vienna, IL, 259-292.

Monticello TM, Morgan KT, Uraih LC. 1990. Nonneoplastic nasal lesions in rats and mice. Environ Health Perspect 85:249-274.

Full Text: <http://www.ncbi.nlm.nih.gov/pmc/articles/PMC1568333/>



NTP Nonneoplastic Lesion Atlas

Nose, Epithelium – Accumulation, Hyaline Droplet

References:

Renne R, Brix A, Harkema J, Kittel B, Lewis D, March T, Nagano K, Pino M, Rittinghausen S, Rosenbruch M, Tellier P, Wohrmann T. 2009. Proliferative and nonproliferative lesions of the rat and mouse respiratory tract. *Toxicol Pathol* 37(7 suppl):5S-73S.

Abstract: <http://www.ncbi.nlm.nih.gov/pubmed/20032296>

St Clair MGB, Morgan KT. 1992. Changes in the upper respiratory tract. In: *Pathology of the Aging Rat* (Mohr U, Dungworth DL, Capen CC, eds). International Life Sciences Institute Press, Washington, DC, 111-127.

Authors:

Rodney A. Miller, DVM, PhD, DACVP
NC Pathology Group Manager
Senior Pathologist
Experimental Pathology Laboratories, Inc.
Research Triangle Park, NC

Mark F. Cesta, DVM, PhD, DACVP
Staff Scientist, NTP Pathologist
Cellular and Molecular Pathology Branch
Division of the National Toxicology Program
National Institute of Environmental Health Sciences
Research Triangle Park, NC