

NTP Nonneoplastic Lesion Atlas

Urinary bladder – Dilation

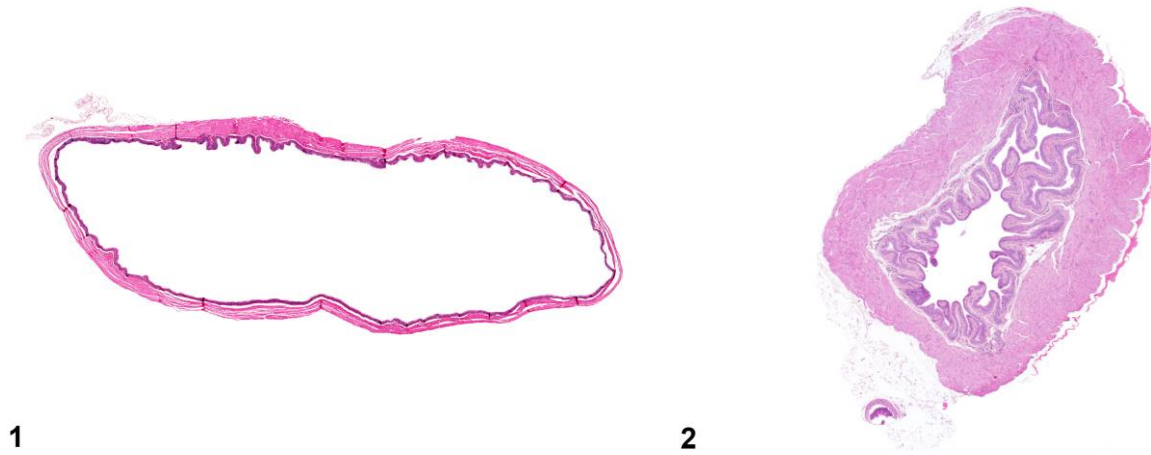
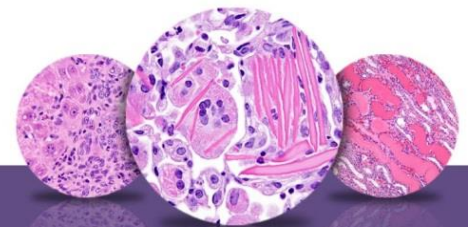


Figure Legend: **Figure 1** Dilation of the urinary bladder with focal to diffuse flattening of urothelium in a male B6C3F1 mouse from a chronic study. **Figure 2** Normal bladder for comparison in a male B6C3F1 mouse from a subchronic study.

Comment: Dilation of the urinary bladder is characterized by an overly distended bladder with flattened urothelium (Figure 1). This is a commonly observed change, which can result from a number of etiologies. The most common cause is obstruction. Cases of urinary bladder dilation may be noted where the cause is not apparent or related to chemical administration. The etiology of bladder dilation may be missed when the urethra is not examined. Mouse urologic syndrome in male animals is a frequent cause of obstruction, bladder dilation, inflammation, morbidity, and death. Calculi may also block the outflow of urine, leading to dilation. Although proteinaceous plugs may be observed in the trigone region of the urinary bladder, these plugs usually do not contribute to dilation because in most cases they represent agonal events. Formalin inflation of the urinary bladder is usually recommended, but overinflation and other inflation-related artifacts may occur.



NTP Nonneoplastic Lesion Atlas

Urinary bladder – Dilation

Recommendation: Dilation of the urinary bladder should be diagnosed and given a severity grade. Identification of cause should be considered if dilation is treatment related. If the cause can be identified, it should be diagnosed separately and its relationship to the urinary bladder dilation discussed in the narrative.

References:

Babcock VI, Southam CM. 1965. Obstructive uropathy in laboratory mice. *Proc Soc Exp Biol Med* 120:580–581.

Abstract: <http://ebm.sagepub.com/content/120/2/580.abstract>

Collins GR, Goodheart CR, Henson D. 1972. Spontaneous heritable hydronephrosis in inbred mice. 1. Description, incidence, and distribution of lesions. *Lab Anim Sci* 22:333–338.

Abstract: <http://www.ncbi.nlm.nih.gov/pubmed/4338696>

Everitt JI, Ross PW, Davis TW. 1988. Urologic syndrome associated with wire caging in AKR mice. *Lab Anim Sci* 38:609–611.

Abstract: <http://www.ncbi.nlm.nih.gov/pubmed/3193755>

Frazier KS, Seely JC, Hard GC, Betton G, Burnett R, Nakatsuji S, Nishikawa A, Durchfeld-Meyer B, Bube A. 2012. Proliferative and non-proliferative lesions in the rat and mouse urinary system. *Toxicol Pathol* 40:14S–86S.

Abstract: <http://www.ncbi.nlm.nih.gov/pubmed/22637735>

Hsu HH. 1986. Hereditary hydronephrosis, mouse. In: *Monographs on Pathology of Laboratory Animals: Urinary System* (Jones TC, Hard GC, Mohr U, eds). Springer, Berlin, 273–275.

Abstract: <http://www.ils.org/publications/urinarysystem.pdf>

Maronpot RR. 1998. Spontaneous hydronephrosis, rat. In: *Monographs on Pathology of Laboratory Animals: Urinary System, 2nd ed* (Jones TC, Hard GC, Mohr U, eds). Springer, Berlin, 306–309.

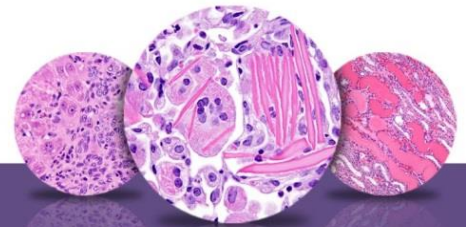
Abstract: <http://www.ils.org/publications/urinarysystem.pdf>

Sokoloff L, Barile MF. 1962. Obstructive genitourinary disease in male STR/1N mice. *Am J Pathol* 41:233–246.

Abstract: <http://www.ncbi.nlm.nih.gov/pmc/articles/PMC1949600/>

Weide LG, Lacy PE. 1991. Hereditary hydronephrosis in C57BL/KsJ mice. *Lab Anim Sci* 41:415–418.

Abstract: <http://www.ncbi.nlm.nih.gov/pubmed/1666139>



NTP Nonneoplastic Lesion Atlas

Urinary bladder – Dilation

Authors:

John Curtis Seely, DVM, DACVP
Senior Pathologist
Experimental Pathology Laboratories, Inc.
Research Triangle Park, NC

Abraham Nyska, DVM, Diplomate ECVF, Fellow IATP
Expert in Toxicologic Pathology
Visiting Full Professor of Pathology
Sackler School of Medicine, Tel Aviv University
Timrat Israel